



Research Article

Clinicopathological Study and Management of Parotid Gland

Swellings

Dr Avinash Kumar¹, Dr Garima Sinha*², Dr Komal Garg³, Dr Sonal Srivastava⁴, Dr Rushit Shah⁵, Hemkant Verma⁶

1. Associate Professor, Dept. of Otorhinolaryngology – Head and Neck Surgery, Noida International Institute of Medical Sciences (NIIMS), NIU ,Greater Noida, U.P.
2. Assistant Professor, Dept. of Anaesthesia and Critical Care, Government Institute of Medical Sciences (GIMS), Greater Noida , U.P.
3. Senior Resident , Dept. of Otorhinolaryngology – Head and Neck Surgery, Noida International Institute of Medical Sciences (NIIMS), NIU ,Greater Noida, U.P.
4. Junior Resident, 3rd year Post Graduate Trainee, Department of Otorhinolaryngology – Head and Neck Surgery ERA Lucknow Medical College & Hospital , Lucknow.
5. Senior Resident, Department of Pathology, Dr N.D. Desai Faculty of Medical Science and Research, Nadiad.
6. MCh Surgical Oncology.

***Correspondence to:** Dr Garima Sinha, Assistant Professor, Dept. of Anaesthesia and Critical Care, Government Institute of Medical Sciences (GIMS), Greater Noida , U.P.

Copyright.

© 2024 **Dr Garima Sinha**. This is an open access article distributed under the Creative Commons Attribution License, which permits unrestricted use, distribution, and reproduction in any medium, provided the original work is properly cited.

Received: 25 May 2024

Published: 18 June 2024

DOI: <https://doi.org/10.5281/zenodo.15128728>

Abstract

Aims and Objectives

1. To study the incidence of parotid gland lesions in patients attending ENT OPD/admitted in ENT ward in our region.
2. To evaluate the distribution in age, sex, modes of presentation of the parotid gland swellings.
3. To categorise the parotid gland swellings into different entities according to investigations.
4. To study histomorphology of parotid salivary gland lesions.

Type of study – A Prospective clinical study

Materials and Methods

Patients admitted in ENT WARD/attending ENT OPD , NIIMS , GREATER NOIDA with parotid swellings are selected for the present study from 1st Jan 2022 to 28th Feb 2024.

A prospective clinical study is conducted over the selected group for their age, sex, modes of presentation and their investigations. Study on various treatment modalities and their operative approach has been done.

Observation and Results.

The parotid gland lesions were more common in females and in most of the cases belonged to lower socioeconomic status. Pleomorphic adenoma was the most common type of salivary gland lesion seen in 64.70% patients. Commonest mode of presentation was neck swelling. The most common investigation done was Fine needle aspiration cytology. In maximum cases Superficial Parotidectomy was done. Morbidity with facial nerve paralysis was seen in 1 case.

Conclusion

This study is a single institutional experience of 34 parotid gland lesions. Most of the patients were in second decade of life. Fine needle aspiration cytology and histopathological examination plays a crucial role in diagnosis and treatment of parotid gland tumours. Management of parotid gland lesions were mainly operative.

Introduction

A swelling in the region of the salivary glands presents a diagnostic challenge with regards to its site of origin, histological behavior and tissue diagnosis.

These lesions are not only involved in diseases isolated to the parotid, but can also be present as a part of a generalized systemic disorder. Benign parotid neoplasms are estimated to be 7 times more frequently than malignant tumours. Majority of the benign tumours constitute pleomorphic adenoma. Most of them present with painless swelling in front of the auricle. Early diagnosis is important and long term survival rate is better if diagnosed early. Fine needle aspiration cytology is of paramount importance in diagnosing these lesions, however after surgical intervention specimen should be sent for histopathological examination to confirm the diagnosis.

Materials and Methods

Patients admitted in ENT WARD/attending ENT OPD, NIIMS, GREATER NOIDA with parotid swellings are selected for the present study from 1st Jan 2022 to 28th Feb 2024.

A prospective clinical study is conducted over the selected group for their age, sex, modes of presentation and their investigations. Study on various treatment modalities and their operative approach has been done. Written informed consent was obtained from all patients.

Inclusion criteria

1. All patients willing to participate in the same duration with parotid swellings.
2. Parotid lesions diagnosed based on FNAC findings.
3. Lesions that were not concomitant with other lesions such as infections.

Exclusion criteria

1. Any neurological or psychiatric illness; altered sensorium; patients with any other major medical disorders like DM, blood disorders, hypertension, acute and chronic liver and kidney disease
2. Pregnant and breast feeding females

All patients who presented to ENT OPD with parotid swellings in the given duration and who are willing to participate have been taken in sample size.

Results and Observations in my Study

The present study was done in the department of E. N. T - HNS for duration of 2 years from 1st JAN 2022 – 28th FEB 2024. During this period 34 cases of parotid swellings were admitted in the department/attended ENT OPD. The results and observations are made according to the following tables & charts.

TABLE 1 – AGE DISTRIBUTION

AGE DISTRIBUTION	NO. OF CASES	PERCENTAGE
1 -10 YRS	0	0
11 – 20 YRS	2	5.88%
21 -30 YRS	7	20.58%
31 – 40 YRS	13	38.23%
41 – 50 YRS	10	29.41%
51 – 60 YRS	1	2.94%
61 – 70 YRS	1	2.94%

The present study shows commonest age group as the fourth decade followed by fifth decade. The youngest patient was 17 years of age and the oldest was 68 years of age

TABLE 2 -SEX DISTRIBUTION

SEX	NO. OF CASES	PERCENTAGE
MALE	14	41.17%
FEMALE	20	58.82%

They were seen to be more common in females with 58.82%

TABLE 3 -TYPE OF CASES

TYPE OF SWELLINGS	NO. OF CASES	PERCENTAGE
PLEOMORPHIC ADENOMA	22	64.70%
CARCINOMA EX PLEOMORPHIC ADENOMA	2	5.88%
ACINIC CELL TUMOUR	1	2.94%
WARTHINS	2	5.88%
MYOEPIITHELIOMA	1	2.94%
ONCOCYTOMA	1	2.94%
ABSCESS	2	5.88%
SJOGRENS SYNDROME	2	5.88%
MUCOEPIDERMOID CARCINOMA	1	2.94%

Pleomorphic adenoma was most common in 64.70% cases.

TABLE 4 -MODE OF PRESENTATION**CLINICAL PRESENTATION**

MODE OF PRESENTATION	NO.OFCASES	PERCENTAGE
PRE AURICULAR UNILATERAL FIRM SWELLING	30	88.23%
CYSTIC SWELLING	2	5.88%
BILATERAL SWELLING	2	5.88%

The commonest presentation was preauricular unilateral firm swelling (88.23%).

TABLE 5 - INVESTIGATIONS

TYPE OF INVESTIGATION	NO.OF CASES	PERCENTAGE
FNAC	34	100%
USG NECK	32	94.11%
CT SCAN NECK	10	29.41%
HISTOPATHOLOGY	32	94.11%

In the present study among the investigations , FNAC and USG NECK were important and were done in most of the cases of parotid gland swellings .

TABLE 6 -MODE OF TREATMENT – out of 34 parotid gland swelling cases,

OPERATIVE APPROACH	NO. OF CASES	PERCENTAGE
SUPERFICIAL PAROTIDECTOMY	28	82.35%
TOTAL PAROTIDECTOMY	2	5.88%
INCISION AND DRAINAGE	2	5.88%
CONSERVATIVE	2	5.88%

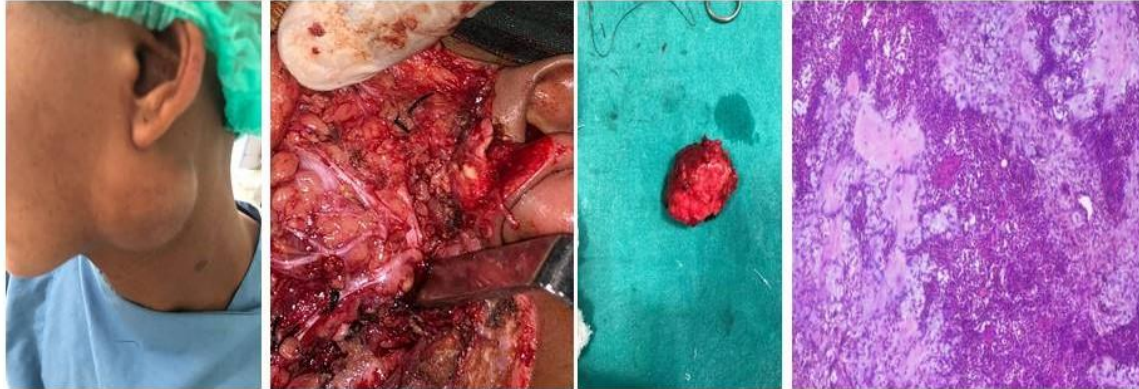TABLE 7 - COMPLICATIONS

TYPE OF COMPLICATION	NO. OF CASES	PERCENTAGE
FACIAL NERVE PARALYSIS	1	2.94%
NECK HEMATOMA	1	2.94%
INFECTION	1	2.94%

In the present study we have encountered a few complications also. They were treated conservatively.

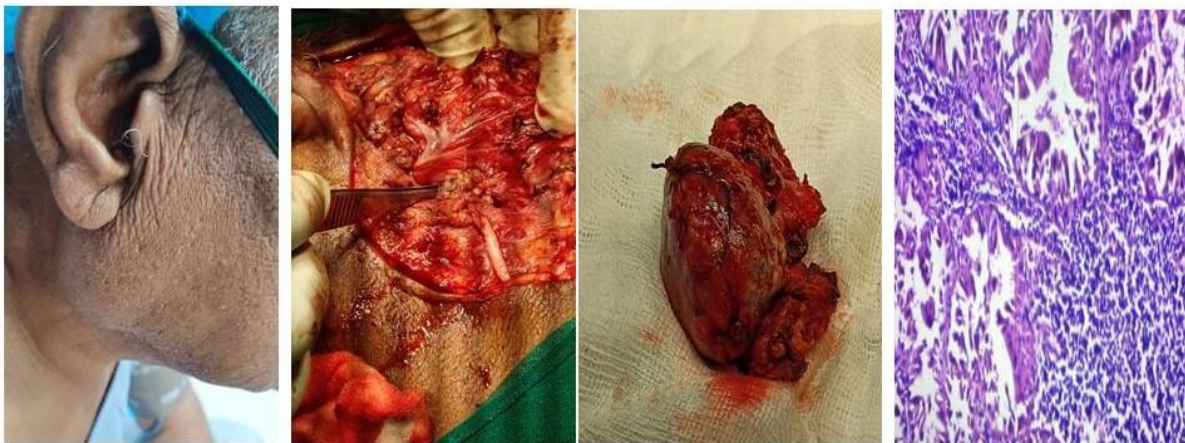
FOLLOW UP: Our cases were followed up after 2 weeks and 1 month of discharge from hospital.

CASE 1 – Case of pleomorphic adenoma parotid. Histology slide shows epithelial component forming the inner layer of cysts and tubules and myoepithelial cells as the outer layer of cysts and tubules and are scattered within the myxoid stroma.

PLEOMORPHIC
ADENOMA PAROTIDINTRAOPERATIVE
PICTUREGROSS
SPECIMEN

HISTOLOGY SLIDE

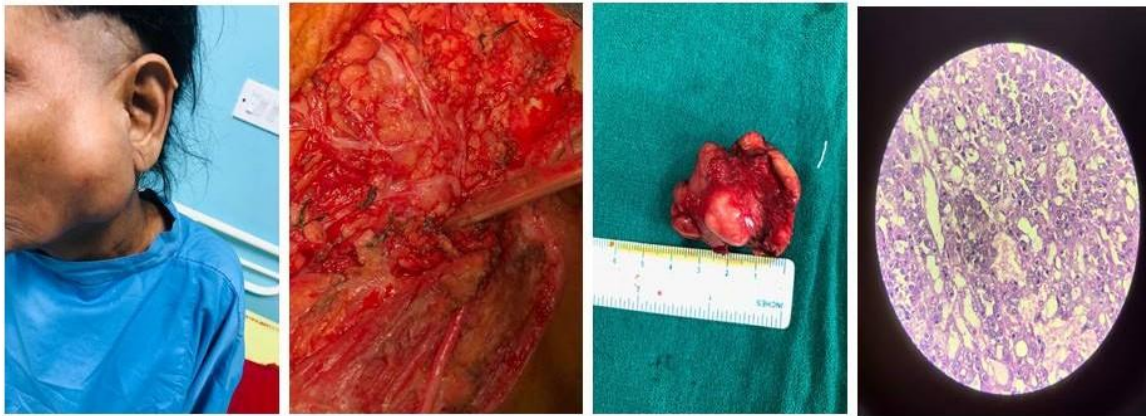CASE 2 – Case of Warthins tumour . Histopathology confirmed the disease showing papillary architecture. The papillae was lined by bilayered oncocytic epithelial cells and surrounding stroma shows dense lymphoid population containing lymphoid follicles with germinal centre.

WARTHINS
TUMOURINTRAOPERATIVE
PICTURE

GROSS SPECIMEN

HISTOLOGY SLIDE

CASE 3 – Case of acinic cell tumour. Histopathology showed large and polyhedral cells with basophilic granular cytoplasm. Prominent lymphoid infiltrates with necrosis and mitosis are present.

ACINIC CELL
TUMOUR PAROTIDINTRAOPERATIVE
PICTURE

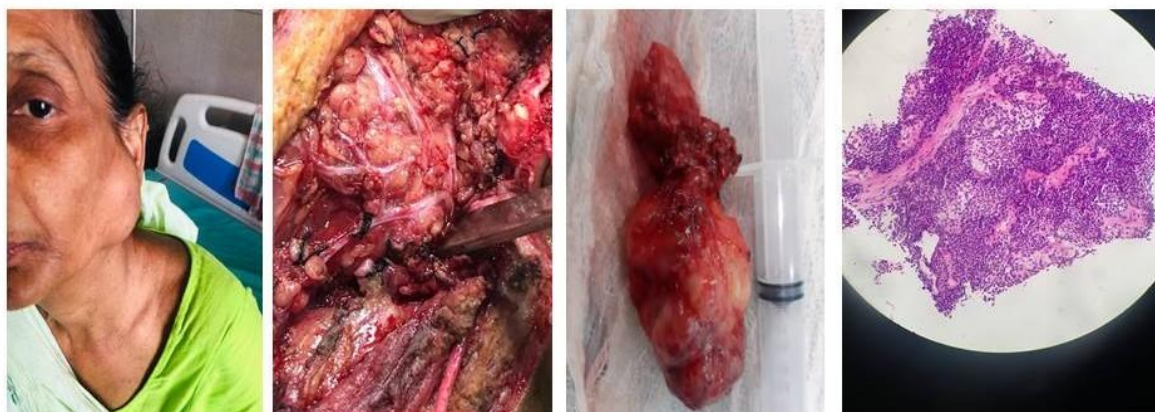GROSS SPECIMEN

HISTOLOGY SLIDE

CASE 4 – Case of myoepithelioma parotid. Histopathology showed H&E-stained sections showing solid tumor with round to oval cells with inconspicuous nucleoli and vesicular chromatin, surrounded by scanty, hyalinized stroma.

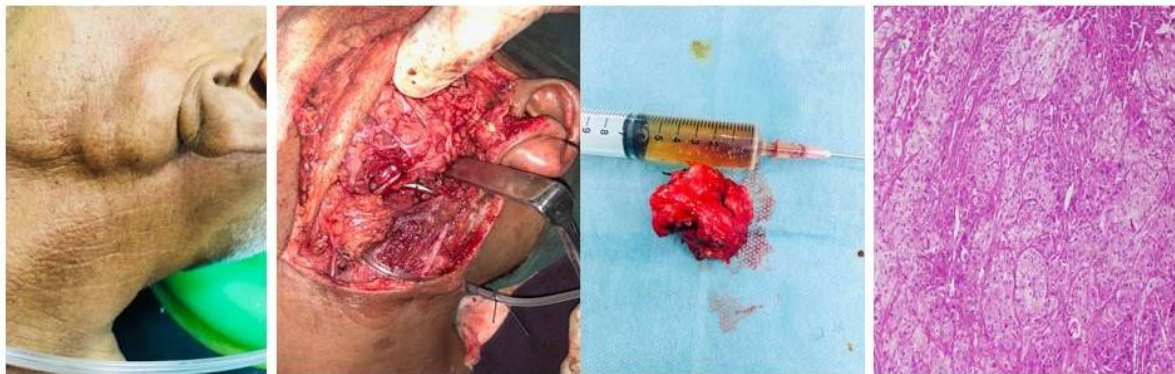Sections showing tumor cells with epithelioid morphology.

On immunohistochemistry, cells were positive for p63 & S100 and also showed focal positivity for SMA (smooth muscle actin). These tumor cells showed negative results with synaptophysin & chromogranin.

MYOEPITHELIOMA
PAROTIDINTRAOPERATIVE
PICTUREGROSS
SPECIMEN

HISTOLOGY SLIDE

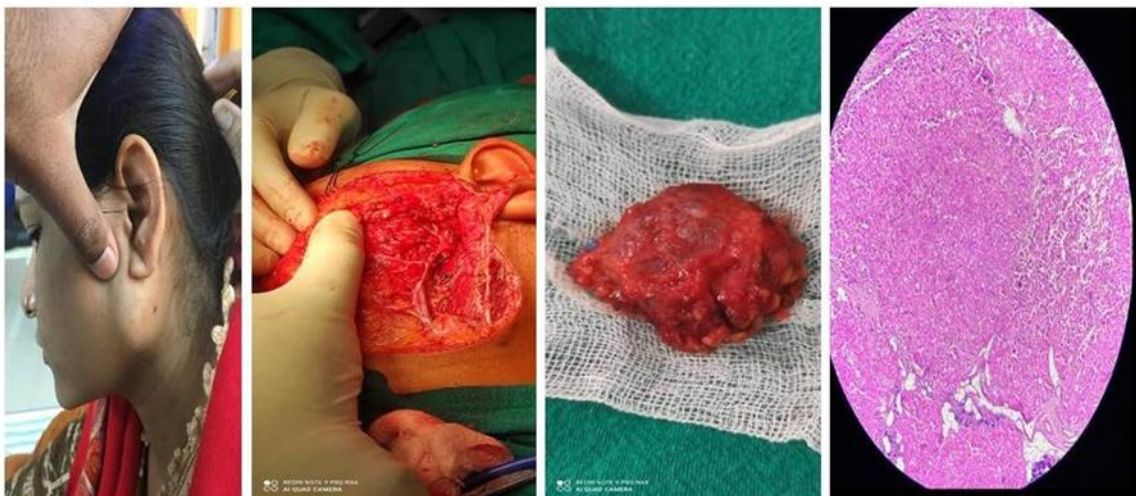CASE 5 – Case of Mucoepidermoid carcinoma parotid . Histopathology showed cells arranged in solid , cystic and papillary growth patterns and solid nests , sheets or cords of epidermoid cells. Extracellular mucin pools are seen and varying degree of pleomorphism are noted along with areas of necrosis.

MUCOEPIDERMOID
CARCINOMA PAROTIDINTRAOPERATIVE
PICTURE

GROSS SPECIMEN

HISTOLOGY SLIDE

CASE 6 – Case of Oncocytoma parotid. Histopathology showed eosinophilic cells with finely granular cytoplasm and uniform , round , centrally placed nuclei.

ONCOCYTOMA
PAROTIDINTRAOPERATIVE
PICTURE

GROSS SPECIMEN

HISTOLOGY SLIDE

Discussion

The present study of 34 cases of parotid swellings are discussed in light of the similar available literature. The study is compared with relevant literature to find out the differences or similarities of evaluated results, although we did not get exactly similar study in the review of literature. The discussion is done according to the sequence of results & observations.

The study was conducted with the aim of assessing age , sex , mode of presentation , histological types , surgery performed and complications of 34 cases of parotid lesions admitted in ENT ward of NIIMS , Greater Noida.

Salivary gland neoplasms are rare and constitute 3 – 4 % of Head and Neck neoplasms¹. Majority of them are benign and a small percentage of them constitute malignant tumours.

Parotid gland is the most common site of salivary gland tumours². They arise in superficial lobe mostly . Parotid tumours present as slow growing , painless swelling either below the ear or in the upper aspect of neck³. Rarely they arise from deep lobe and in this case they mostly present as parapharyngeal masses⁴.

Parotid tumours pose a special challenge to surgeons because of diversity of histological subtypes and their remarkable variation in clinical behavior .

Parotid gland lesions were observed in the age group 17 to 68 years in my study. Highest incidence was observed in 4th decade followed by 5th decade. In the study conducted by Akhtar J et al , his results were similar to mine⁵.

They were seen more commonly in females (58.82%). My results are consistent with studies conducted by Kilavuz⁶ and Naz et al⁷.

The commonest mode of presentation was painless neck swelling which was present in all cases. Similar observations were made by Das DK et al⁸ and Nagarkar⁹ study. Pain in the parotid gland was the second most common symptom and is more common in malignant tumours.

Pleomorphic adenoma was the commonest swelling of all swellings (70.58 %). Similar high incidence of Pleomorphic adenoma 83.9% was observed by Vuhahela et al study of African population¹⁰ . This is similar to the results of other studies too^{6,7}.

One case of oncocytoma was recorded, accounting for 2.94% of all parotid swellings. Tilakaratne WM et al , Subhashraj K et al , Ito et al studies found Oncocytoma accounting for less than 1% of all salivary gland tumours¹¹.

One case of Warthins tumour was reported , accounting for 2.94% of all salivary gland tumours consistent with less than 1% incidence of it in the study done by Gonzalvez at al ¹².

Two cases of Carcinoma ex Pleomorphic Adenoma was reported , accounting for 5.88 % of all parotid swellings. Study done by Jaafari et al reported 7% of these cases in his study¹³.

Two cases of Sjogrens syndrome were reported accounting for 5.88 % of all parotid lesions. Study by Achalkar et al also reported 2 cases of Sjogrens syndrome in his study¹⁴.

Out of 34 cases, 30 underwent FNAC and 2 cases were diagnosed clinically as acute inflammatory conditions associated with severe pain. 2 cases were diagnosed as Sjogrens syndrome.

All the 30 cases were subjected to FNAC as it was a quick , rapid , simple , inexpensive and harmless procedure¹⁵. The superficial location of parotid gland , easy accessibility and high diagnostic accuracy makes FNAC a popular method for evaluating them¹⁶.

The sensitivity of FNAC in detecting benign tumours was similar to study done by A F Costa et al¹⁷ . The diagnostic accuracy of FNAC in detecting Benign and Malignant tumours was similar to study done by S Yang et al¹⁸. In our studies FNAC was highly sensitive in detecting benign tumours.

Only 32 cases underwent HPE, rest of them were managed conservatively.

Limitation of this study is that we could not have a proper follow up of the patients due to short interval of study period (2yrs), whereas when compared to other studies, they have longer study period and also it is a single institutional study.

Conclusion

Diagnosis of Parotid tumours must be considered in any patient presenting with salivary gland swelling¹⁹. Parotid neoplasms have diverse clinical and prognostic outcomes , hence accurate diagnosis is essential²⁰. FNAC should be the first choice of investigation in evaluating salivary gland pathologies²¹. All specimens should be sent for histopathological examination to confirm the diagnosis.

CONFLICTS OF INTEREST

The authors report no conflict of interest.

References

1. Wang XD, Meng LJ, Hou TT, Huang SH. Tumours of the salivary glands in northeastern China: a retrospective study of 2508 patients. *Br J Oral Maxillofac Surg*. 2015;53(2):132-7.

2. Carlson ER, Schlieve T. Salivary Gland Malignancies. *Oral Maxillofac Surg Clin North Am*. 2019;31(1):125-144.
3. Al sharif MN, Alhomsy K. Salivary glands tumors: demographics and occurrence according to age and gender. *EJBPS*. 2020;7(6):508-14.
4. Kumaran JV, Daniel MJ, Krishnan M, Selvam S. Salivary gland tumors: An institutional experience. *SRM J Res Dent Sci*. 2019;10:12-6.
5. Akhter J, Hirachand S, Lakhey M. Role of FNAC in the diagnosis of salivary gland swellings. *Kathmandu Univ Med J*. 2008;6(2)(22):204–208.
6. Kilavuz AE, Songu M, Pinar E, Ozkul Y, Ozturkcan S, Aladag I. Superficial Parotidectomy Versus Partial Superficial Parotidectomy: A Comparison of Complication Rates, Operative Time, and Hospital Stay. *J Oral Maxillofac Surg*. 2018;76(9):2027-32.
7. Naz S, Hashmi AA, Khurshid A, Faridi N, Edhi MM, Kamal A, Khan M. Diagnostic role of fine needle aspiration cytology (FNAC) in the evaluation of salivary gland swelling: an institutional experience. *BMC Res Notes*. 2015;8:101. doi: 10.1186/s13104-015-1048-5.
8. Das DK, Anim JT. Pleomorphic adenoma of salivary gland: to what extent does fine needle aspiration cytology reflect histopathological features. *Cytopathology*. 2005;16:65–70. doi: 10.1111/j.1365-2303.2004.00208.x.
9. Nagarkar NM, Bansal S, Dass A, et al. Salivary gland tumors - our experience. *Indian J Otolaryngol Head Neck Surg*. 2004 Jan;56(1):31-4. doi: 10.1007/BF02968769.
10. Vuhahula E A.M. Salivary Gland tumors in Uganda: Clinical Pathological study. *African Health Sciences* 2004; 4 (1): 15-23.
11. Tilakaratne WM, Jayasooriya PR, Tennakoon TM, et al. Epithelial salivary tumors in Sri Lanka: a retrospective study of 713 cases. *Oral Surg Oral Med Oral Pathol Oral Radiol Endod*. 2009 Jul;108(1):90-8. doi: 10.1016/j.tripleo.2009.01.026. Epub 2009 Apr 29.
12. Gonzalez-Alva P, Tanaka A, Ohba K, Yoshizawa D, Ito S, Kusama K. Clinicopathological Study of Epithelial Salivary Gland Neoplasms : Retrospective Review of 156 Cases. *J. Meikai Dent Med* 2007; 36 (2): 135 -43.
13. Jaafari-Ashkavandi Z, Ashraf MJ, Moshaverinia M. et al. Salivary gland tumors: a clinicopathologic study of 366 cases in southern Iran. *Asian Pac J Cancer Prev*. 2013;14(1):27-30.
14. Achalkar G.V " A clinicopathological Study of Salivary Gland Tumors". *Journal of Evolution of Medical and Dental Sciences* 2013;50(12):9726-31

15. Shetty Archana, V Geethamani. Spectrum of Major Salivary Gland Tumours: Clinicopathologic Study. *Sch. J. App. Med. Sci.* 2014; 2(3):1088-90.
16. Henrys CE, Grigg R. Use of fine-needle aspiration cytology in the diagnosis of parotid neoplasms. *ANZ J Surg.* 2015;85:838–842. doi: 10.1111/ans.12939.
17. A. F. Costa, A. Altemani, and M. Hermsen, “Current concepts on dedifferentiation/high-grade transformation in salivary gland tumors,” *Pathology Research International*, vol. 2011, Article ID 325965, 9 pages, 2011.
18. S. Yang and X. Chen, “Epithelial-myoepithelial carcinoma with high grade transformation,” *International Journal of Oral and Maxillofacial Surgery*, vol. 41, no. 7, pp. 810–813, 2012.
19. Ansari M. Salivary gland tumors in an Iranian population: retrospective study of 130 cases. *J Oral Maxillofac Surg*, 2007;65:2187-94.
20. Nakisa Torabinia, Saeedeh Khalesi, Clinicopathological study of 229 cases of salivary gland tumors in Isfahan population *Dental Research Journal / September 2014 / Vol 11 / Issue 5*
21. de Oliveira FA, Duarte EC, Taveira CT, Máximo AA, de Aquino EC, Alencar RD, Vencio EF. Salivary gland tumor: a review of 599 cases in a Brazilian population. *Head and neck pathology.* 2009 Dec;3:271-5



Medtronic