



## **Congenital Brachymetatarsia and its Surgical Treatment**

Kassem El Houcheimi\*

**\*Correspondence to:** Kassem El Houcheimi, UAE.

### **Copyright**

© 2024 **Kassem El Houcheimi**. This is an open access article distributed under the Creative Commons Attribution License, which permits unrestricted use, distribution, and reproduction in any medium, provided the original work is properly cited.

Received: 29 March 2024

Published: 01 June 2024

**ABSTRACT**

*This retrospective study evaluated the surgical results of 69 metatarsals from 44 patients with congenital brachymetatarsia. The study used an intercalary autogenous iliac bone transplant for one-stage lengthening and a one-stage combination technique for multiple foot ray damage. If toe-tip parabola couldn't be achieved with intraoperative metatarsal distraction, concurrent proximal phalangeal lengthening was performed. The follow-up period averaged 3.5 years. All patients were satisfied with the aesthetic and functional outcomes. In 56 metatarsals, one-stage lengthening resulted in an average length gain of 14 mm. Six patients with a combination shortening operation restored a practically normal foot parabola. No case was made more difficult by later neurovascular dysfunction. The study concludes that satisfactory results can be achieved for congenital brachymetatarsia treatment if surgical alternatives are tailored to the patient's expectations and overall foot look.*

**Keywords:** *Brachymetatarsia, Foot, Treatment, Neurovascular, Dysfunction.*

**Introduction**

Congenital brachymetatarsia is a rare condition involving the shortening of metatarsal bone due to premature epiphyseal closure. The condition is primarily affected by the fourth metatarsal and has a strong female predominance. 1 The deformity can cause pain due to an altered metatarsal parabola, but cosmesis is a major concern among young women. Various surgical techniques have been described for repairing brachymetatarsia, including one-stage lengthening with an intercalary bone graft and gradual lengthening by callotasis. Each method has its advantages and disadvantages.

One-stage lengthening offers advantages such as a shorter period to bony union, reduced scarring, and less morbidity. However, it also has disadvantages such as donor-site morbidity, a smaller gain in length, and more neurovascular complications. Gradual lengthening by callostasis does not require a bone graft, allows early weight bearing, and has fewer neurovascular complications.<sup>2</sup>

Sometimes, a shortening osteotomy of the adjacent metatarsal can restore a normal metatarsal parabola and

cosmetically acceptable foot appearance. When assessing a patient with brachymetatarsia, several variables should be considered, including the number and sites of affected rays, the amount of lengthening, and the method of lengthening and fixation. This study aimed to evaluate the surgical outcome of congenital brachymetatarsia treated according to the protocol.<sup>3</sup>

## Patients and Methods

The study reviewed 69 cases of congenital brachymetatarsia in 44 patients aged 16 to 36 years. All patients complained of unsightly short toes and experienced occasional pain in adjacent metatarsal heads when walking. The main indication for surgery was cosmetic, but patient selection was made when the patient fully understood the expected results and possible complications. Surgery was not considered if the patient had not reached skeletal maturity due to possible physal injury related with lengthening or if the patient had an unrealistic expectation of the results.<sup>4</sup>

The patients were categorized into single- or multiple-ray involvements and grouped by the amount of lengthening required. A one-stage lengthening with an intercalary autogenous iliac bone graft was performed for single ray involvement in a foot, and additional proximal phalangeal lengthening was planned if the measured target length was large. A one-stage combined shortening and lengthening procedure without an iliac bone graft was performed for multiple ray involvement in the same foot. If the patient refused to accept shortening of normal rays, they could choose either one-stage lengthening or gradual lengthening by callostasis in all affected rays.<sup>5</sup>

## Treatment of single-ray brachymetatarsia

A study conducted on 38 patients with single-ray brachymetatarsia performed a total of 68 one-stage skeletal lengthening procedures using intercalary autogenous bone grafting.<sup>6</sup> The procedure involved lengthening 12 proximal phalanges concomitantly with the metatarsal of the same ray. The majority of the affected metatarsal was the fourth toe, with only one patient with unilateral involvement and two with bilateral involvement having isolated shortening of the first metatarsal. <sup>7</sup> The osteotomy site was gradually distracted using an Inge bone spreader for 20-30 minutes to reduce soft-tissue tension. If necessary, adjacent deep

transverse metatarsal ligaments were cut. The cast and K-wire were removed 8-10 weeks after surgery, and full weight bearing was permitted 12 weeks postoperatively. The procedure for proximal phalanx lengthening was similar.<sup>8</sup>

### **Treatment of multiple-ray brachymetatarsia**

Six patients with congenital brachymetatarsia underwent a one-stage combined shortening and lengthening procedure using an intercalary autogenous bone graft from an adjacent metatarsal.<sup>9</sup> The procedure involved multiple metatarsals bilaterally, with five patients having short first and fourth metatarsals and one having short first, fourth, and fifth metatarsals. Patients were informed about the procedure on normal rays and agreed to toe shortening. All operations were performed bilaterally, and postoperative management remained the same.<sup>10</sup>

### **Results**

The study focuses on one-stage lengthening for single ray involvement, aiming to achieve a good cosmetic result with restoration of a functional metatarsal parabola. The average length gain and percentage increase of 68 bones, including 56 metatarsals and 12 proximal phalanges, were 13 (5-21) mm and 33 (11-65)% respectively. In 56 metatarsal lengthening procedures, length-gain averaging 14 (6-21) mm was obtained, equivalent to an increase of 32 (11-51%). For the 12 proximal phalangeal lengthening procedures, the corresponding figures were 8 (5-11) mm and 54 (47-65%).<sup>11</sup>

The primary goal of treatment for 13 metatarsals and three proximal phalanges was to obtain a cosmetic result with restoration of a functional metatarsal parabola. When evaluating patients with this deformity, the number of affected rays was considered first, followed by the amount of required lengthening.<sup>12</sup> In cases of single ray involvement, the authors always tried to restore the normal length of the metatarsal. Shortening of an adjacent bone reduced target length and enabled them to carry out a one-stage lengthening instead of gradual distraction.

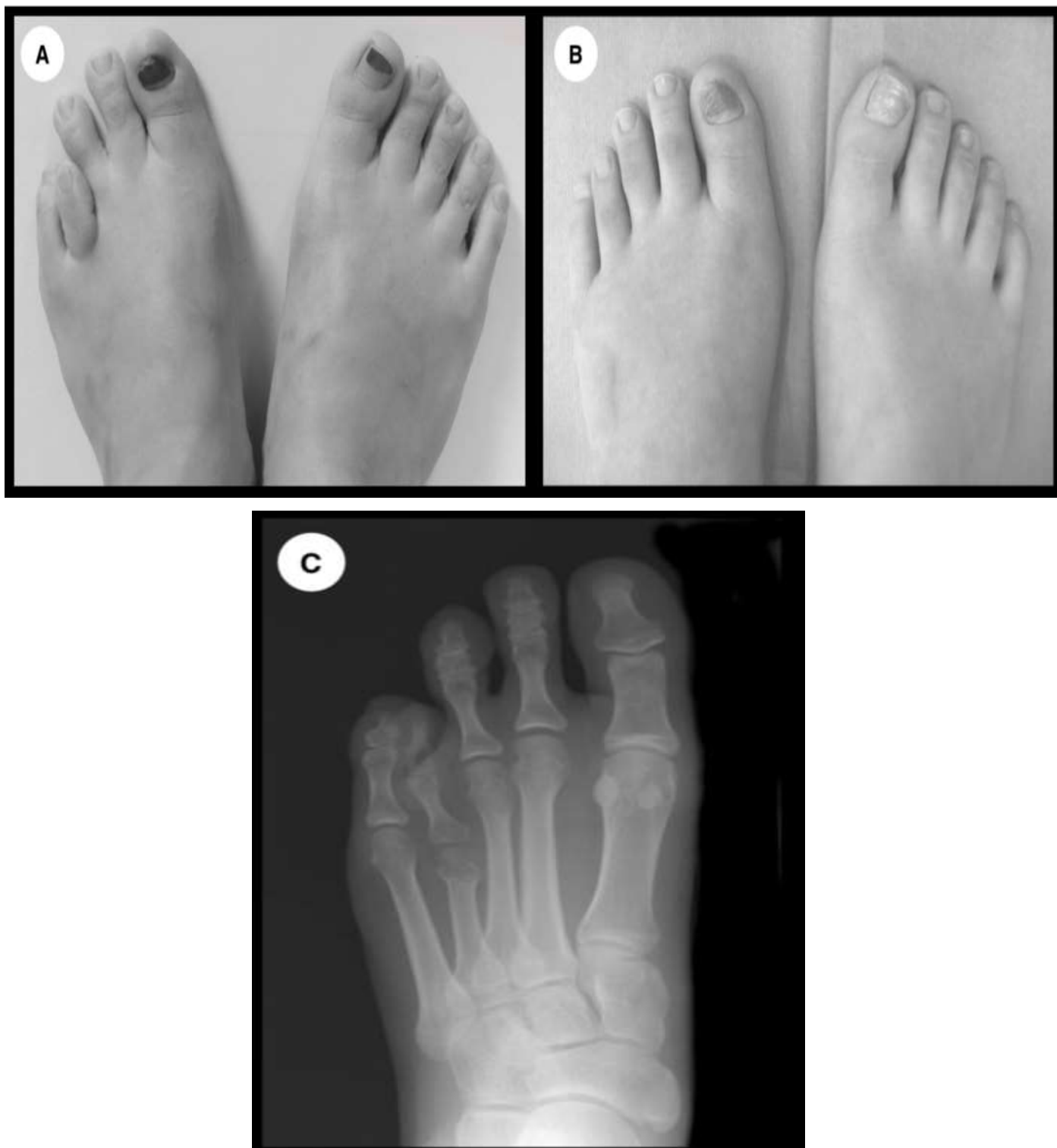

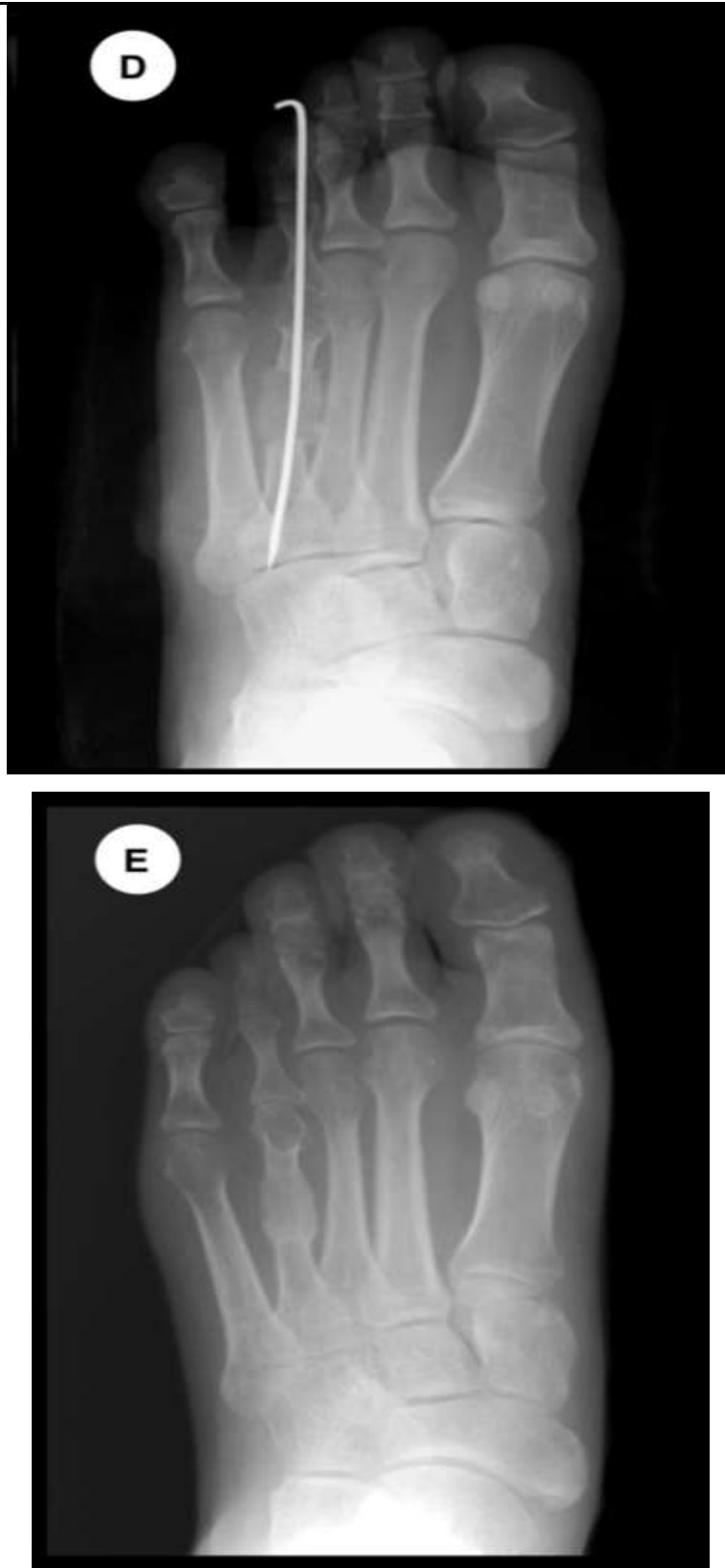


Fig: 1 The radiographs show an anteroposterior view of before and after operation of bone graft.

Average Length Percentage	Equivalent Length percentage
13 (5-21) % mm	33 (11-65) % mm
14 (6-21) % mm	32 (11-51) % mm
8 (5-11) % m	54 (47-65) % mm

In almost all cases of single ray involvement, the authors were able to lengthen the metatarsal by one-stage lengthening with intercalary bone graft without neurovascular impairment. If longer lengthening was required, they were able to restore normal ray length with concomitant proximal phalangeal lengthening without functional impairment, and gradual lengthening with callus distraction was not necessary. 13

Proximal phalangeal lengthening was effective to get a cosmetic (toe-tip) parabola when intraoperative gradual distraction of the metatarsal could not achieve a satisfactory ray length.<sup>14</sup> Although it is ideal to accomplish both metatarsal and toe-tip parabolas, the authors believe that toe-tip parabola is more important than metatarsal head parabola to the patients, as most have no pain or functional problem with their disturbed metatarsal head parabola preoperatively and their concern is mainly cosmesis.

Intraoperative gradual distraction using the phenomenon of creep and stress relaxation has been found sufficient to gain up to 21 mm of lengthening. Cutting the adjacent deep transverse metatarsal ligaments were effective to gain more soft tissue release without noticeable adverse effects. 15 Gradual lengthening by callotaxis can use more creep and stress relaxation than intraoperative gradient distraction, but the overall radiologic and clinical results of the two methods were comparable in terms of length gain, complications, cosmesis, and patient satisfaction.

## Conclusion

Congenital brachymetatarsia can occasionally be difficult to treat, and there is a risk of several problems during or following surgery. Nonetheless, positive outcomes are possible if the surgical approach is properly customized to match the patient's expectations and overall foot appearance. Anticipated for the treatment of brachymetatarsia congenita.

---

**Reference**

1. Urano Y, Kobayashi A. Bone-lengthening for shortness of the fourth toe. *J. Bone Joint Surg.* 60, 91–93 (1978).
2. McGlamry ED, Cooper CT. Brachymetatarsia: a surgical treatment. *J. Am. Psycho. Anal.* 59, 259–264 (1969).
3. Marcinko D, Rappaport M, Gordon S. Post-traumatic brachymetatarsia. *J. Foot Surg.* 23, 451–453 (1984).
4. Ferrandez L, Yubero J, Usabiaga J, Ramos L. Congenital brachymetatarsia: Three cases. *Foot Ankle* 14, 529–533 (1993).
5. Kawashima T, Yamada A, Ueda K, Harii K: Treatment of brachymetatarsia by callus distraction (Callotaxis). *Ann. Plast. Surg.* 32, 191–199 (1994).
6. Masuda T, Matoh N, Nakajima T, Tomi M, Ohba K. Treatment of brachymetatarsia using a semicircular lengthener. 1–3 years results in 6 patients. *Acta Orthop. Scand.* 66, 43–46 (1995).
7. McGlamry ED, Banks AS, Downey MS. In: *Comprehensive Textbook of Foot Surgery*. Vol. 2, Second ed. Baltimore: Williams and Wilkins 1211–1231 (1992).
8. Takakura Y, Tanaka T, Fujii T, Tamai S. Lengthening of short great toes by callus distraction. *J. Bone Joint Surg.* 79, 955–958 (1997).
9. Masada K, Fujita S, Fuji T, Ohno H. Complications following metatarsal lengthening by callus distraction for brachymetatarsia. *J. Pediatr. Orthop.* 19, 394–397 (1999).
10. Wada A, Bensahel H, Takamura K, Fujii T, Yanagida H, Nakamura T. Metatarsal lengthening by callus distraction for brachymetatarsia. *J. Pediatr. Orthop.* 13, 206–210 (2004).
11. Fox IM. Treatment of brachymetatarsia by the callus distraction method. *J. Foot Surg.* 37, 391–395 (1998).
12. Goforth WP, Overbeek TD. Brachymetatarsia of the third and fourth metatarsals. *J. Am. Podiatr. Assoc.* 91, 373–378 (2001).
13. Handelman RB, Perlman MD, Coleman WB. Brachymetatarsia: a review and case report. *J. Am. Podiatr. Assoc.* 76, 413–416 (1986).
14. Kim JS, Baek GH, Chung MS, Yoon PW. Multiple congenital brachymetatarsia. A one stage combined

---

shortening and lengthening procedure without iliac bone graft. *J. Bone Joint Surg.* 86, 1013–1015 (2004).

15. Kim HT, Lee SH, Yoo CI, Kang JH, Suh JT. The management of brachymetatarsia. *J. Bone Joint Surg.* 85, 683–690 (2003).



Medtronic