



Case Report

**Neuroblastoma with Orbital Metastasis: Review of Literature and
A Case Report**

Dr Rahul Singh ¹, Dr Shagufa Jamal ², Dr Himani Sharma* ³, Dr Hemkant Verma ⁴

1. Assistant Professor Department of Ophthalmology NIIMS Greater Noida
2. Senior Resident, Department of Ophthalmology NIIMS Greater Noida
3. Assistant professor- Department of Otorhinolaryngology & Head and Neck surgery NIIMS Greater Noida
4. Consultant Surgical Oncology.

***Correspondence to:** Dr Himani Sharma, Assistant professor- Department of Otorhinolaryngology & Head and Neck surgery NIIMS Greater Noida.

Copyright.

© 2024 **Dr Himani Sharma**. This is an open access article distributed under the Creative Commons Attribution License, which permits unrestricted use, distribution, and reproduction in any medium, provided the original work is properly cited.

Received: 14 May 2024

Published: 01 June 2024

DOI: <https://doi.org/10.5281/zenodo.15128680>

Abstract

Aim: To determine clinical characteristics including age, gender, presenting symptoms, systemic location involved, neuroblastoma stage, radiological & histological evidences, and outcome among children of neuroblastoma with orbital metastasis.

Methods: PUBMED search and Ovid Medline search had been carried out for relevant literature on neuroblastoma with orbital metastases between 2000 -current.

Case Report: A 18 months-old boy presented with low grade fever, anorexia, abdominal distension, weight loss and proptosis for 40 days. After detailed examination, radiological investigation and biopsy diagnosed as diagnosed a stage IV neuroblastoma with hepatic metastases and osseous metastatic lesion of left orbit and started on chemotherapy.

Results: We came across 27 neuroblastoma cases with orbital metastases in our search. The mean age at diagnosis for all 28 patients was 28.49 months. Adrenal gland (60.7%) was most frequently reported primary site of tumor. Proptosis (67.86%) and periorbital ecchymoses (60.71%) were found to be most common symptoms in neuroblastoma with orbital metastases.

Keywords: neuroblastoma; orbital metastasis; adrenal tumor; proptosis; periorbital ecchymosis.

INTRODUCTION

Neuroblastoma is the most common extracranial pediatric solid tumor. It constitutes 7-8% of all pediatric cancers.¹ Its incidence is of around 1 to 3 in 100,000 cases.^{2,3} This accounts for 15% of total pediatric cancer-related mortality.⁴ Neuroblastoma is a malignancy of sympathetic-adrenal lineage of the neural crest and thus it can arise at any site of sympathetic nervous system.⁵ It most frequently originates adrenal region (48%) followed by extra-adrenal retroperitoneum (25%), and chest (16%).^{1,5-7} Forty-eight percent of patients found to have wide spread metastases at the time of presentation.^{7,8} Most common sites of metastasis are bone marrow (70.5%), skeleton (55.7%), lymph nodes (30.9%), liver (29.6%), or intracranial and orbit (18.2%).⁹ Neuroblastoma can rapidly metastasize to orbit. Orbital metastases occur in about 10%-20% of all patients. It

is indicated by proptosis and periorbital ecchymosis (raccoon eyes).^{7,8,10-12} These two signs are the most frequently noticed and classic signs of orbital metastasis.^{7,8} Other indications of orbital involvement are Horner syndrome,¹³⁻¹⁶ opsoclonus/myoclonus,¹⁷ ocular motility defects,^{10,18} ptosis,¹⁸ and blindness.^{11,19} Presence of orbital signs indicate extensive malignancy load and poor prognosis.²⁰

In the current paper, we have reviewed the cases of neuroblastoma with orbital metastasis and report a case of 1½ year old boy diagnosed as neuroblastoma with orbital and hepatic metastases. Ethics approval for the current study was obtained from the ethical committee meeting, Noida International Institute of Medical Sciences, Greater Noida. All methods done in this study were in agreement with the ethical guidelines of the Helsinki declaration.

CASE REPORT

A one and half year-old boy visited Pediatric OPD with the complaints of low-grade fever, anorexia, abdominal distension, and weight loss for 15 days. His mother also complained of progressively increasing swelling of left eye for 5 days. On physical examination, patient was afebrile and moderate pallor was present. Per abdomen examination revealed non-tender, soft lump in right hypochondrium to right lumbar quadrant up to midline. His weight was 7.2 kg (expected weight=12.2 kg) and height was 70 cm (expected height=87.8 cm). Ophthalmological examination revealed inferior globe dystopia and proptosis of left eye (Figure 1 and 2). Anterior segment was normal in both eyes. Fundus evaluation demonstrated choroidal folds in left eye, rest of the findings were normal in both eyes. UBM scan of left orbit showed large homogenous lesion superior to globe with mild to moderate spikes (Figure 3). The laboratory investigation revealed hemoglobin level 8g/dL, total leucocyte count 8,200/mm³, platelet count 32,500/mm³ and erythrocyte sedimentation rate 33.2mm in first hour. Twenty-four hour urinary vanilly-mandelic acid level was found to be elevated (68 µmol/mL; normal=0-10 µmol/mL). Bone marrow aspiration discovered infiltration with round cell indicative of neuroblastoma. Abdominal USG disclosed a large heterogeneously hypoechoic mass (78×30×24 cm in size) with multiple foci of calcification in right hypochondrium crossing midline causing mass effect and medially displacing aorta and inferior vena cava. Abdominal USG findings further supported by magnetic resonance imaging (MRI) which also revealed hepatic metastases. Contrast enhanced CT orbit findings reported a relatively well defined heterogeneously enhancing soft tissue mass lesion of size 32×25×27 mm in extraconal space of left orbit, possibly arising superolateral wall (frontal bone) of left orbit showing speculated/ 'sun-ray' periosteal reaction(Figure 4). Mass effect was evidenced by inferior and lateral displacement of left extra-ocular muscles, optic nerve, and eye globe with proptosis. USG guided true-cut biopsy of abdominal mass

reveled neuroblastoma. Based on above-mentioned signs and investigations, child was diagnosed as a stage IV with hepatic metastases and osseous metastatic lesion of left orbit. Department of Pediatric Oncology started chemotherapy (cisplatin, doxorubicin, etoposide, and ifosfamide) with injection ondansetron and injection ranitidine. On further following the child, he developed exposure keratopathy in affected eye (Figure 5). Unfortunately, child died while undergoing chemotherapy.

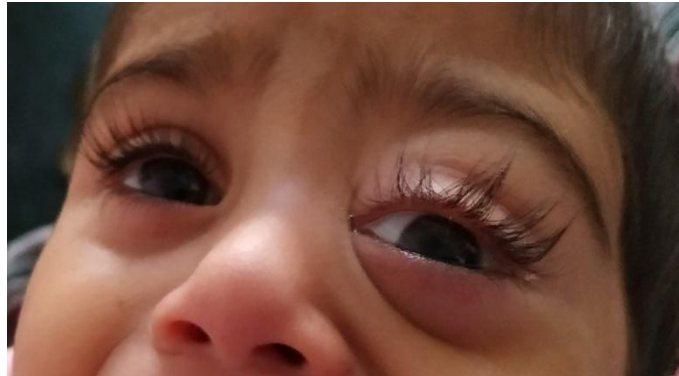

Figure 1. The photograph of the 18-months-old boy of neuroblastoma with orbital metastases showing the proptosis and inferior dystopia on the day of presentaion.

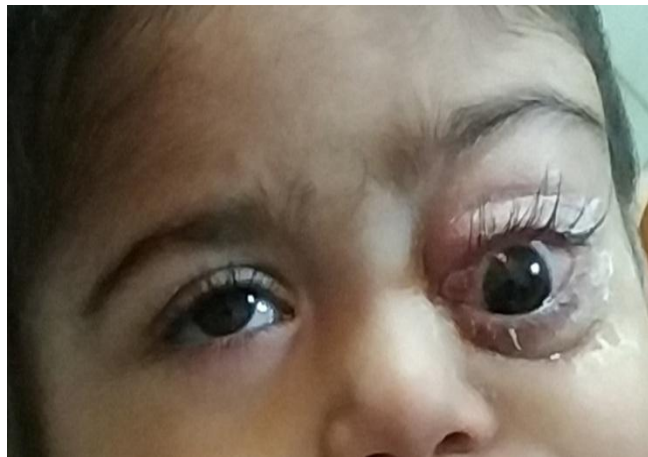

Figure 2. Day 4 photograph of the boy showing increased proptosis and dystopia.

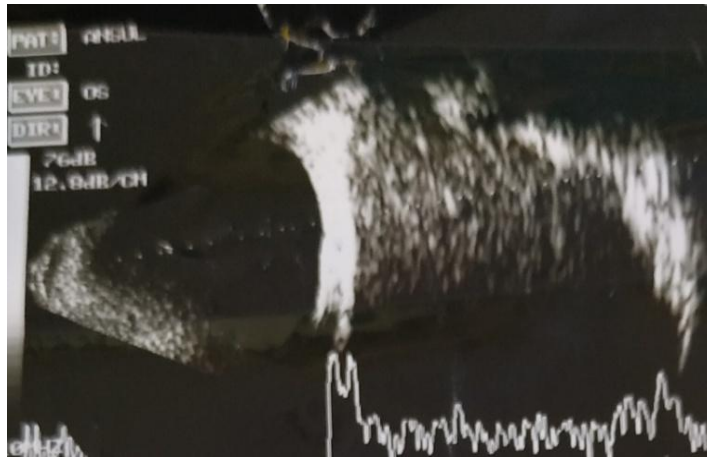


Figure 3. Ultrasound biomicroscopy scan of left orbit showing homogenous lesion superior to globe with mild to moderate spikes.

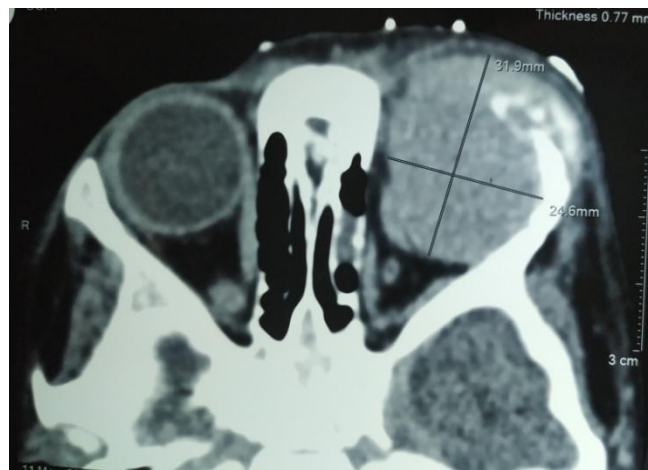


Figure 4. An axial contrast enhanced CT orbit reveal left eye proptosis and heterogeneously enhancing soft tissue mass lesion of size 32×25×27 mm in extraconal space of left orbit, possibly arising superolateral wall (frontal bone) of left orbit showing speculated/ 'sun-ray' periosteal reaction (arrow head). CT=computed tomography.

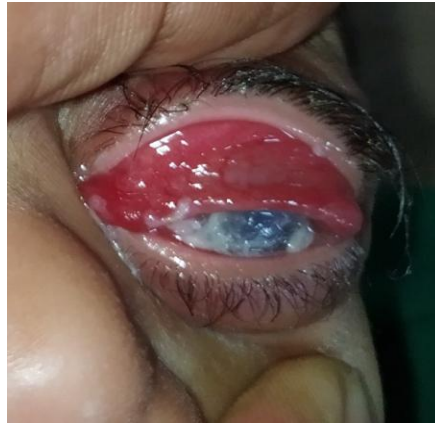

Figure 5. Day 11 photograph of the boy showing increased proptosis, palpebral conjunctiva congestion and corneal keratopathy.

DISCUSSION

Neuroblastoma has unexplained predisposition to orbital metastases causing proptosis, periorbital ecchymosis, and range of orbital manifestations.²⁰ Orbital involvement often has extraosseous soft tissue components causing proptosis.^{10,21} Periorbital ecchymosis is detected in 28–33% of all cases and is because of obstruction of vessels by tumor cells.²²⁻²⁴ In 1999, DuBois et al. reported amplification of tumor MYCN, a poor prognostic marker in cases of neuroblastoma with orbital metastases.⁹ International Neuroblastoma Risk Group (INRG) classification system and International Neuroblastoma Staging System (INSS) categorized tumors that are widely metastatic as Stages M and Stage IV, respectively.^{7,20} In the current paper, we report a case of 1½ year old boy diagnosed as stage IV neuroblastoma with orbital and hepatic metastases who presented with proptosis as initial symptoms. We came to the diagnosis of neuroblastoma with the aid classical symptoms, radiological investigations, and distinctive histological features. Unfortunately, our patient succumbed to death on the course of treatment. PUBMED search had been carried out for relevant literature on neuroblastoma with orbital metastases between 2000 and 2020. Twenty-seven cases of neuroblastoma with orbital metastases were found (Table 1).

Case No.	Year at Diagnosis/Publication	Age at Diagnosis (months)	Gender	Presenting Symptoms	Primary Site	Radiological Findings Suggestive of Neuroblastoma	Histological Findings Suggestive of Neuroblastoma	Treatment	Stage	Final Outcome
1 ⁸	1969	42.6 months	F	B/L periorbital ecchymosis, B/L painful proptosis	R adrenal	Present	Present	Chemotherapy	IV	Died of disease
2 ⁸	1970	21.5	M	Reduced appetite, fever, hematuria, R ptosis, R subconjunctival hemorrhage	L adrenal	Present	Present	Radiation and chemotherapy	IV	Died of disease
3 ⁸	1976	29.7	F	Lethargic, purpura, thrombocytopenia, anemia, R proptosis, R ecchymosis, R ptosis, B/L temporal tumor nodules	L adrenal	Present	Present	Resection of L adrenal, L metastatic lymph nodes, L nephrectomy. Radiation and chemotherapy	IV	Died of disease
4 ⁸	1977	34.8	F	Irritability, dehydration, fever, lethargy, L proptosis	L adrenal	Present	Present	Resection of L adrenal, L kidney and L peri-aortic lymph nodes. Radiation and chemotherapy	IV	Died of disease
5 ⁸	1981	24.5	M	Fatigue, fever, poor	L adrenal	Present	Present	Radiation and	IV	Died of disease

				appetite, swollen L testicle, L proptosis and ecchymosis				chemotherapy		
6 ⁸	1987	29.5	M	B/L periorbital ecchymosis, tender abdomen, ataxic gait	R abdomen	Present	Present	Resection of R abdominal mass and peri-aortic lymph nodes	IV	Died of disease
7 ¹⁰	2005	48	F	R proptosis, R subconjunctival hemorrhage	L adrenal	Not reported	Not reported	Not reported	Not reported	Blind right eye, under treatment
8 ¹⁰	2005	15	F	Not reported	L paravertebral mass	Present	Not reported	Not reported	Not reported	Under treatment
9 ¹⁰	2005	17	M	L proptosis, periorbital ecchymosis, ocular motility defect	R adrenal	Not reported	Not reported	Not reported	Not reported	Hearing loss, developmental delay, disease free
10 ¹⁰	2005	69	M	L proptosis, ocular motility defect	R adrenal	Not reported	Not reported	Not reported	Not reported	Under treatment
5 ¹¹	2005	10	M	R proptosis,	L adrenal	Not reported	Not reported	Not reported	Not reported	Under treatment
12 ¹⁰	2005	20	M	L periorbital ecchymosis	L adrenal	Not reported	Not reported	Not reported	Not reported	Died of disease
13 ²⁵	2001	26	M	Periorbital swelling, ecchymosis, subconjunctival hemorrhage, pancytopenia	Abdomen	Present	Present	Chemotherapy	IV	Not reported
14 ²⁶	2003	30	M	Visual loss	L paravertebral region	Present	Present	Chemotherapy	IV	Remission

					in the thorax					
15 ²⁷	2004	14	F	R proptosis, bilateral proptosis, oedema of the eyelids, and periorbital ecchymosis	Not reported	Not reported	Not reported	Chemotherapy	IV	Disease free
16 ²⁸	2005	15	M	Periorbital ecchymoses, proptosis, abdominal pain, fever, vomiting	L suprarenal region	Present	Not reported	Not reported	Not reported	Not reported
17 ²⁹	2007	10	F	Periorbital edema, ecchymosis proptosis	L suprarenal mass	Present	Present	Local treatment	IV	Not reported
18 ³⁰	2010	12	M	Periorbital ecchymoses	R adrenal	Present	Not reported	Not reported	IV	Not reported
19 ³¹	2010	20	F	L orbital swelling	Unknown	Present	Present	Chemotherapy	IV	Disease-free at last follow-up of 4 months
20 ³²	2011	24	F	Fever, L proptosis, L periorbital ecchymosis, mass in upper abdomen	Abdomen	Present	Present	Chemotherapy, Resection of abdominal tumor, radiotherapy	IV	Disease free
21 ³³	2012	21	M	Periorbital ecchymoses, proptosis, face swelling,	Not reported	Present	Present	Chemotherapy	Not reported	Died of disease
22 ³³	2012	30	M	Periorbital ecchymoses, edema	Abdomen	Present	Present	Chemotherapy	Not reported	Died of disease
23 ³⁴	2012	36	M	Periorbital ecchymoses, proptosis, vision loss,	R adrenal	Present	Present	Chemotherapy	IV	No evidence of recurrence

				hepatospleno megaly						ce within the follow- upperio d of 6 months
24 ³⁵	2016	60	M	Proptosis, decreased supraduction	Paraspi nal	Present	Present	Not reported	IV	Not reported
25 ³⁶	2017	48	M	Proptosis, periorbital ecchymosis, weight loss, headache, vomiting	R suprare nal region	Present	Present	Not reported	IV	Not reported
26 ²⁴	2019	36	F	Periorbital ecchymoses, proptosis, subconjunctiv al hemorrhage, anemia	L adrenal	Present	Present	Patient refused treatment	IV	Alive at the 6- month follow- up
27 ³⁷	2020	36	M	Swelling and bleeding from the maxillary L posterior region, fever, B/L proptosis	R suprare nal region	Present	Present	Not reported	Not re ported	Not reported
Pres ent case	2020	18	M	Fever, anorexia, L proptosis	Abdom inal	Present	Present	Chemothe rapy	IV	Died of disease

Table 1. Summary of patient of neuroblastoma with orbital metastases. M=Male; F= Female; B/L=Bilateral; R=Right; L=Left.

Table 1 enumerates the clinical characteristics of all 28 neuroblastoma cases with orbital metastases, including age, presenting symptoms, systemic location involved, neuroblastoma stage, radiological & histological evidences, and final outcome. The mean age at diagnosis for all 28 was 28.49 months (range, 10–69 months) and 18 cases (64.29%) were male. Seventeen (60.7%) of the tumor were in the adrenal gland primarily followed by 5 (17.86%) of case were in the abdomen and 3(10.71%) were cited in paravertebral/paraspinal

region. In 1 (3.57%) case, primary site of origin of tumor was not found while in 2 (7.14%) cases primary site was not reported in the respective study. Eighteen (64.29%) of the 28 cases were in stage IV and in rest 10 (35.71%) case, exact stage was not mentioned in the study.

Proptosis and periorbital ecchymoses are considered as classic signs of neuroblastoma with orbital involvement. Present review of literature was also consistent with these symptoms and proptosis (19/28, 67.86%) followed by periorbital ecchymosis (17/28, 60.71%; Table 1) were found to be the most frequent symptoms of neuroblastoma with orbital metastases. Other less encountered ocular findings were lid, periorbital, orbital, or adjacent face swelling/edema (6/28, 21.43 %), subconjunctival hemorrhage (4/28, 14.29%), vision loss (2/28, 7.14%), and reduced ocular motility (3/28, 10.71%). Ten patients died of disease, out of these 10 patients 6 were diagnosed from 1969 through 1987. So, this mortality rate does not represent the current advanced management protocols and as all the cases had orbital signs which indicate extensive malignancy load and poor prognosis.

Harreld et al. compared 222 neuroblastoma cases with and without orbital, calvarial and non-orbital bone metastasis. They found reduced overall survival and 5-year survival in patients ≥ 18 months of age with orbital involvement. They also concluded greater preponderance of orbital bone metastases with periorbital ecchymosis.³⁸ In a retrospective study done by Smith et al found higher survival rate for all fourteen cases diagnosed of neuroblastoma (57% at 1 year and 50% at 5 years) while lower survival rate in those six patients with ophthalmic manifestation (17% at nine months).⁸ Thus Smith et al. concluded orbital metastasis as poor prognostic factor.⁸ In another large series of 405 children with neuroblastoma, 75% (60 of 80) of cases with orbital involvement had proptosis or periorbital ecchymosis.³⁹ In another case series of 20 cases, 20% of neuroblastoma cases presented with proptosis.⁴⁰

According to the one study, overall survival (OS) of disseminated neuroblastoma is as low as 22–27%, compared to up to 91% in those lacking distant metastases.⁴¹ Due to the lack of details of the patients, details of last three studies were not entered in Table 1.

Neuroblastoma is a multisystem disease and requires multidisciplinary management. Timely diagnosis and management can be started by understanding clinical presentation, specific radiological & histological findings and biological (N-myc amplification, and levels of lactate dehydrogenase, ferritin, and neuron-specific enolase) characteristics. The treatment of neuroblastoma has changed drastically over the last few decades but mortality in children with orbital metastasis remains high. Advancements in stem cell transplantation and immunotherapy will hopefully translate into reduced mortality. In the

To conduct the literature review, we performed a PubMed search of the medical literature for the using the

following keywords in various combinations: neuroblastoma, orbital metastasis, adrenal tumor, proptosis, periorbital ecchymosis. In addition, literature review was done by means of Ovid Medline search with the following mesh headings: exp * neuroblastoma, orbital metastasis / proptosis /, periorbital ecchymosis /, adrenal tumor/, limited to English language, and from 2000-current. In addition, reference lists from the selected articles were used to obtain further articles.

Declaration of patient consent

The authors certify that they have obtained all appropriate consent forms from patient's legal guardians. In the form the patient's legal guardians has/have given his/her/their consent for his/her/their images and other clinical information to be reported in the journal. The patient's legal guardians understand that their child's names and initials will not be published, and due efforts will be made to conceal their identity, but anonymity cannot be guaranteed.

Financial support and sponsorship: Nil.

Conflicts of interest: There are no conflicts of interest.

References

1. Maris JM. Recent advances in neuroblastoma. *N Engl J Med*. 2010;362(23):2202-2211. doi:10.1056/NEJMra0804577
2. Bernstein ML, Leclerc JM, Bunin G, et al. A population-based study of neuroblastoma incidence, survival, and mortality in North America [published correction appears in *J Clin Oncol* 1992 Jul;10(7):1202]. *J Clin Oncol*. 1992;10(2):323-329. doi:10.1200/JCO.1992.10.2.323
3. Gutierrez JC, Fischer AC, Sola JE, Perez EA, Koniaris LG. Markedly improving survival of neuroblastoma: a 30-year analysis of 1,646 patients. *Pediatr Surg Int*. 2007;23(7):637-646. doi:10.1007/s00383-007-1933-7
4. Kim S, Chung DH. Pediatric solid malignancies: neuroblastoma and Wilms' tumor. *Surg Clin North Am*. 2006;86(2):469-xi. doi:10.1016/j.suc.2005.12.008
5. Maris JM, Hogarty MD, Bagatell R, Cohn SL. Neuroblastoma. *Lancet*. 2007;369(9579):2106-2120. doi:10.1016/S0140-6736(07)60983-0
6. Castleberry RP. Biology and treatment of neuroblastoma. *Pediatr Clin North Am*. 1997;44(4):919-937. doi:10.1016/s0031-3955(05)70537-x

-
7. Brisse HJ, McCarville MB, Granata C, et al. Guidelines for imaging and staging of neuroblastictumors: consensus report from the International Neuroblastoma Risk Group Project. *Radiology*. 2011;261(1):243-257. doi:10.1148/radiol.11101352
 8. Smith SJ, Diehl NN, Smith BD, Mohny BG. Incidence, ocular manifestations, and survival in children with neuroblastoma: a population-based study. *Am J Ophthalmol*. 2010;149(4):677-682.e2. doi:10.1016/j.ajo.2009.11.027
 9. DuBois SG, Kalika Y, Lukens JN, et al. Metastatic sites in stage IV and IVS neuroblastoma correlate with age, tumor biology, and survival. *J PediatrHematol Oncol*. 1999;21(3):181-189. doi:10.1097/00043426-199905000-00005
 10. Ahmed S, Goel S, Khandwala M, Agrawal A, Chang B, Simmons IG. Neuroblastoma with orbital metastasis: ophthalmic presentation and role of ophthalmologists. *Eye (Lond)*. 2006;20(4):466-470. doi:10.1038/sj.eye.6701912
 11. Belgaumi AF, Kauffman WM, Jenkins JJ, et al. Blindness in children with neuroblastoma. *Cancer*. 1997;80(10):1997-2004.
 12. Musarella MA, Chan HS, DeBoer G, Gallie BL. Ocular involvement in neuroblastoma: prognostic implications. *Ophthalmology*. 1984;91(8):936-940. doi:10.1016/s0161-6420(84)34211-7
 13. Zafeiriou DI, Economou M, Kolioukas D, Triantafyllou P, Kardaras P, Gombakis N. Congenital Horner's syndrome associated with cervical neuroblastoma. *Eur J Paediatr Neurol*. 2006;10(2):90-92. doi:10.1016/j.ejpn.2006.01.004
 14. Sauer C, Levingohn MW. Horner's syndrome in childhood. *Neurology*. 1976;26(3):216-220. doi:10.1212/wnl.26.3.216
 15. Mahoney NR, Liu GT, Menacker SJ, Wilson MC, Hogarty MD, Maris JM. Pediatric horner syndrome: etiologies and roles of imaging and urine studies to detect neuroblastoma and other responsible mass lesions. *Am J Ophthalmol*. 2006;142(4):651-659. doi:10.1016/j.ajo.2006.05.047
 16. Jeffery AR, Ellis FJ, Repka MX, Buncic JR. Pediatric Horner syndrome. *J AAPOS*. 1998;2(3):159-167. doi:10.1016/s1091-8531(98)90008-8
 17. Farrelly C, Daneman A, Chan HS, Martin DJ. Occult neuroblastoma presenting with opsomyoclonus: utility of computed tomography. *AJR Am J Roentgenol*. 1984;142(4):807-810. doi:10.2214/ajr.142.4.807
 18. Alfano JE. Ophthalmological aspects of neuroblastomatosis: a study of 53 verified cases. *Trans Am AcadOphthalmolOtolaryngol*. 1968;72(6):830-848.
 19. Shubert EE, Oliver GL, Jaco NT. Metastatic neuroblastoma causing bilateral blindness. *Can J Ophthalmol*.
-

1969;4(1):100-103.

20. Maris JM, Hogarty MD, Bagatell R, Cohn SL. Neuroblastoma. *Lancet*. 2007;369(9579):2106-2120. doi:10.1016/S0140-6736(07)60983-0
21. Chung EM, Murphey MD, Specht CS, Cube R, Smirniotopoulos JG. From the Archives of the AFIP. Pediatric orbit tumors and tumorlike lesions: osseous lesions of the orbit. *Radiographics*. 2008;28(4):1193-1214. doi:10.1148/rg.284085013
22. Amemiya T, Hayashida H, Dake Y. Metastatic orbital tumors in Japan: a review of the literature. *Ophthalmic Epidemiol*. 2002;9(1):35-47. doi:10.1076/oep.9.1.35.1718
23. Shields JA, Shields CL, Brotman HK, Carvalho C, Perez N, Eagle RC Jr. Cancer metastatic to the orbit: the 2000 Robert M. Curts Lecture. *Ophthalmic PlastReconstr Surg*. 2001;17(5):346-354. doi:10.1097/00002341-200109000-00009
24. Yang WJ, Zhou YY, Zhao F, Mei ZM, Li S, Xiang Y. Orbital neuroblastoma metastasis: A case report and literature review. *Medicine (Baltimore)*. 2019;98(36):e17038. doi:10.1097/MD.00000000000017038
25. Cliff JF, Newman L, Malone M, Brady G, Crean SJ. Facial features of widespread neuroblastoma: a case report. *Int J Paediatr Dent*. 2001;11(3):215-220. doi:10.1046/j.1365-263x.2001.00269.x
26. Varma D, George N, Livingston J, Negi A, Willshaw HE. Acute visual loss as an early manifestation of metastatic neuroblastoma. *Eye (Lond)*. 2003;17(2):250-252. doi:10.1038/sj.eye.6700289
27. Russo G, Di Pietro M, La Spina M. Ocular involvement in neuroblastoma: not always metastasis. *Lancet Oncol*. 2004;5(5):324. doi:10.1016/S1470-2045(04)01472-X
28. Bay A, Faik Oner A. Raccoon eyes. *Indian Pediatr*. 2005;42(9):949.
29. Gumus K. A child with raccoon eyes masquerading as trauma. *Int Ophthalmol*. 2007;27(6):379-381. doi:10.1007/s10792-007-9089-y
30. Moran DE, Donoghue V. Periorbital ecchymosis ('raccoon eyes') as the presenting feature of neuroblastoma. *PediatrRadiol*. 2010;40(10):1710. doi:10.1007/s00247-009-1467-3
31. Salmi D, Patel C, Imashuku S, Shimada H, Satake N. Neuroblastoma of unknown primary site with periorbital bone metastasis in a child. *Pediatr Blood Cancer*. 2010;55(2):361-363. doi:10.1002/pbc.22524
32. Okura H, Yatomi K, Saito Y, et al. Unexpected intraparenchymal hematoma caused by brain metastasis in a patient with neuroblastoma: case report. *Neurol Med Chir (Tokyo)*. 2011;51(11):784-788. doi:10.2176/nmc.51.784
33. Muñiz AE. Metastatic neuroblastoma: the mimicker of basilar skull fracture in children. *J Emerg Med*. 2012;42(1):e19-e21. doi:10.1016/j.jemermed.2009.08.014

-
34. Ghosh SK, Dutta A, Basu M. Raccoon eyes in a case of metastatic neuroblastoma. *Indian J Dermatol Venereol Leprol.* 2012;78(6):740-741. doi:10.4103/0378-6323.102370
35. Kurian J, Chen NN, Shinder R. Orbital Metastatic Neuroblastoma. *Ophthalmology.* 2016;123(8):1674. doi:10.1016/j.opthta.2016.03.044
36. Mota EB, Penna CRR, Marchiori E. Metastatic Dissemination of a Neuroblastoma. *J Pediatr.* 2017;189:232-232.e1. doi:10.1016/j.jpeds.2017.05.069
37. Kalaskar RR, Kalaskar AR. Neuroblastoma in early childhood: A rare case report and review of literature. *Contemp Clin Dent.* 2016;7(3):401-404. doi:10.4103/0976-237X.188579
38. Harreld JH, Bratton EM, Federico SM, et al. Orbital Metastasis Is Associated With Decreased Survival in Stage M Neuroblastoma. *Pediatr Blood Cancer.* 2016;63(4):627-633. doi:10.1002/pbc.25847
39. Musarella MA, Chan HS, DeBoer G, Gallie BL. Ocular involvement in neuroblastoma: prognostic implications. *Ophthalmology.* 1984;91(8):936-940. doi:10.1016/s0161-6420(84)34211-7
40. al-Mulhim I. Neuroblastoma in children: a 10-year experience in Saudi Arabia. *J Trop Pediatr.* 1998;44(2):77-80. doi:10.1093/tropej/44.2.77
41. Cohn SL, Pearson AD, London WB, et al. The International Neuroblastoma Risk Group (INRG) classification system: an INRG Task Force report. *J Clin Oncol.* 2009;27(2):289-297. doi:10.1200/JCO.2008.16.6785.



Medtronic