



A 76-Year-Old Female Presents to your OPD with 3 Hours History of Weakness of Right Hand, Headache and Problem with Her Vision.

Dr Saad Hussain Gillani*, FRCP Glasgow, FRCP Edinburgh and MRCP UK

Corresponding Author: Dr Saad Hussain Gillani, FRCP Glasgow, FRCP Edinburgh and MRCP UK, Consultant Physician / Classified Medical Specialist, Fauji Foundation Hospital, Pakistan.

Copy Right: © 2022 Dr Saad Hussain Gillani, This is an open access article distributed under the Creative Commons Attribution License, which permits unrestricted use, distribution, and reproduction in any medium, provided the original work is properly cited.

Received Date: September 08, 2022

Published Date: September 20, 2022

Description

A 76-year-old female presents to your OPD with 3 hours history of weakness of right hand, headache and problem with her vision.

She also complains of lightheadedness, numbness and tingling on right arm and leg , and difficulty with her speech.

You take her BP which is found to be high at 160/89 mmHg.

She is also having a severe headache that has not responded to analgesics.

You suspect the patient could be having stroke in evolution and decide to order a CT scan of head and ECG and send bloods for further investigations.

Her CT scan is given below:

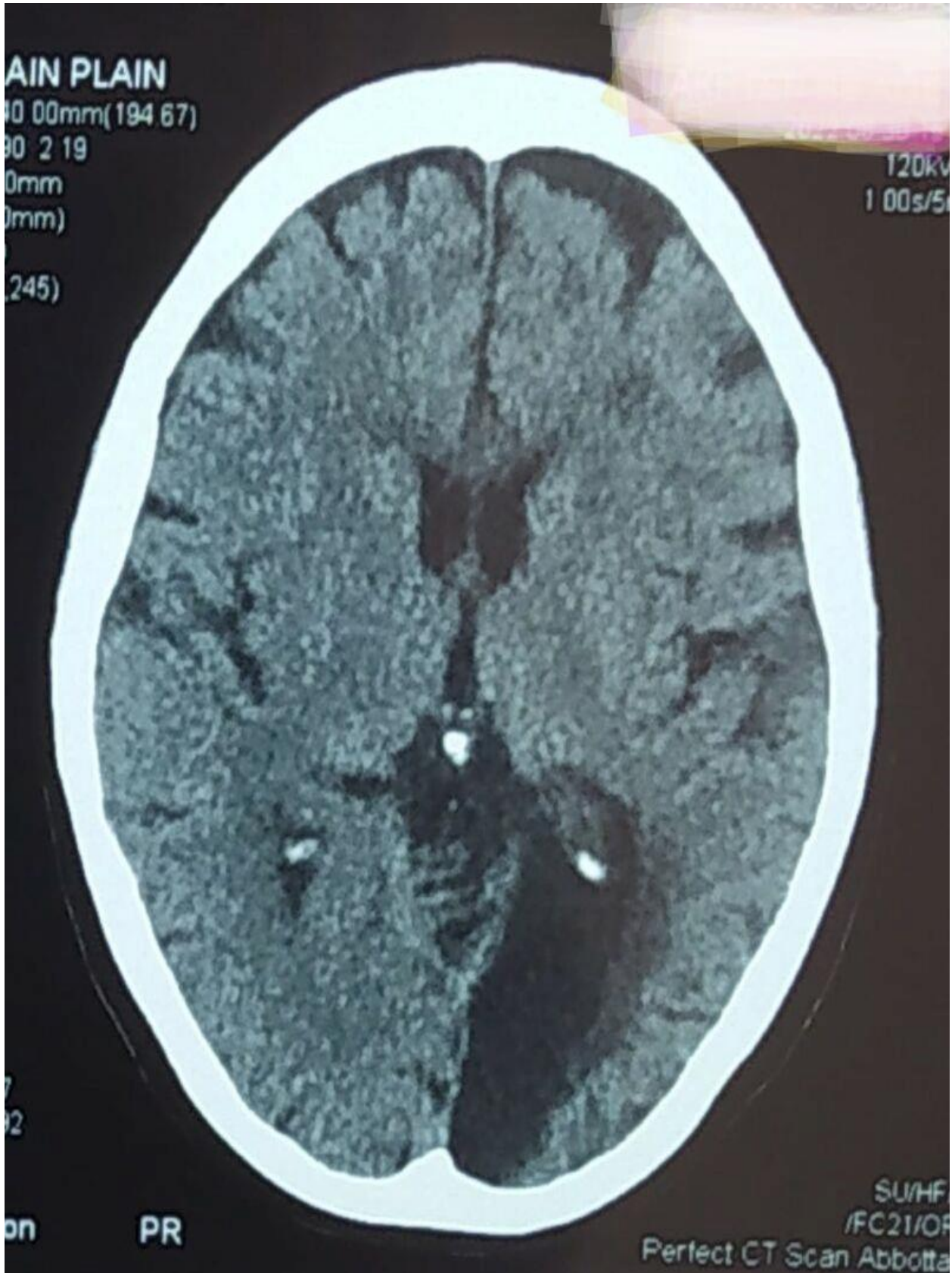
1. What are the findings in the CT scan.
2. Why do you want to conduct/ organize and ECG?
3. Which bloods should you send?
4. What is the most likely Diagnosis?
5. How would you manage this patient?

Discussion

1. What are the findings in the CT scan.

- The CT of the head is showing a left occipital infarct.
- Infarcts are visible as dark opacities on CT scan without contrast.
- This is a CT scan without contrast.
- CT images are conventionally viewed from below, as if looking up into the top of the head.
- This means the right side of the brain is on the left side of the viewer.
- So, as you look at the axial CT images, your left is the patients right side.
- So, the right side of the image depicts the left side of the patient.

Hence in this case, the occipital appears to be on the right side of the viewer but actually its showing the left side of patient, so the Occipital infarct is on the left side of the patient's brain.



2. Why do you want to conduct/ organize and ECG?

- We need to make sure the patient is not having a disturbed / irregular rhythm / atrial fibrillation as it can lead to development of cardiac thrombi and lead to stroke / cerebral infarcts.

3. Which bloods should you send?

- It is vital to determine underlying cause of stroke, most common on which include cardiac causes, diabetes mellitus, Hypercholesterolemia and hypertension.
- Bloods should be sent for Full blood count, CRP (to determine underlying sepsis) sugar levels , Lipid profile, urea, creatinine, and clotting profile , INR < PT , APTT , Prothrombin C and S levels , Factor V Leiden mutations to exclude pro thrombotic diseases and lupus anticoagulant.
- Other investigations include Echocardiogram, blood cultures in case of fever and urine R/E and culture and sensitivity.

4. What is the most likely Diagnosis?

- Most likely diagnosis is acute occipital infarct / CVA.

5. How would you manage this patient?

- Since it has been less than 4.5 hours and patient is developing an acute infarct , she should be managed by thrombolysis once exclusions of haemorrhage on neuro imaging has been done.

The drug of choice is Alteplase:

Alteplase Dosing for Acute Ischaemic Stroke

1. 0.9mg / kg body weight to maximum of 90mg
2. 10% total dose should be given as initial iv bolus
3. remainder (90%) should be infused iv over 60 mins in 0.9% sodium chloride (or can be given neat via a syringe pump).