



A Paradigm Shift in Pathological Diagnosis and Therapeutic Approach with Odontogenic Keratocysts! Is it Possible to Review Cautious Management?

Dr. Minal Sharma ¹, Dr. Ajinath Nanasaheb Jadhav*², Janardan B. Garde ³,

Dr. Uzma Siddiqui Hamidullah ⁴

1,4. Ex Resident, Department of Oral and maxillofacial surgery, MA Rangoonwala Dental College and research Centre, Pune, Maharashtra, India

2. Associate professor, Department of Dentistry, JIIU'S Indian Institute of Medical sciences and research, At Po. Warudi, Tq. Badnapur, Dist- Jalna -431202, Maharashtra, India.

3. Professor, Department of Oral and maxillofacial surgery, MA Rangoonwala Dental college and research center, Pune, Maharashtra, India.

Corresponding Author: Dr. Ajinath Nanasaheb Jadhav, Associate professor, Department of Dentistry, JIIU'S Indian Institute of Medical sciences and research, At Po. Warudi, Tq. Badnapur, Dist- Jalna -431202, Maharashtra, India.

Copy Right: © 2022 Dr. Ajinath Nanasaheb Jadhav, This is an open access article distributed under the Creative Commons Attribution License, which permits unrestricted use, distribution, and reproduction in any medium, provided the original work is properly cited.

Received Date: October 14, 2022

Published Date: November 01, 2022

Abstract

Background: Immunohistochemistry research, however, indicates that it may also be treated conservatively using techniques like marsupialization and enucleation with supplemental procedures. The ideal treatment strategy for this special cyst, renowned for its propensity for recurrence and aggressive behaviour, is still up for debate. Although not all surgeons, most favor removing the jaw and reconstructing it using a free fibular flap, a nonvascular flap, a titanium crib, or a recon plate. The purpose of this study is to compare the results of treating OKC using a decompression approach and treating OKC without a decompression technique, then performing enucleation and adding peripheral ostectomy and Carnoy's solution application as supplementary procedures.

Materials and methods: Twenty patients diagnosed with odontogenic keratocyst were recruited in study and divided in 2 groups. In group-1, 10 patients treated by marsupialisation followed by enucleation with adjunctive procedures including peripheral ostectomy and application of Carnoy's solution. In group 2, 10 patients were treated by without marsupialisation. The two groups were compared for following outcome.

- 1) Surgical site morbidity and physiologic, functional, and aesthetic rehabilitation.
- 2) Comparing Pre and postoperative clinical examinations for nerve damage
- 3) Lesion recurrence or the presence of radiolucency at three, six and 12 months after surgery.

Results: Patients treated in group-1 had less morbidity, physiology and easier functional and esthetic rehabilitation, Similarly patients in group-1 experienced minimal nerve injury and faster recovery. In both of the group none of the patient had recurrence of lesion after 5 years of follow-up period.

Conclusion: We can conclude that the protocol of decompression followed by enucleation with peripheral ostectomy and Carnoy's solution has promising results for large OKC's. Resection of jaw should be preserved to only recurrent cases of OKC's. Enucleation and peripheral ostectomy followed by Carnoy's solution application gives better outcome of management of OKC equally effective to that of en bloc resection.

Key words: odontogenic keratocyst, Marsupialisation, enucleation, peripheral ostectomy, Carnoy's solution.

Abbreviations

OKC: Odontogenic keratocyst

OPG: Orthopantomogram

CBCT: Cone beam Computed Tomography

KCOT: Keratocystic Odontogenic Tumor

Introduction

The maxillofacial region's dilemmatic odontogenic keratocyst has attracted a lot of interest over the past two decades [1]. Despite having distinctive histological and clinical traits, the cyst is nevertheless unique because of its aggressive nature and high recurrence rate [2]. Since 1887 up till 2017, numerous attempts have been made to categorise odontogenic keratocysts (OKC). Due to its aggressive behavior, high recurrence rates, and distinct histological characteristics, OKC was reclassified and renamed as keratocystic odontogenic tumour (KCOT) by WHO in its classifications of head and neck tumours in 2005. OKC had previously been classified by WHO as developmental odontogenic cyst of the jaw in 1971 and 1992 [3]. However, the KCOT has recently been reclassified by the WHO classification of Head and Neck pathology (2017) back into the cystic category [4].

Since its initial description, OKC has remained a mystery. Prior to the invention of antibiotics, marsupialization and decompression were frequently used to treat cysts [5]. A conservative approach to treatment is an option, as are more involved procedures including segmental and en bloc resection. The odontogenic keratocyst has a tendency to be treated more aggressively due to its clinical relevance, even up to jaw resection [6]. Immunohistochemistry research, however, indicates that it may also be treated conservatively using techniques such straightforward marsupialization and enucleation with supplemental procedures [7]. The ideal treatment strategy for this special cyst, renowned for its propensity for recurrence and aggressive behaviour, is still up for debate. Although not all surgeons, most favor removing the jaw and reconstructing it using a free fibular flap, a nonvascular flap, a titanium crib, or a recon plate. However, this method has a number of drawbacks, including denervation and devascularization of the tissue, longer operation times, the need for additional surgery sites, greater morbidity, and problems with free flaps, non-vascular flaps, or titanium implants. On the other hand, cautious therapy aids in reducing the cyst's size and avoiding radical procedures, hence reducing morbidity and minimising lesion recurrence [8].

The purpose of this study is to compare the results of treating OKC using a decompression approach and treating OKC without a decompression technique, then performing enucleation and adding peripheral ostectomy and carnoy's solution application as supplementary procedures [9]. Is it possible to prevent jaw resection, according to a study?

Materials and Method

A prospective, randomized clinical trial was carried out in our institute's department of oral and maxillofacial surgery after receiving ethical clearance from the university. The ethical committee granted official approval. The study involved 20 patients who needed surgery and had been clinically, histopathologically, and radiologically confirmed to have OKC.

Inclusion criteria:

1. Patients above the age of 18 years
2. Patients ready to give consent
4. Lesions radiographically larger than 3 centimeters.

Exclusion criteria:

1. Any patient with a severe systemic illness
2. Individuals with Recurrence of OKC
3. Patients who resisted giving their consent.

The following factors that determine how well OKC will respond to conservative management were observed.

- 1) Surgical site morbidity and physiologic, functional, and aesthetic rehabilitation.
- 2) Comparing Pre and postoperative clinical examinations for nerve damage
- 3) Lesion recurrence or the presence of radiolucency at three, six and 12 months after surgery.

In each patient, an orthopantomogram (OPG), cone beam computed tomography (CBCT) and neurovascular canal tracing were performed.

Method

The study was executed to evaluate the efficacy of surgical management of OKC with decompression technique (Group-1) and without decompression technique (Group-2).

Twenty patients in total were chosen for the randomised control experiment, and the randomization process used the flipping coin method. In group 1, ten patients received decompression, enucleation, peripheral ostectomy, and administration of Carnoy's solution. In group 2, an additional 10 patients received enucleation, peripheral ostectomy, and administration of Carnoy's solution without decompression procedure.

For both the study's recruitment and surgical treatment, a thorough case history and consents were obtained. Prior to the trial, preliminary clinical and radiological records were kept.

Group-1 surgical protocol (Images from 1-16 illustrates details of study procedure, surgical steps and healing of cystic cavity)

STAGE 1: Decompression

A window into the lesion was made during the decompression surgery, and the removed tissue was sent for histology. Depending on the size of the window, the decompression tube was constructed from a disposable 5cc or 2cc syringe needle cover. The substance was chosen since it was inert and did not hinder chewing. Using 24 gauge wire the tube was fastened to the nearby teeth in its intended location. For the first week, the patient was summoned back each day and instructed to self-irrigate using a 10ml syringe filled with saline and betadine solution through the decompression tube. A CBCT or OPG radiographic evaluation was performed every three months to evaluate the lesion. Depending on how long it took for the lesion to move at least 2 cm away from the lower border of the mandible and a crucial structure, follow-up was conducted for a period of 6–9 months. The formula $\frac{\text{Length/pixels at the end of decompression}}{\text{length/pixels in pre-decompression period}} \times 100$ was used to compute the percent of reduction. This shift in radiodensity indicated cyst contraction and concurrent bone deposition around the cystic cavity.

STAGE 2: Enucleation

The remaining cystic lesion was removed by enucleation, peripheral ostectomy, and the use of Carnoy's solution.

In order to completely enucleate the lesion, a bone window was formed using round bur drilling and an appropriate incision to reflect a full thickness periosteal flap. Following enucleation, extensive irrigation was used to perform a peripheral ostectomy up to 2 mm around the cavity. For chemical cauterization, freshly made Carnoy's solution, which contains 60% absolute alcohol, 30% chloroform, 10% glacial acetic acid, and 0.1 mg/ml ferric chloride, was poured in the cavity for five minutes. The inferior alveolar nerve was protected using Vaseline during the treatment, and soft tissues were carefully retracted using a pack of roller gauze. After that, 0.9% normal saline was used to effectively irrigate the entire cavity.

Patients who had enucleation were summoned back 7 and 14 days later to evaluate any nerve damage, morbidity, and radiographic results. After enucleation patients were followed till additional 24 months to see the amount of bone deposition and healing of cystic cavity and to observe recurrence. On the same device, all CBCT and OPG images were captured. The scale found on the CBCT and OPG, which had been used to gauge the degree of radiolucency, was utilised to compare the before and post-operative images by the same examiner. The radio densities of the photos were assessed using the histogram function in Adobe Photoshop CS5. The formula $\frac{\text{Length/pixels at the end of decompression}}{\text{length/pixels in pre-decompression period}} \times 100$ was used to compute the reduction's percentage.

Group-2

In remaining 10 patients cystic lesion was removed by enucleation, peripheral ostectomy, and Carnoy's solution under general anaesthesia by procedure similar to stage 2 procedure in group-1.

Results

Data was gathered, inputted, and duplicates removed in Microsoft Excel 2013. Using Shapiro Wilk's test, the data were initially examined for normality of distribution. It was discovered to have a typical distribution.

The Chi square test was used to compare the proportions between the two groups (Table no. 1 to 3)

The analysis was conducted using the social statistical package (SPSS; 22.0; IBM Analytics, New York; USA).

Nerve Paraesthesia	Group-1 (Decompression+ Enucleation)		Group-2 (Enucleation)	
	N	%	N	%
Reduced	01	10	00	0
Recovered	04	40	06	60
Persistent	01	10	03	30
No Paraesthesia	04	40	01	10
Total	10	100%	10	100%

Chi square= 4.2, degree of freedom= 3; p= 0.24

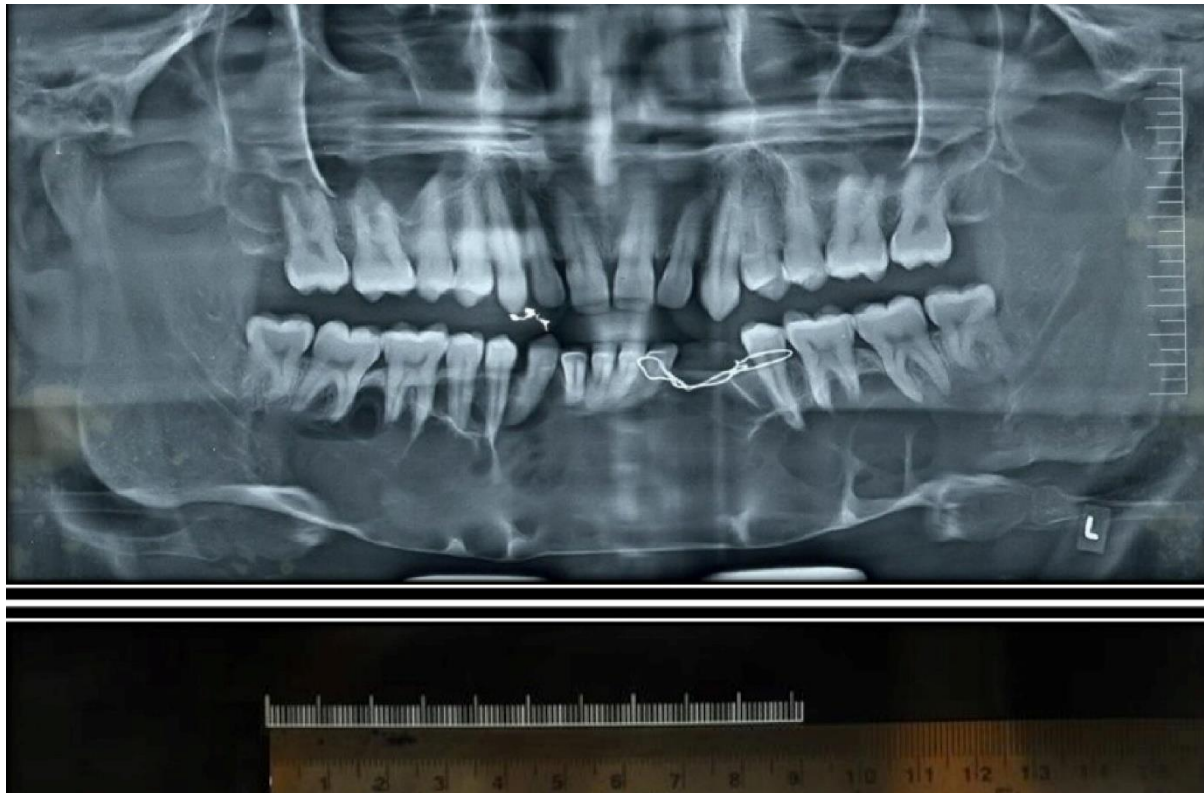Table no. 1: Distribution of nerve paraesthesia between two groups after enucleation

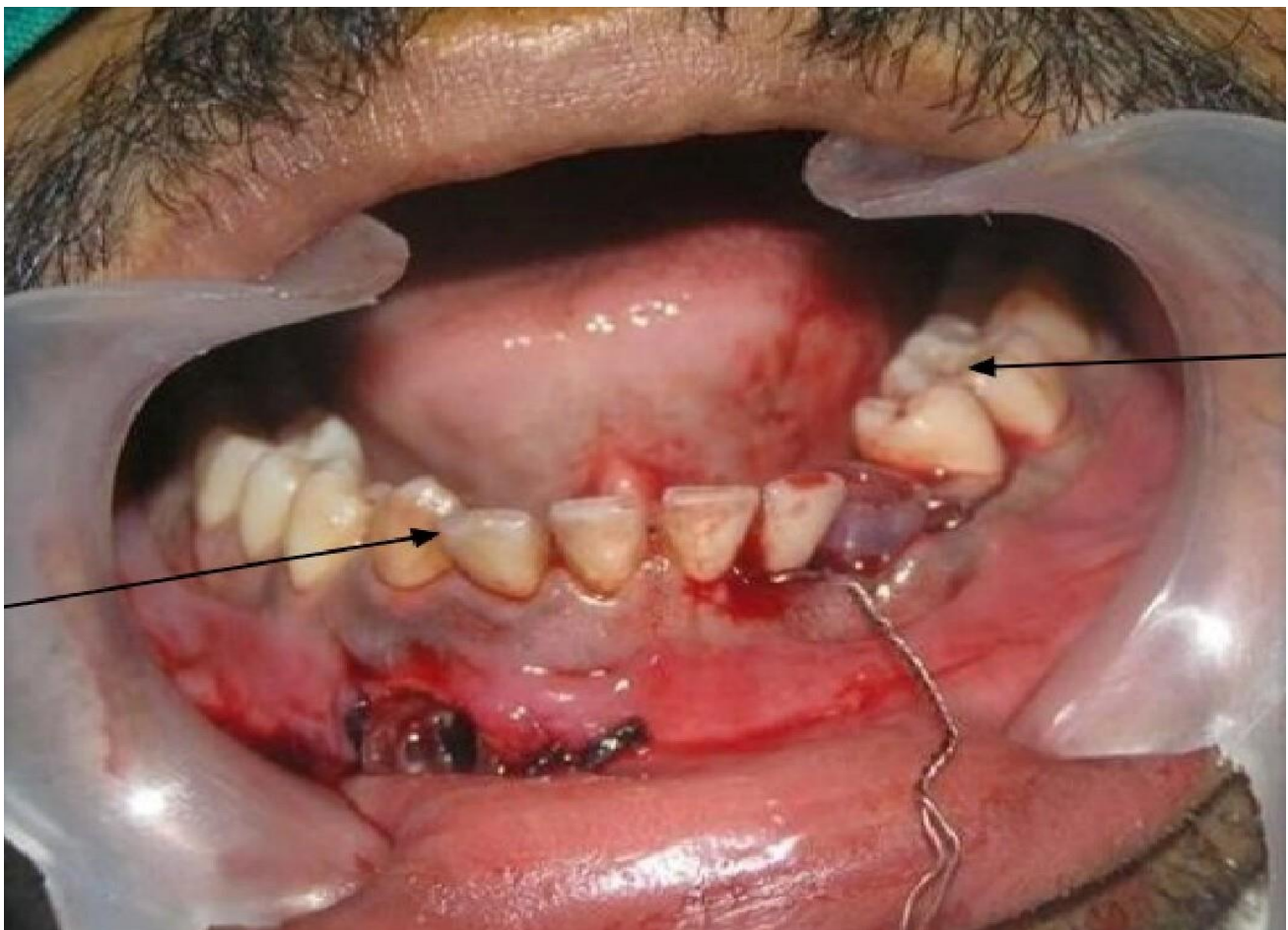
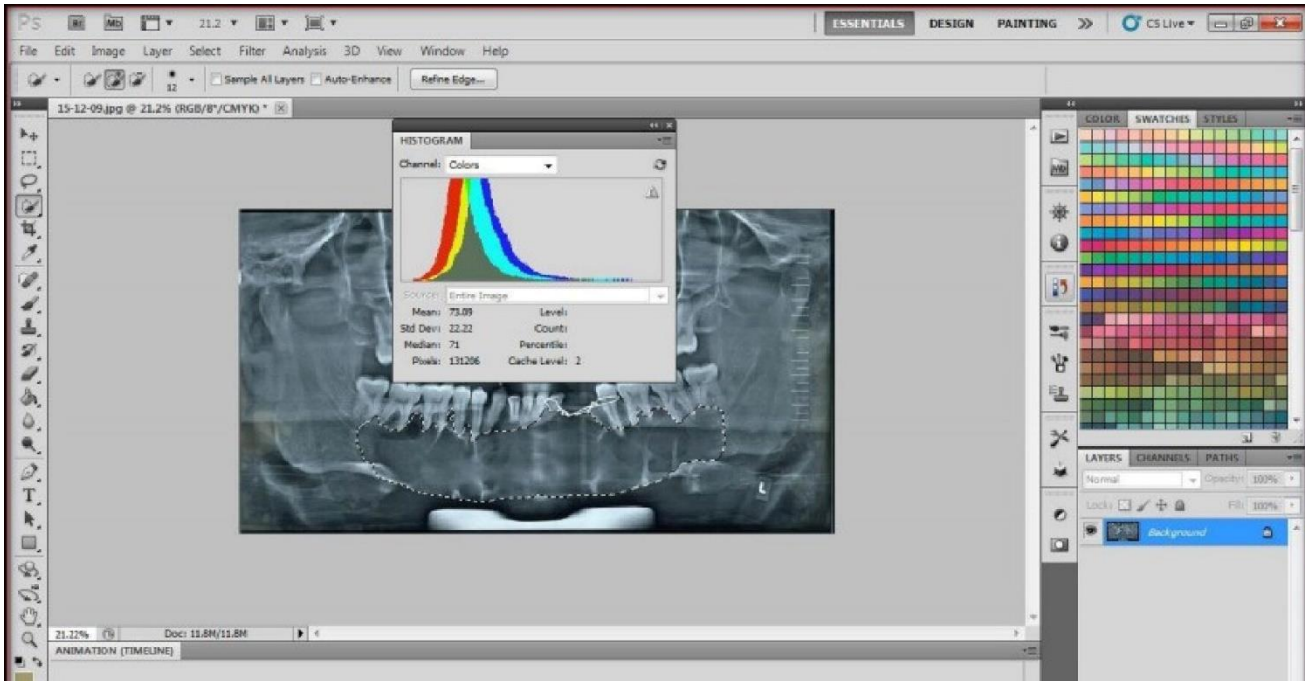
Type of Treatment	Group-1		Group-2	
	N	%	N	%
Extraction	01	10	08	80
Endodontic Treatment	09	90	02	20
Total	10	100	10	100

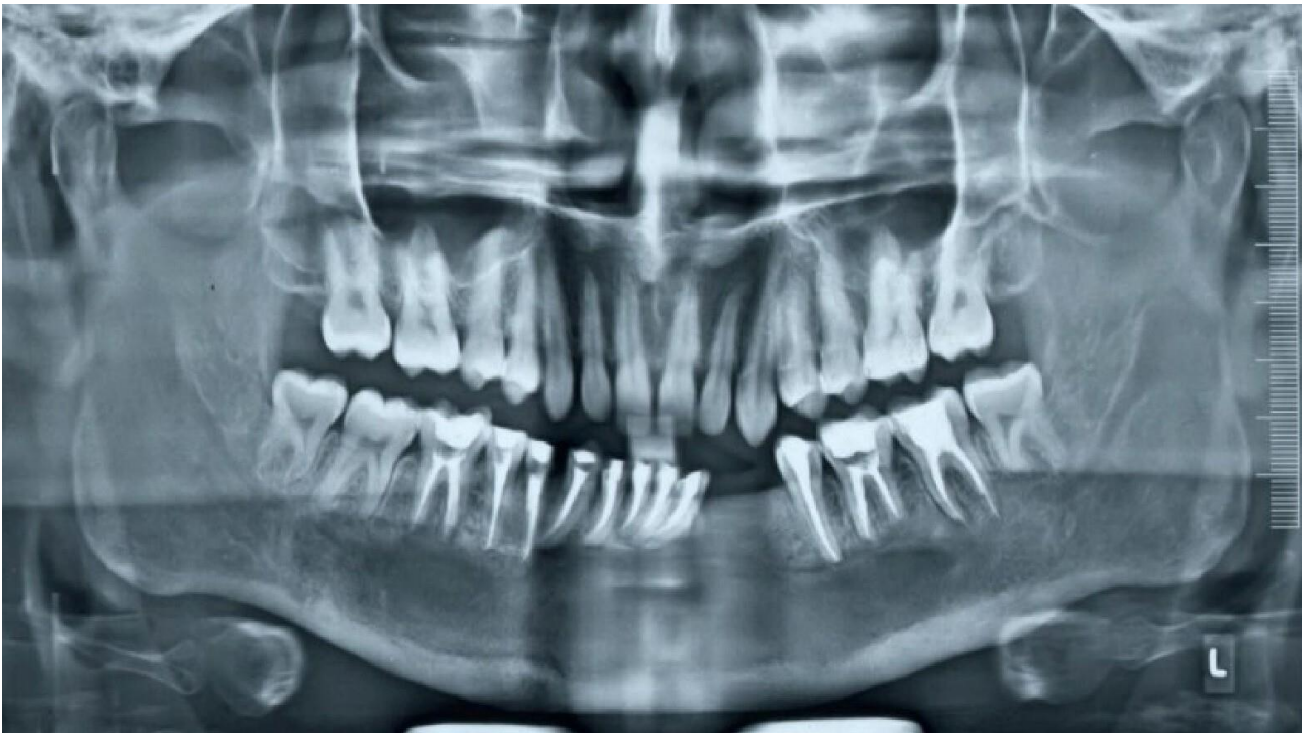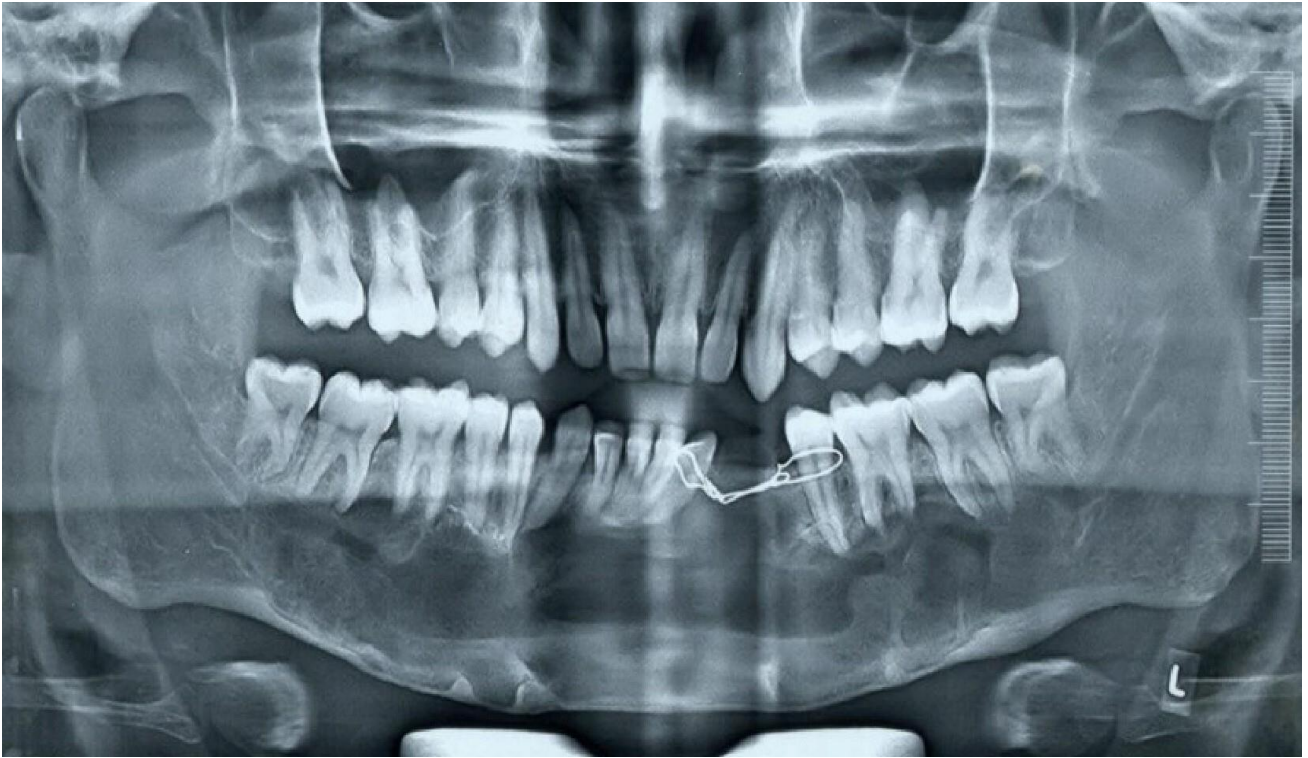
Table no. 2: Distribution Of The 2 Groups Based On The Type Of Treatment Of The Involved Teeth

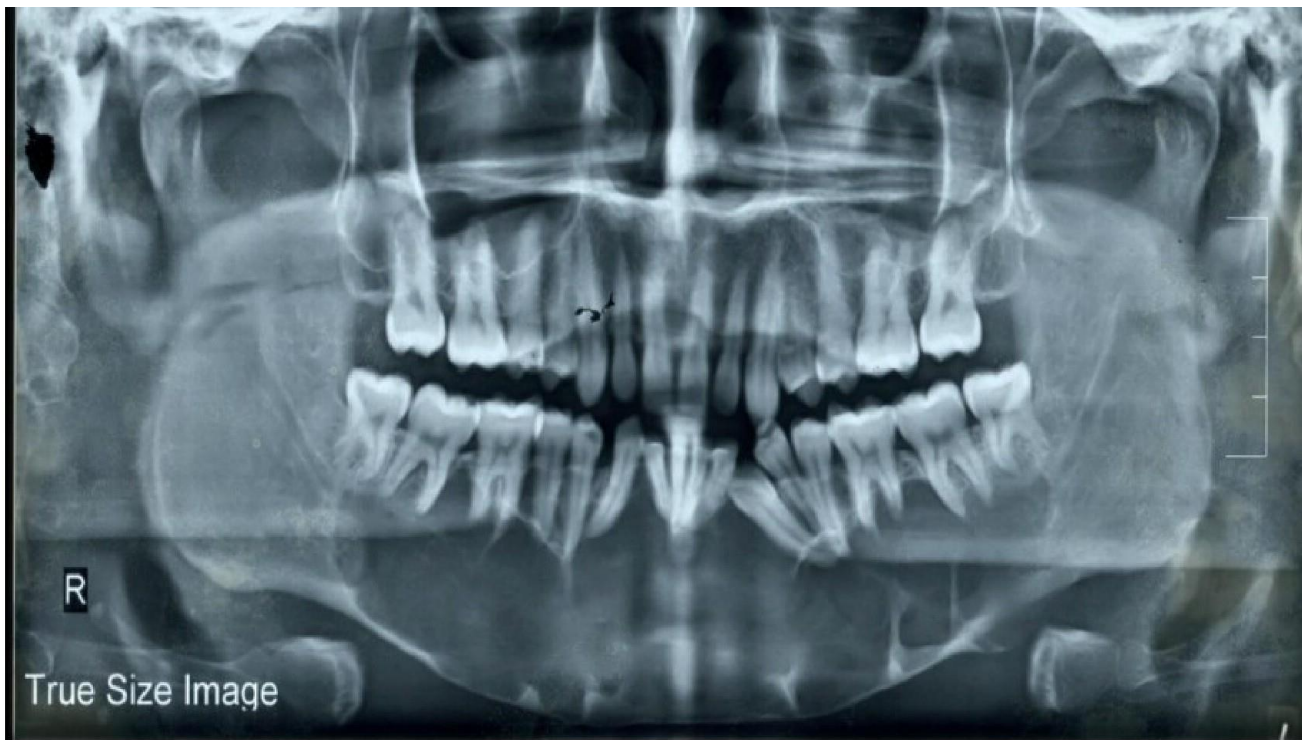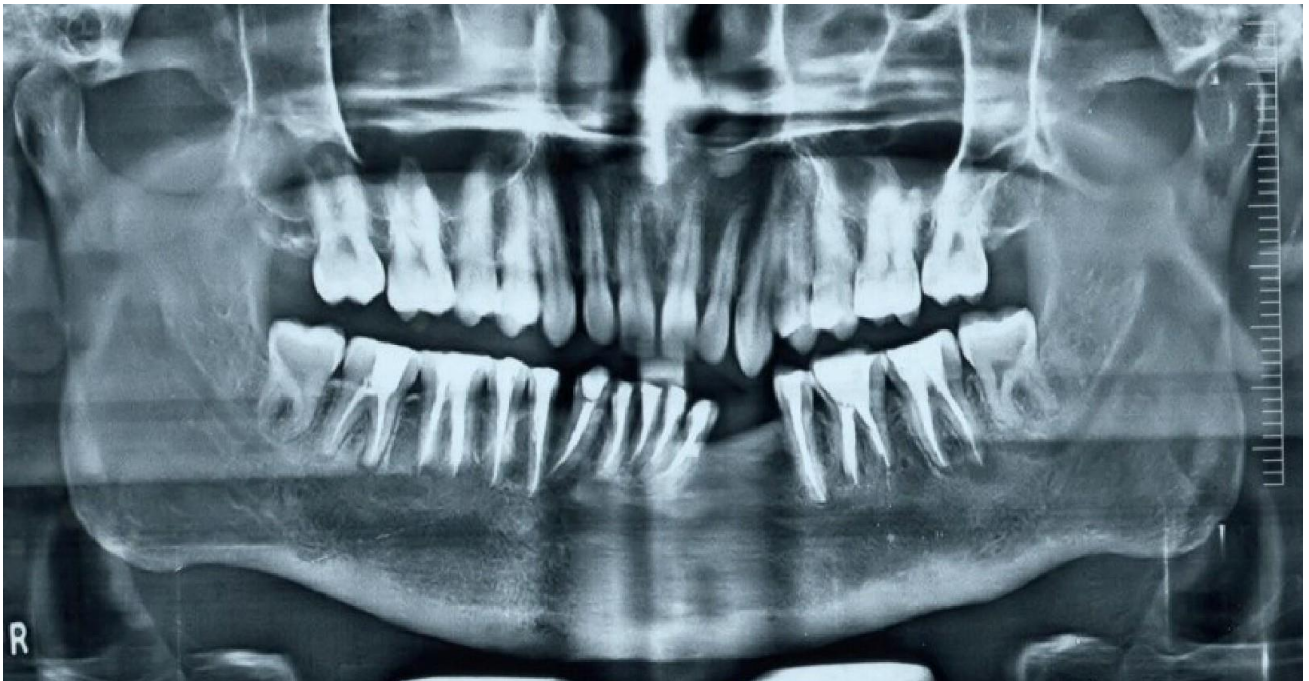Patient No.	Location of OKC	Pre-op dimensions in OPG	Reduction in size of OKC after Marsupialisation		
			3 Months	6 months	9 months
1	Body to body across midline	16 x 3.7cm	14.8 x 3.4 cm	12.6 x 3.2 cm	12.2 x 3 cm
2	Right Angle	11.3 x 5.1cm	10.5 x 4.6 cm	9.7 x 4.45 cm	9.3 x 4.3 cm
3	Left Body	9.6 x 3.2cm	7.4 x 2.3 cm	6.2 x 1.8 cm	6.0 x 1.6 cm
4	Left Ramus	3.8 x 2.6cm	3.6 x 2.5 cm	3.2 x 2.4 cm	2.8 x 2.2 cm
5	Symphysis	7.8 x 3.6cm	7.0 x 3.4 cm	6.6 x 3.3 cm	6.2 x 3.2 cm
6	Left Angle	6.3 x 2.4cm	5.8 x 2.2 cm	5.2 x 2 cm	4.9 x 1.9 cm
7	Right Angle	13.2 x 5.2cm	12.5 x 4.8 cm	11.8 x 4.2 cm	11.1 x 3.9 cm
8	Left Angle	8.6 x 3.2cm	7.8 x 2.9 cm	7.3 x 2.7 cm	7 x 2.5 cm
9	Left Body	10.4 x 2 cm	9.9 x 1.8 cm	9.4 x 1.6 cm	9 x 1.4 cm
10	Left Angle	6.6 x 3.1cm	6.2 x 1.8 cm	5.9 x 1.7 cm	5.5 x 1.6 cm

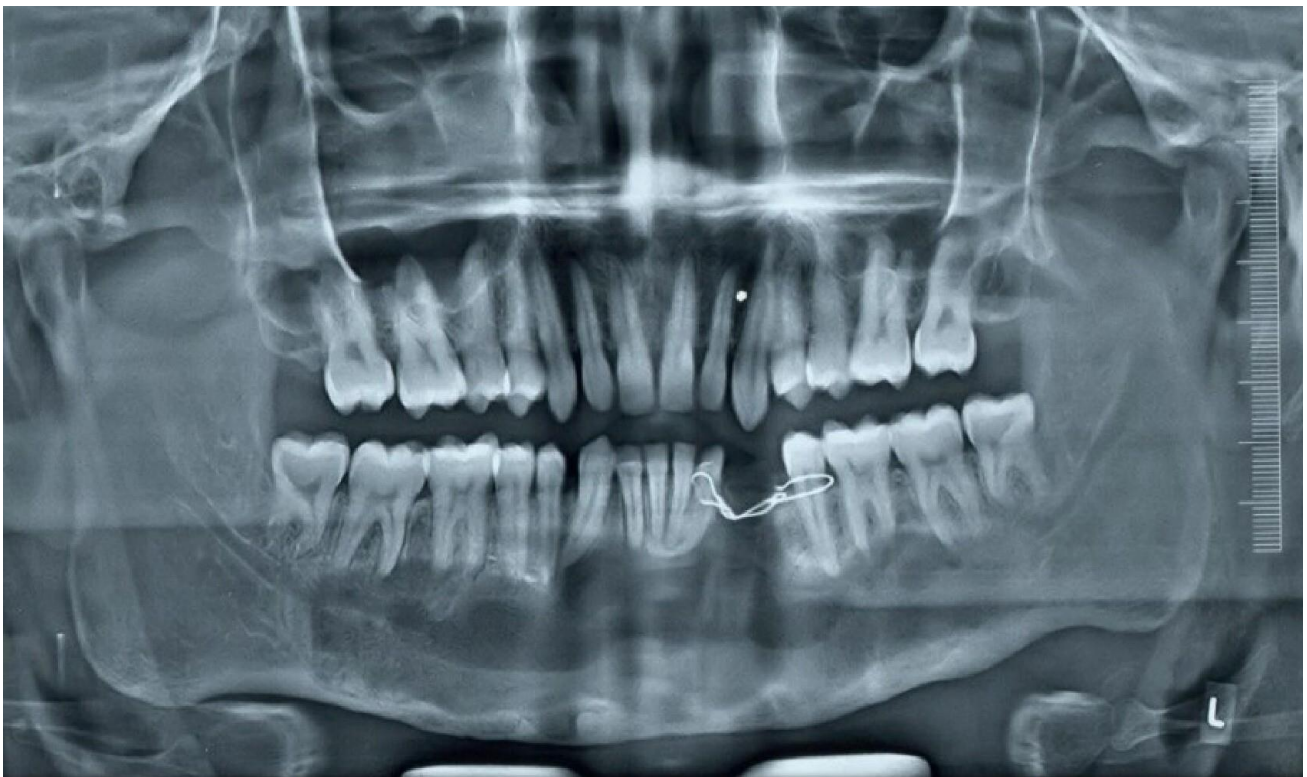
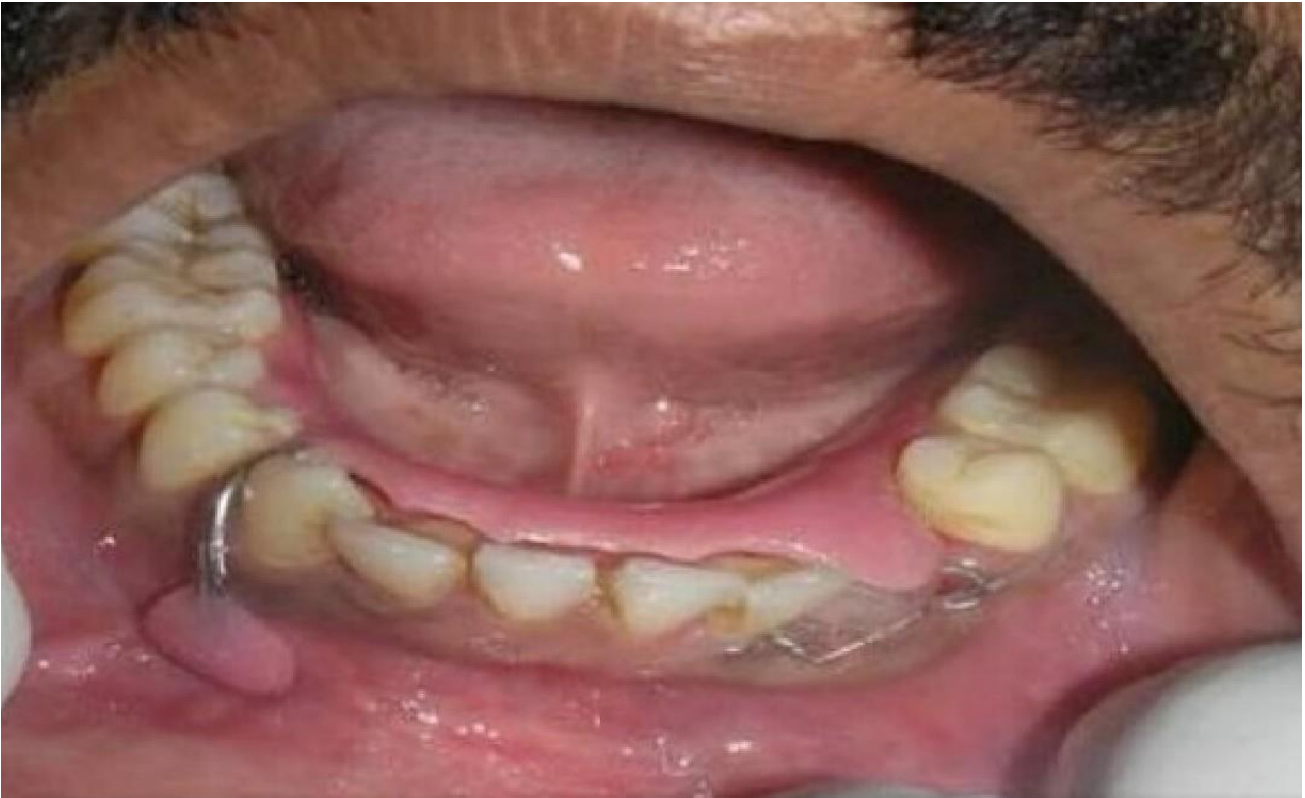Table No. 3: Location of OKC and reduction in size of OKC after marsupilisation at different point of time in group 1.

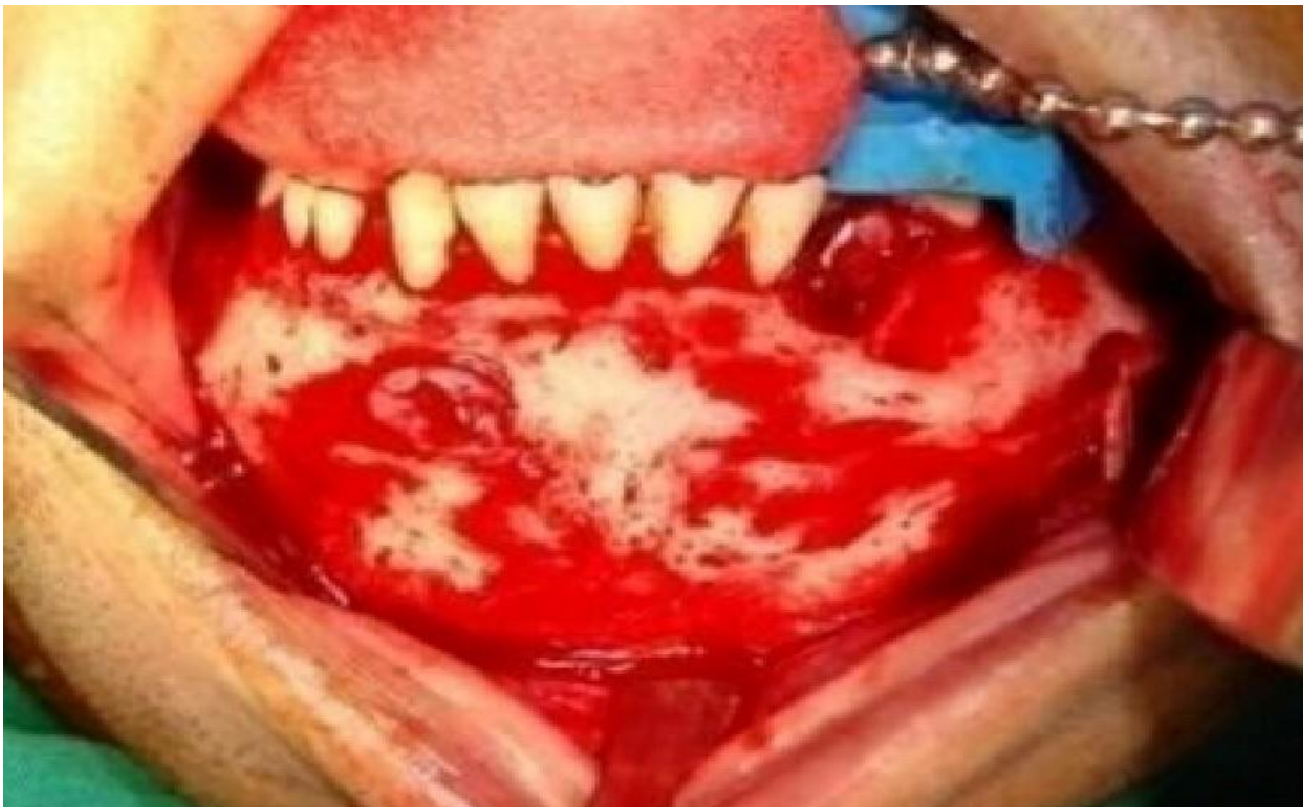
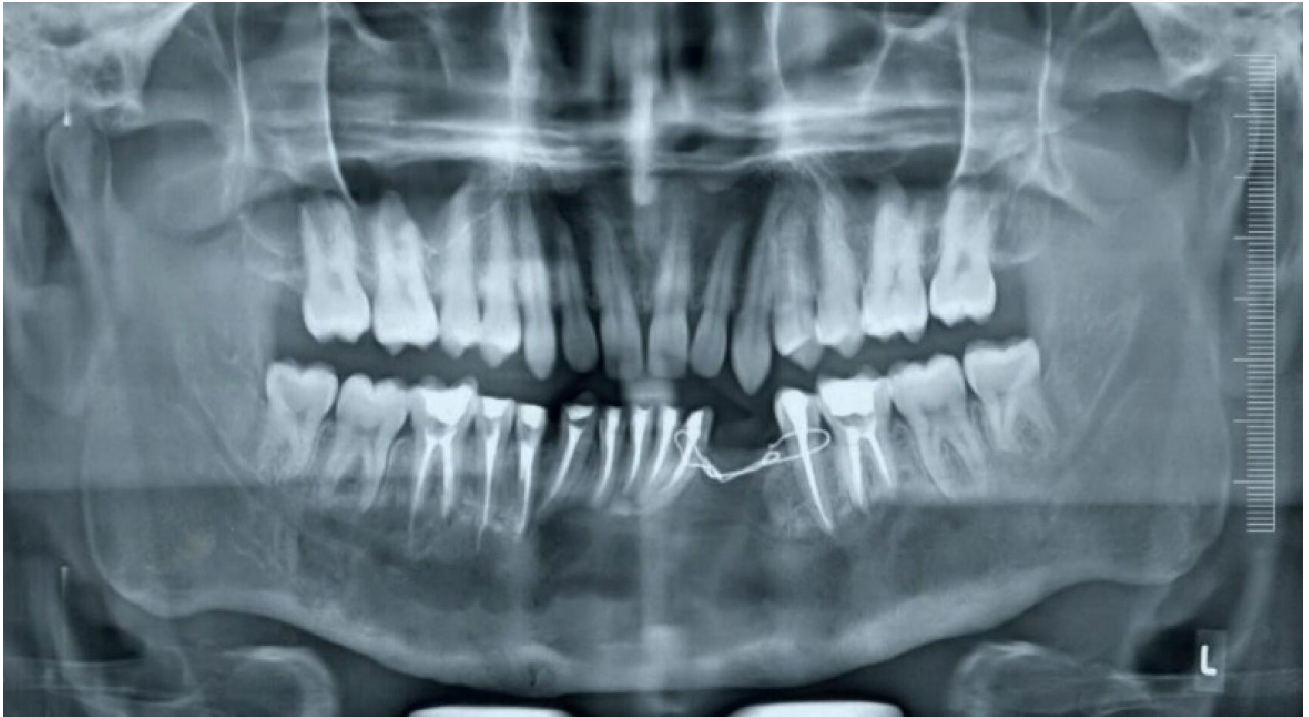

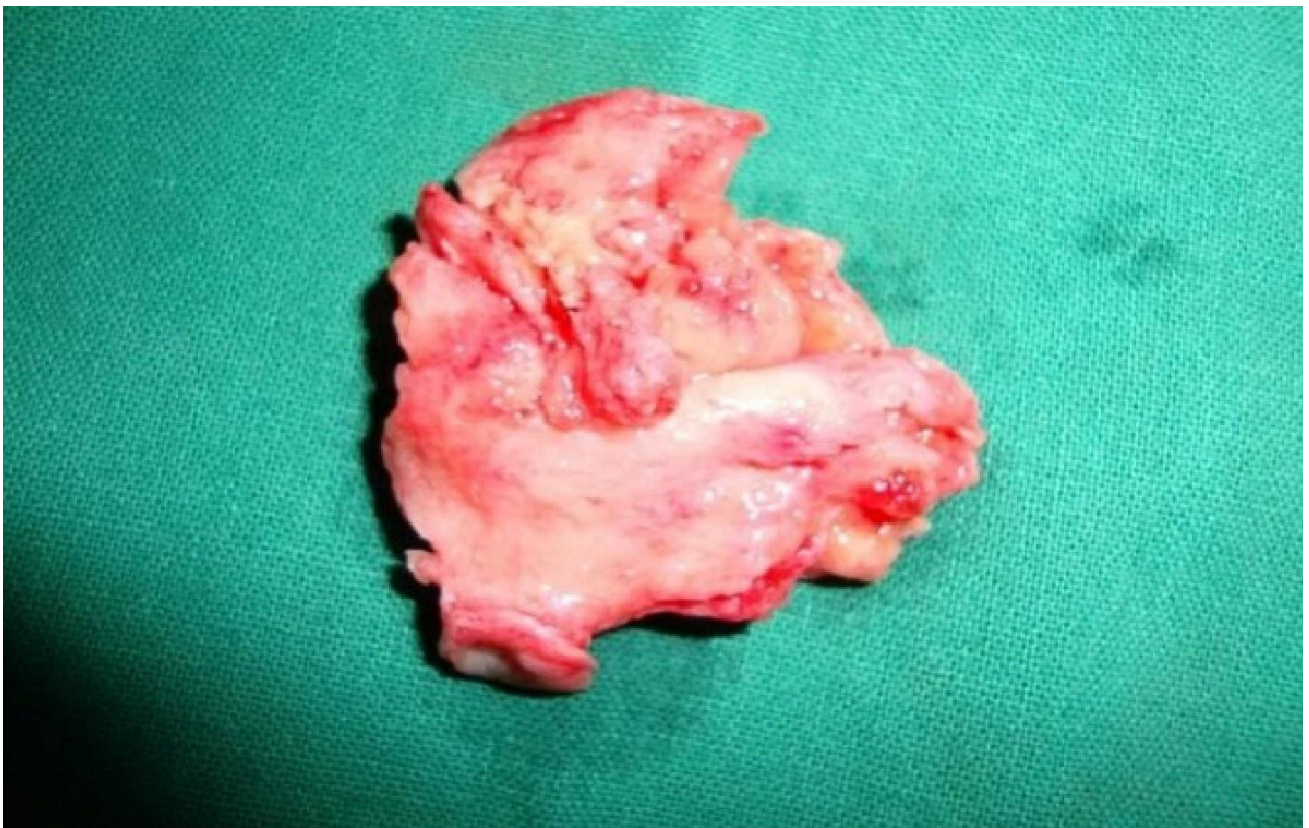

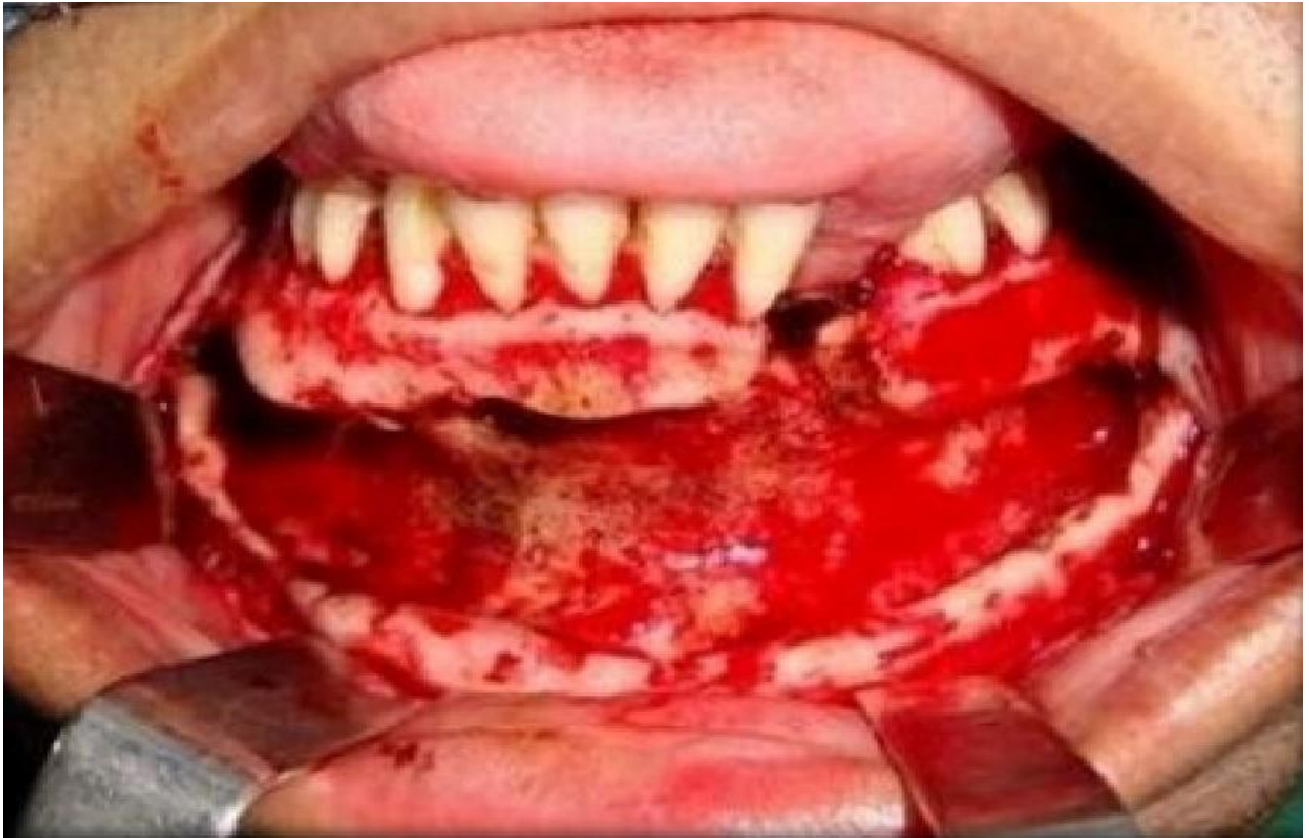
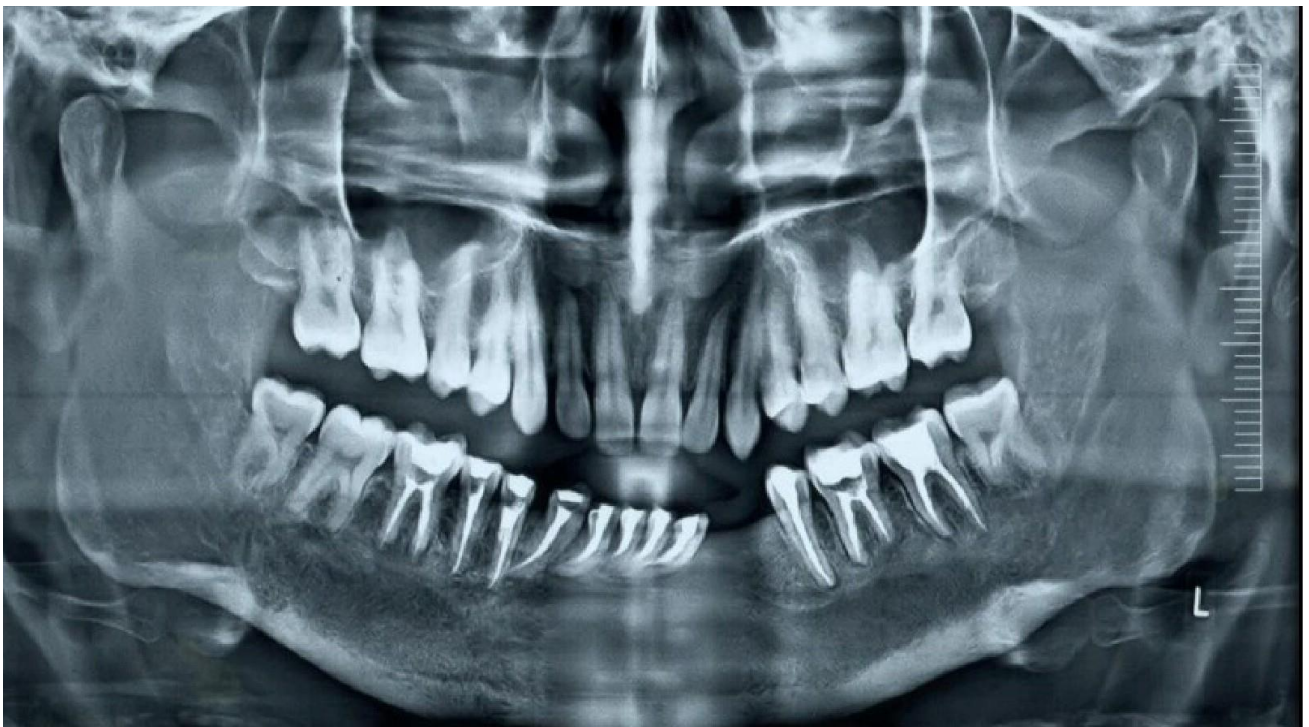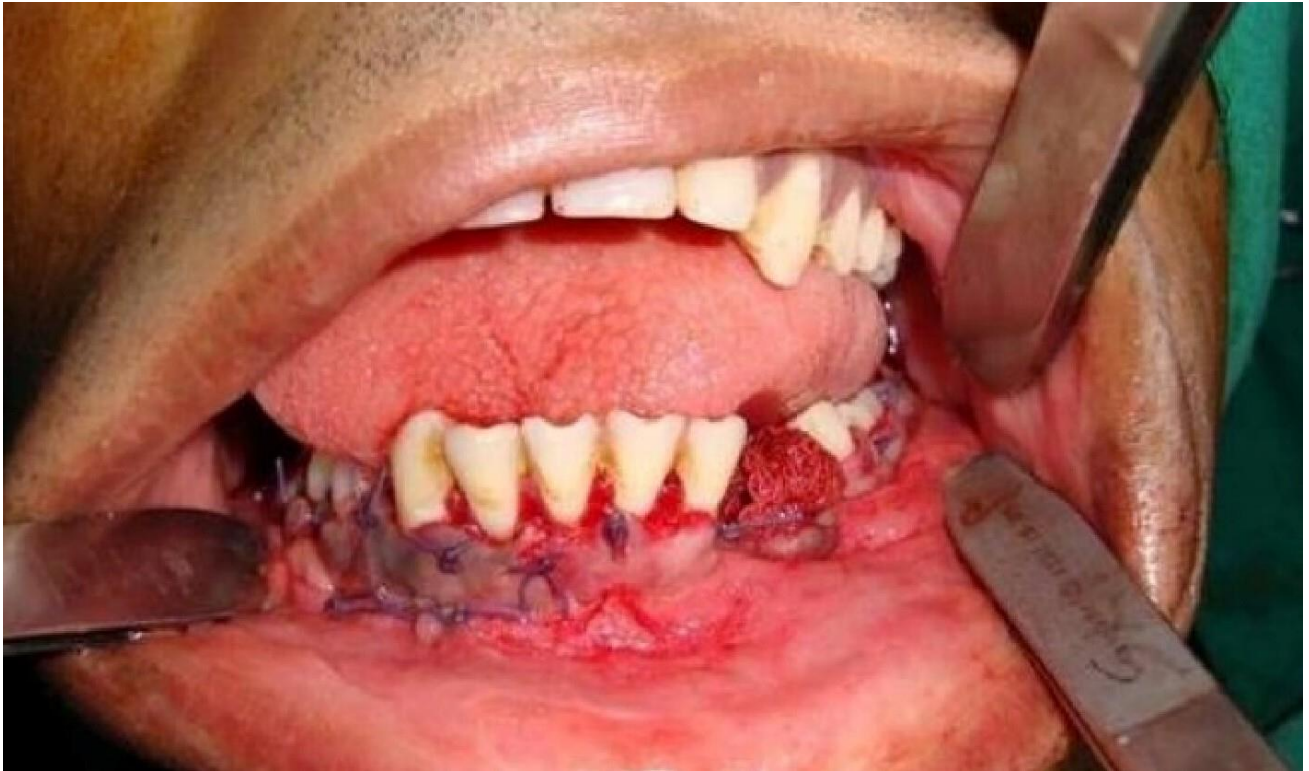





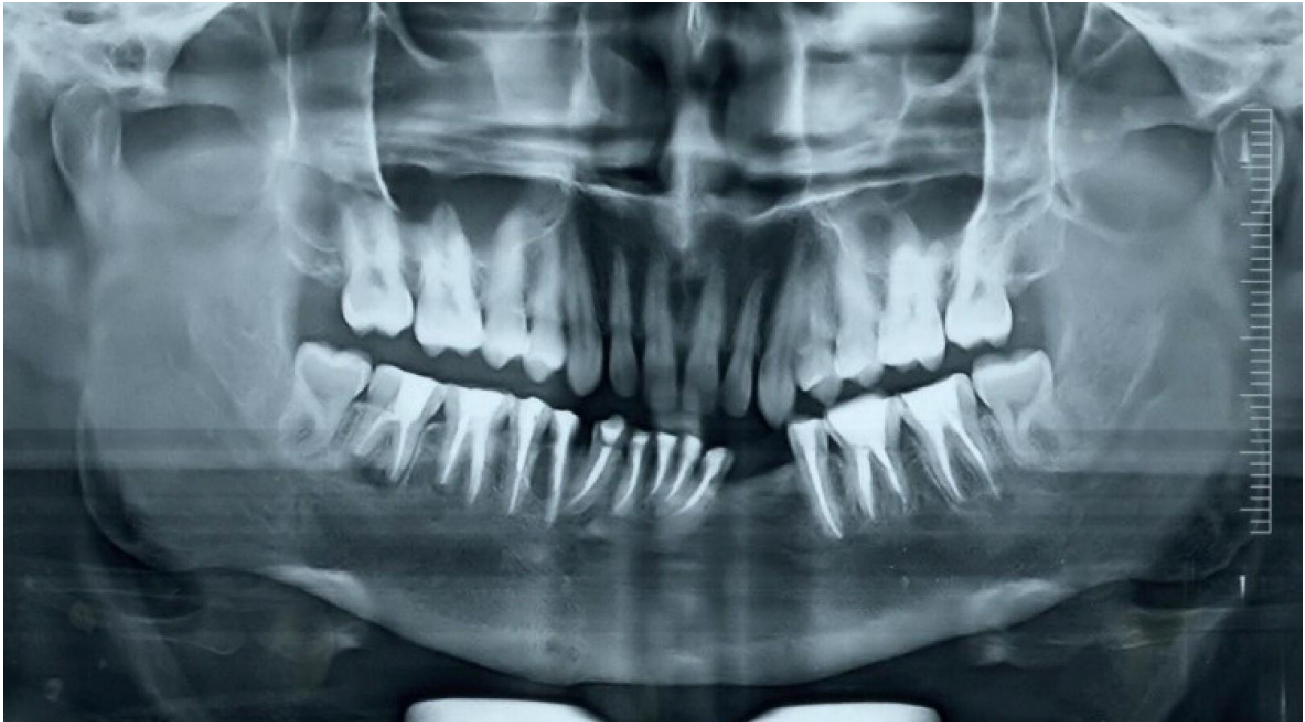








The factors that determine how better OKC will respond to conservative management are discussed as follows

1) Surgical site morbidity and physiologic, functional, and aesthetic rehabilitation.

In neither group was there any significant morbidity. Both groups' physiology, jaw function, and cosmetic appearance were determined to be similar. Although patients in Group 1 required closer monitoring and more frequent sessions for follow-up and maintenance of oral hygiene. Since a conservative technique was sufficient to achieve a satisfying result in terms of aesthetics, function, and physiology, a second donor site wasn't necessary.

In comparison to Group-1, a much higher number of patients in Group-2 underwent extractions. Additionally, Group-1 treated more cases than Group-2 with endodontic therapy. In order to restore function, repair of dental components was therefore more important in group 2 than in group 1.

2) Comparing Pre and postoperative clinical examinations for nerve damage

Even though Group-2 and Group-1 had more incidences of temporary nerve paraesthesia, there was no discernible difference in terms of permanent nerve paraesthesia between the two groups.

However, 2 individuals in group 2 compared to group 1 experienced permanent inferior alveolar nerve paraesthesia, with no cases of permanent paraesthesia. Thus, compared to no decompression procedure, the risk of a lasting nerve injury was significantly lower.

3) Lesion recurrence or the presence of radiolucency at three, six and 12 and 24 months after surgery.

Up to 24-month follow-up period, neither group had any radiolucency or recurrence. However, one patient in group-2 who was not given decompression developed radiolucency. However, we were unable to tell if it was a second primary or recurrence.

Interestingly, throughout a period of 5 years of follow-up, none of the cases required jaw resection at the time of surgery.

Discussion

According to studies using immunohistochemistry and histology, the lining of OKC often changes after decompression therapy, becoming thicker and more ortho-keratinized or resembling normal oral mucosa without the naturally aggressive characteristics of OKC (e.g., inhibition of interleukin-1, loss of cytokeratin-10 production). Decompression followed by cyst enucleation is a safer technique in these situations because it removes the little collapsed cyst, which may behave more benignly (orthokeratinized), with less possibility of damaging the crucial structures [10]. This justifies the practice of marsupializing then enucleating OKC. According to Thomas et al's findings, the pre-decompression diagnosis and post-residual cystectomy were the same in 91% of patients [11]. In our study, in group A, there was no change in the pre-decompression diagnosis and post residual cystectomy in any patients.

Based on Tolstunov's specifications for a decompression device, we changed the needle cover and employed it as a decompression stent. It did have the drawback of not being radiopaque, which is essential when determining the size and position within the bone cavity or when the material has been displaced [12]. In contrast to Kolokythas' description [13], our stent was a little more firm, thus we secured it with 24 gauge wire rather than 28 gauge wire. Due to its rounded edges and the fact that the majority of it was embedded in the cavity, the gadget had been utilised regularly as part of our treatment despite its stiff design.

Earlier only single case reports were published with the protocol of decompression followed by enucleation of cyst, but with advanced techniques and its better outcome, made this protocol widely

accepted. As a result, numerous case series reports appeared in the literature. The majority of the literatures focus on OKC's recurrence after conservative care. If decompression was used as a treatment, Pogrel et al. reported a 10% recurrence rate. However, it has been indicated that the long-term cure rate is higher when it is merely used to reduce the size and is followed by a definitive enucleation treatment [14]. A similar method was used by N. Brondum and colleagues to treat 12 cases, and they observed a low risk of recurrence [15]. The size of cyst was noticeably reduced in the largest trial to date using a similar approach, which was conducted by P. Marker [16]. On radiographic inspection, Rohith Gaikwad saw a mean 53.85% reduction in size whereas YI Zhao observed a 65% reduction in cystic volume [17]. On assessing the rate of shrinkage of OKC's, Kubota et al. discovered that it takes 9 months for it to decrease to half its original size. After 9 months of decompression in our study's group-1, we observed a 45.56 to 72.32% reduction in size, with a mean of 59.04%. After decompression, all patients had a thick lining around the lesion, which was completely eliminated in group-1 following the enucleation of the lesion.

Adjunctive procedures like thermal cauterization, cryosurgery cauterization, chemical cauterization (Carnoy's Solution), and/or peripheral ostectomy are routinely performed after the curettage of OKC. The goal of adjunctive operations is to remove any remaining pathology in the peripheral bone, such as satellite cysts and/or epithelial remains, in order to reduce the likelihood of recurrence. The three adjunctive techniques that are most commonly discussed in the literature are peripheral ostectomy, cryotherapy using liquid nitrogen, and Carnoy's solution [18]. By denaturing proteins and trapping cells, Carnoy's solution attempts to remove epithelial residues from cyst walls that may have remained after enucleation and may be a potential recurrence factor [19]. According to Voorsmit's research, the majority of the remaining cysts and daughter cysts are fixed after 5 minutes of administration, with the mean depth of bone perforation of Carnoy's solution being 1.54 mm [20]. The largest case series of patients treated with this technique was reported by Teresa Morgan et al, who used enucleation together with peripheral ostectomy. On a follow-up period of 1.5 to 9 years, Kolokythas reported no recurrence in patients treated with peripheral ostectomy following enucleation [21]. In a 5-year follow-up, Pogrel reported a recurrence rate of 2.5% while Chow noted a 10% recurrence rate [21]. In our study, there was no recurrence until 5 years after the first diagnosis.

The simplicity and accuracy of this method's solution application are its benefits. Among the drawbacks are irreversible neurotoxicity (if nerve exposure lasts two minutes or more), toxicity to nearby soft tissue, skin, and tooth follicles, irreparable damage to the superficial and devitalized osseous edge, and the impossibility of quick bone transplantation. The length of time that Carnoy's solution is in touch with the neural surface and the axonal degeneration that takes place when treatment

lasts longer than three minutes appear to influence the degree of neuropathy that results. In some instances, 100% of cases showed neuropathy after using Carnoy's solution [22]. However, 11–17.6% of patients who received Carnoy's treatment reported developing neuropathy. It could be explained by the possibility that the nerve, if handled while near the cyst, could sustain harm. In 80% of the cases in our study, we found temporary paresthesia. All of these lesions, though, were in close proximity to the neurovascular bundle. Therefore, it is impossible to determine whether the temporary paresthesia was caused by Carnoy's solution or by genuine injury sustained during handling [22].

Resection is seen to be the most invasive and harmful form of treatment for a benign tumour. However, segmental or marginal osseous excision is likely the most thorough form of treatment recommended for the management of OKCs. En bloc resection is the only treatment option consistently cited in case series with a zero recurrence rate, despite the fact that some people think it's radical treatment for a benign cyst. En bloc osseous resection should be viewed as including two separate surgical techniques: a segmental resection and a marginal resection that retains continuity [18]. According to Bataineh and Al Qudah's series of 31 cases treated by marginal resection with a 1 cm safe margin and tracked for 2 to 8 years, there were no recurrences [23]. Mild transitory inferior alveolar nerve paresthesia was the only significant side effect after the resections [18].

Resection as a treatment modality is considered the most extensive and morbid treatment for a benign tumour. Though perhaps the most extensive form of treatment indicated for the management of OKCs is that of marginal or segmental osseous resection. Although some individuals consider this treatment to be radical for a benign cyst, en bloc resection is the only treatment modality consistently cited in case series with a zero recurrence rate. En bloc osseous resection should be considered as two distinct surgical approaches: a marginal resection or rim ostectomy that preserves continuity and a segmental resection [18]. Bataineh and Al Qudah reported their series of 31 cases treated by marginal resection with a 1 cm safe margin, followed from 2-8 years and noted zero recurrence [23]. The only major complication from the resections was mild transient inferior alveolar nerve paresthesia [18].

A segmental resection, which violates the continuity of the mandible, is the most extensive treatment. The need for complex reconstruction, with subsequent bone grafting, loss of inferior alveolar nerve function, and cosmetic deformity are potential sequels inherent to segmental resections. Thus there are few absolute indications like recurrent/extensive lesions, involvement of the condyle, a pathologic fracture caused by an untreated cyst, or ameloblastomatous or carcinomatous degeneration within an OKC for this type of resection. Several case reports have documented cyst extension into the orbit, base of skull, and intracranial region. In most cases, the patients were initially treated with conservative

means. Jackson et al, in their report of two OKCs with intracranial extension from a mandibular source, stated that “en bloc resection of the specimen with a layer of surrounding normal tissue may seem ‘radical’ but it ensures total removal” [24].

Traditional OKC management has held the belief that a 5-year follow-up period was adequate to discover most recurrences. Other researchers believe that a 10-year follow-up period is more appropriate because of the large number of first recurrences after 5 years [16]. It was seen that conservative approach was more acceptable in majority of the cases. If this fails (and especially in cases of multiple recurrence), then en bloc resection seems to be the most effective surgical approach, resulting in little or no recurrence. Browne reported a 25% recurrence rate on follow up of 6 months or longer and he reported that most recurrences usually occur in the first five years, although they might take place even later 5. In our study we followed cases up 5 years, with no recurrence in either groups. Thus we oppose the resection of jaw for meager percentage of recurrence of OKC if judiciously treated by marsupialisation and followed by enucleation. Treating all cases of OKC by resection for having zero recurrence rate is not scientifically justifiable.

Conclusion

The aim of our study was to evaluate the efficacy of decompression and enucleation with other adjunct procedures. Phenomenal bone deposition and reduction in size of the lesion was noted. The vital structures were preserved and the morbidity was low as compared to aggressive surgical management. We can conclude that the protocol of decompression followed by enucleation with peripheral ostectomy and Carnoy’s solution has promising results for large OKC’s. Resection of jaw should be preserved to only recurrent cases of OKC’s. Enucleation and peripheral ostectomy followed by carnoys solution application gives better outcome of management of OKC equally effective to that of enbloc resection.

References

- 1) Reichart PA, Philipsen HP. Odontogenic tumors and allied lesions. London, UK: Quintessence Publishing, 2004; 332 - 41
- 2) Shear M and Speight PM (eds): Cysts of the oral and maxillofacial regions. 4th edition. Oxford, Blackwell Munksgaard 2007

- 3) Marker P, Brøndum N, Clausen PP, Bastian HL. Treatment of large odontogenic keratocysts by decompression and later cystectomy: a long-term follow-up and a histologic study of 23 cases. *Oral Surg Oral Med Oral Pathol Oral Radiol Endod.* 1996 Aug;82(2):122-31
- 4) Kramer IR, Pindborg JJ, Shear M. The World Health Organization histological typing of odontogenic tumours. Introducing the second edition. *Eur J Cancer B Oral Oncol.* 1993 Jul;29B(3):169-71.
- 5) Maurette PE, Jorge J, Moraes M. Conservative Treatment Protocol of Odontogenic Keratocyst: A Preliminary Study. *Journal of Oral and Maxillofacial Surgery.* 2006; 64:379-383.
- 6) Pogrel MA, Schmidt BL. The odontogenic keratocyst. *Oral and maxillofacial surgery clinics of North America.* 2003 Aug;15(3). [https://doi.org/10.1016/S1042-3699\(03\)00040-2](https://doi.org/10.1016/S1042-3699(03)00040-2)
- 7) Shear M. The aggressive nature of the odontogenic keratocyst: is it a benign cystic neoplasm? Part 1. Clinical and early experimental evidence of aggressive behaviour. *Oral Oncol.* 2002 Apr;38(3):219-26.
- 8) Irvine GH, Bowerman JE. Mandibular keratocysts: surgical management. *Br J Oral Maxillofac Surg.* 1985 Jun;23(3):204-9.
- 9) Oikarinen VJ. Keratocyst recurrences at intervals of more than 10 years: case reports. *Br J Oral Maxillofac Surg.* 1990 Feb;28(1):47-9.
- 10) Kaczmarzyk T, Mojsa I, Stypulkowska J. A systematic review of the recurrence rate for keratocystic odontogenic tumour in relation to treatment modalities. *Int J Oral Maxillofac Surg.* 2012 Jun;41(6):756-67.
- 11) Gao L, Wang XL, Li SM, Liu CY, Chen C, Li JW, Yan XJ, Zhang J, Ren WH, Zhi KQ. Decompression as a treatment for odontogenic cystic lesions of the jaw. *J Oral Maxillofac Surg.* 2014 Feb;72(2):327-33.
- 12) Wushou A, Zhao YJ, Shao ZM. Marsupialization is the optimal treatment approach for keratocystic odontogenic tumour. *J Craniomaxillofac Surg.* 2014 Oct;42(7):1540-4.
- 13) Ribeiro Junior O, Borba AM, Alves CA, de Gouveia MM, Coracin FL, Guimarães Júnior J. Keratocystic odontogenic tumors and Carnoy's solution: results and complications assessment. *Oral Dis.* 2012 Sep;18(6):548-57.

- 14) Kubota Y, Imajo I, Itonaga R, Takenoshita Y. Effects of the patient's age and the size of the primary lesion on the speed of shrinkage after marsupialisation of keratocystic odontogenic tumours, dentigerous cysts, and radicular cysts. *Br J Oral Maxillofac Surg.* 2013 Jun;51(4):358-62.
- 15) Brøndum N, Jensen VJ. Recurrence of keratocysts and decompression treatment. A long-term follow-up of forty-four cases. *Oral Surg Oral Med Oral Pathol.* 1991 Sep;72(3):265-9.
- 16) Stoelinga PJW. The treatment of odontogenickeratocysts by excision of the overlying mucosa, enucleation, and treatment of bony defect with carnoy solution. *J Oral Maxillofac Surg.* 2005; 63: 1667 – 1673
- 17) Saulacic N, Stajcic Z, Stojcev Stajcic Lj, Piattelli A, Iizuka T, Lombardi T. Effects of Carnoy's solution on blood vessels of the axillary fossa of rats. *Int J Oral Maxillofac Surg.* 2009 Aug;38(8):876-9.
- 18) Gaikwad R, Kumaraswamy SV, Keerthi R. Decompression and cystectomy of the odontogenic keratocysts of the mandible: a clinical study. *J Maxillofac Oral Surg.* 2009 Mar;8(1):47-51.
- 19) Zecha JA, Mendes RA, Lindeboom VB, van der Waal I. Recurrence rate of keratocystic odontogenic tumor after conservative surgical treatment without adjunctive therapies - A 35-year single institution experience. *Oral Oncol.* 2010 Oct;46(10):740-2.
- 20) Chirapathomsakul D, Sastravaha P, Jansisyanont P. A review of odontogenic keratocysts and the behavior of recurrences. *Oral Surg Oral Med Oral Pathol Oral Radiol Endod.* 2006 Jan;101(1):5-9;
- 21) Giuliani M, Grossi GB, Lajolo C, Bisceglia M, Herb KE. Conservative management of a large odontogenic keratocyst: report of a case and review of the literature. *J Oral Maxillofac Surg.* 2006 Feb;64(2):308-16.
- 22) Ozkan A, Bayar GR, Altug HA, Sencimen M, Senel B. Management of keratocystic odontogenic tumour with marsupialisation, enucleation and Carnoy's solution application: a case report. *Oral Health Dent Manag.* 2012 Jun;11(2):69-73.
- 23) Dammer R, Niederdellmann H, Dammer P, Nuebler-Moritz M. Conservative or radical treatment of keratocysts: a retrospective review. *Br J Oral Maxillofac Surg.* 1997 Feb;35(1):46-8.
- 24) Madras J, Lapointe H. Keratocystic odontogenic tumour: reclassification of the odontogenic keratocyst from cyst to tumour. *J Can Dent Assoc.* 2008 Mar;74(2):165-165.