



## **Therapeutic Approach and the Management of Early Postoperative Recovery for A Forearm Replantation Following Major Trauma**

Carstea A I<sup>2,5</sup>, Sebe I T<sup>1,2,3</sup>, Dragu E R<sup>1,2,3</sup>, Lascăr I<sup>1,2,3,4</sup>, Chioaru B L<sup>1,2,3\*</sup>

1. *The University of Medicine and Pharmacy "Carol Davila", Bucharest, Romania*

2. *The Emergency Clinical Hospital Bucharest, Romania-Department of Plastic, Aesthetic and Reconstructive Microsurgery.*

3 *MD, PhD*

4 *FRCS, FICS, Prof. Dr. Emeritus*

5 *PhD Student*

**\*Correspondence to:** Chioaru Bogdan Liviu, PhD Student, The University of Medicine and Pharmacy "Carol Davila", Bucharest, Romania, The Emergency Clinical Hospital Bucharest, Romania-Department of Plastic, Aesthetic and Reconstructive Microsurgery.

### **Copyright**

© 2023: **Chioaru Bogdan Liviu**. This is an open access article distributed under the Creative Commons Attribution License, which permits unrestricted use, distribution, and reproduction in any medium, provided the original work is properly cited.

Received: 09 September 2023

Published: 01 October 2023

## **Abstract**

*Limb amputation is a devastating injury, quite common in some areas, with a large variety of effects. Apart from the perspective of losing his job, the patient faces important consequences from social, psychological and aesthetic points of view. Therefore, despite the significant improvement of functional prosthesis, replantation of an amputated limb should be always the first thing to consider and thoroughly evaluation should be prioritised.*

*In this paper we are discussing the case of a middle age man with a traumatic mid-forearm amputation, through an avulsion and twisting mechanism, for which, after MDT discussion and with the patient's consent it is decided to go for forearm replantation. We present the surgical details of this case that was operated on by a multidisciplinary team. We analyse the favourable outcome of this case and also the literature regarding the operative technique, indications and contraindications, and we emphasize on the long term outcome using an early personalised physiotherapy treatment. The follow up for this case was 2 years.*

## **Introduction**

Forearm amputation is a major trauma that decreases dramatically the patients' quality of life and socio-economical and familial reintegration. 20-30000 cases are reported worldwide annually. Replantation is the process through which we reattach a body segment that was amputated by trauma, in an attempt to achieve neurovascular, musculoskeletal and skin integrity with good function and acceptable cosmetic outcome. On the 7th of Sept 1964 the 1st replantation of a completely detached hand was achieved using the vascular anastomosis techniques. Shortly after, in 1968, the 1<sup>st</sup> successful finger replantation was done by microvascular anastomosis by Komatsy & Co.

The mechanism of the injury is crucial in the result of the replantation: clear cut injuries have a much better outcome than crush injuries. The decision to replant a limb should be objective, following the assessment of the tissue viability, the state of the vessels and nerves, the bones and joints integrity and the potential for recovery. These cases are assessed and operated by a multidisciplinary team (plastic and orthopaedic surgeons, anaesthetist and physiotherapist). We demonstrate that early personalised mobilisation and physiotherapy are the key to a good functional recovery.

In this paper we are describing the case of a 50 years old man, right handed, with a circular saw injury. He is admitted to the hospital with the diagnosis of subtotal amputation of right mid forearm with open fracture III C to both radius and ulna. The wound is heavily contaminated. On examination, the ulnar artery, vein and nerve and median nerve were injured (100% divided). The radial artery was in continuity but thrombosed over an area of 5 cm. The amputated segment was only attached through a 4x5 cm area of skin overlying the thrombosed radial artery and the thumb's FDP and FDS. FDPs and FDSs to digits 2-5, FCU, FCR, PL as well as all the extensors and the radial nerve were 100% divided by the injury.

This case was carefully considered for replantation due to the severity of the injury.

After having the pre-anaesthetic review and signing the informed consent, the patient was taken to theatre.

The complexity of the injury and the fact that the wounds were heavily contaminated led to serial surgical procedures. Despite the relative contraindication of replantation in this case due to mechanism of the injury, the surgical team together with the patient decided to go ahead with the procedure, understanding the risks of a long surgical procedure, including infections, thrombosis, reperfusion injury, further surgery, failure of the replantation with subsequent surgical terminalisation, long recovery, DVT, PE.

The surgical approach and early mobilisation led to a satisfactory outcome allowing the patient to return to work and an uneventful social integration.

## **Method and Material**

Male patient, 50 years old, attends the A&E following a DIY accident, e.g. injury by circular saw to right forearm. On arrival the patient is stable, slightly pale, BP 90/60 mmHg, PR 96 and states that the injury happened 4 hours before.

He is admitted with the diagnosis of subtotal amputation of right mid forearm with open fracture III C to both radius and ulna, with the ulnar artery, vein and nerve and median nerve injured (100% divided). The radial artery was in continuity but thrombosed over an area of 5 cm. The amputated segment was only attached through a 4x5 cm area of skin overlying the thrombosed radial artery and the thumb's FDP and FDS. FDPs and FDSs to digits 2-5, FCU, FCR, PL as well as all the extensors and the radial nerve were 100% divided by the injury.

The skin bridge connecting the stump to the amputated segment is disrupted by a wound of 3x4 cm. The stump edge is heavily contaminated with soil and metallic dust. The distal segment is cold, pale and also contaminated. There is no capillary refill to the fingers and no pulse detected on the pulse oximeter. The nerves and tendons are also stretched and twisted.

Currently, the protocol says that for small skin bridges with levelled injuries, the skin bridge is sacrificed to allow the amputated fragment to be preserved at 4 degrees Celsius, in wet swabs, in a plastic bag immersed in water with ice to limit the warm ischemia time. In this particular case, this could not be done due to the radial artery that was in continuity although it was thrombosed, twisted and not patent.

The patient has x-rays, routine bloods check including group and save. He is started on IV Antibiotics (Cefuroxime and Metronidazole).

He was taken to theatre where, under GA and regional block he had washout with 3L normal saline, debridement, exploration, minimal shortage of radius and ulna from the distal fragments. Radius and ulna were reduced in a good position with external fixator for the radius and K-wires for ulna.

The ulnar artery was identified proximally and distally and microsurgical anastomosis was performed. The radial artery had the thrombosed segment removed followed by re-anastomosis. 2 veins were repaired for every artery. We repaired his median and ulnar nerves and his injured flexors. Skin was closed with removable sutures.

Post-surgery, as an inpatient, he is prescribed Cefuroxim (BD, 10/7), Metronidazol(TDS, 3/7), NSAIDS (BD,5/7), Omez(OD, 5/7), Eubiotic (10/7 + 2/52 TTO), Anticoagulant (Fragmine 10.000 UI OD -10/7), Aspenter(10/7), Pentoxifilin(10/7).

The patient recovered well and quickly after the surgical procedure, he had a decrease in his inflammatory markers, normal colour of his skin at the level of the replanted segment, good capillary refill, good Doppler signal for the repaired ulnar and radial arteries. The median nerve had positive Tinel sign at 48 h post-surgery at the level of the repair. He was monitored as per protocol one hourly for the first 6 hours, two hourly for the following 6 hours and the 4 hourly for another 48 hours. The monitoring was done by visual exam/capillary refill, temperature check, handheld Doppler signal over an area marked to the skin overlying the pedicles. He was also monitored clinically and by paraclinic means. The leg was kept warm to avoid vasoconstriction. He was an inpatient for 10/7

---

The hand therapy was started 48 h post-surgery with passive mobilisation of all fingers.

Upon discharged he was prescribed Fragmine 5000IU OD and Aspenter 1tb OD for 1/12. The sutures were removed at 2/52.

One month later he is readmitted to hospital for the second surgical procedure. The k-wire and the external fixator were exchanged for plates and screws and the extensor mechanism was repaired to give the hand the normal cascade. POP immobilisation was done with the elbow at 90 degrees and the hand in resting position. The patient recovered well and was discharged 9 days later.

Due to the operative technique and the early start of hand therapy, common late complications have been prevented (Volkman Sdr, adhesions, stiffness, neuromas, keloid/hypertrophic scars ,etc).

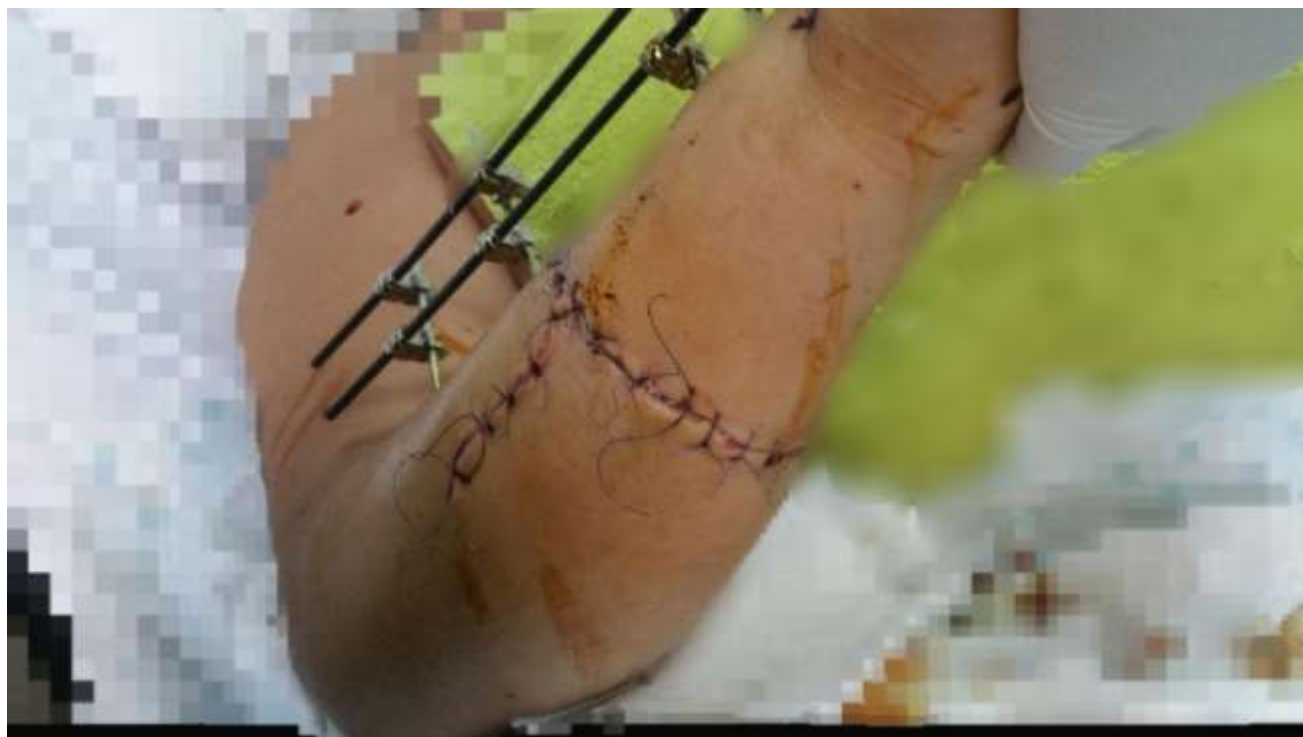After the second surgical procedure, the hand therapy was also started at 48h post op with passive mobilisation of all fingers, on day 7 he was started with light, passive mobilisation of the wrist and active mobilisation of his fingers for the next 2/52. The cast was removed in 3/52 and he has full physiotherapy including ultrasound and electrostimulation for the next 6/52. After 6/52 he carried on with hand therapy at home and follow ups with the hand therapist, plastic surgeons and orthopaedic team. He was seen at 48h, 7/7, 14/ 7, 1/12, 3/12, 6/12, 12/12 and 2 years.

To his every visit, we recorded the findings of his clinical examination, x-rays, Doppler, ultrasound and EMG.

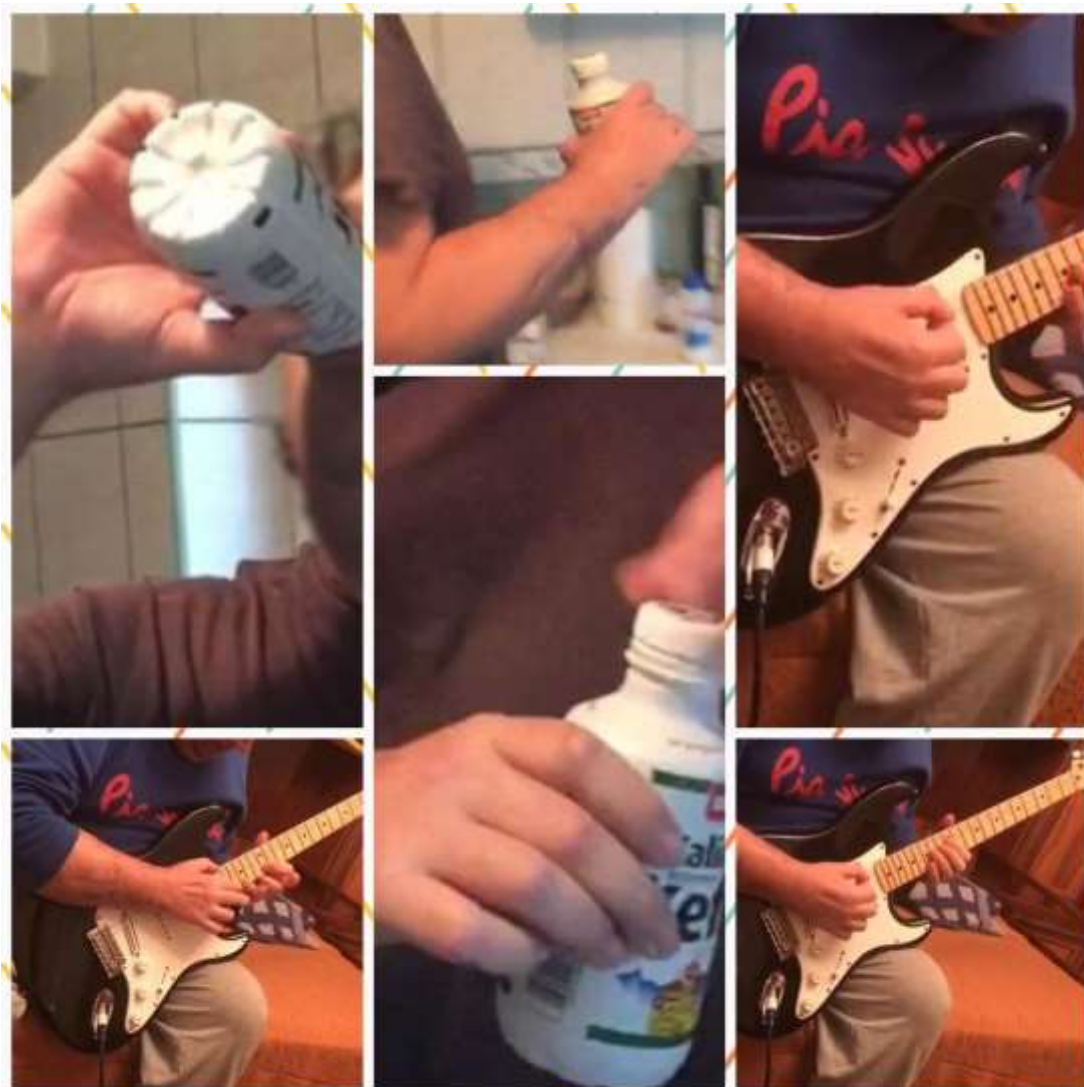## **Results**

The correct surgical approach, in a timely manner and early hand therapy as per protocol with close professional surveillance lead to limb salvage with a very good functional and cosmetic result. The patient was very happy with the result, rating it 9 out of 10. We believe that there is room for further improvement both functionally and cosmetically.

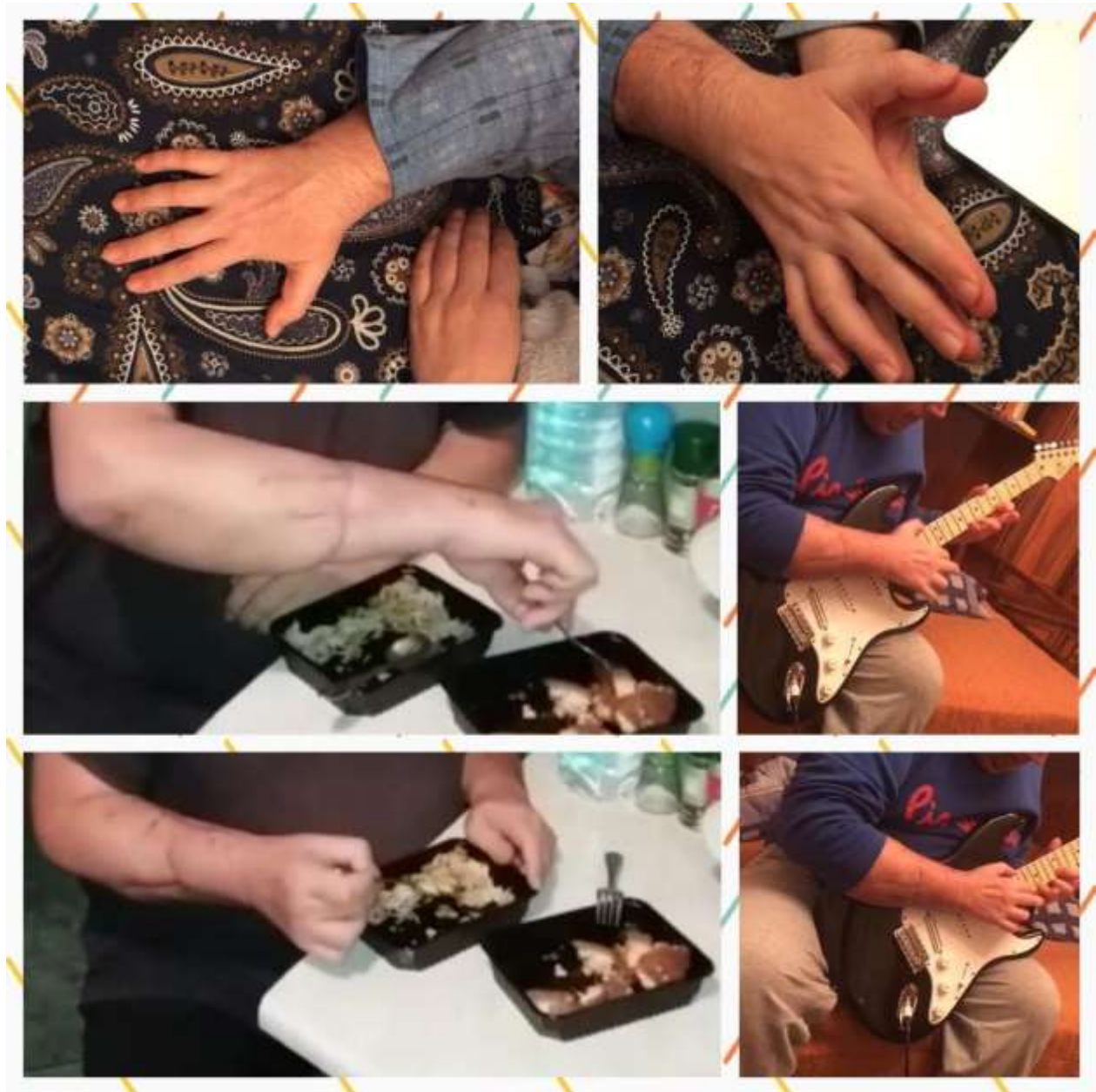At the moment, 2 years post injury he has complete recovery to the flexors and extensors in his right hand/forearm, he has full range of movement with good strength. He is only complaining of not fully recovering the fine dexterity in his fingers. He has good sensation in his hand apart from some areas that are still numb in the radial nerve territory.



**Image 1-6 days post-op**

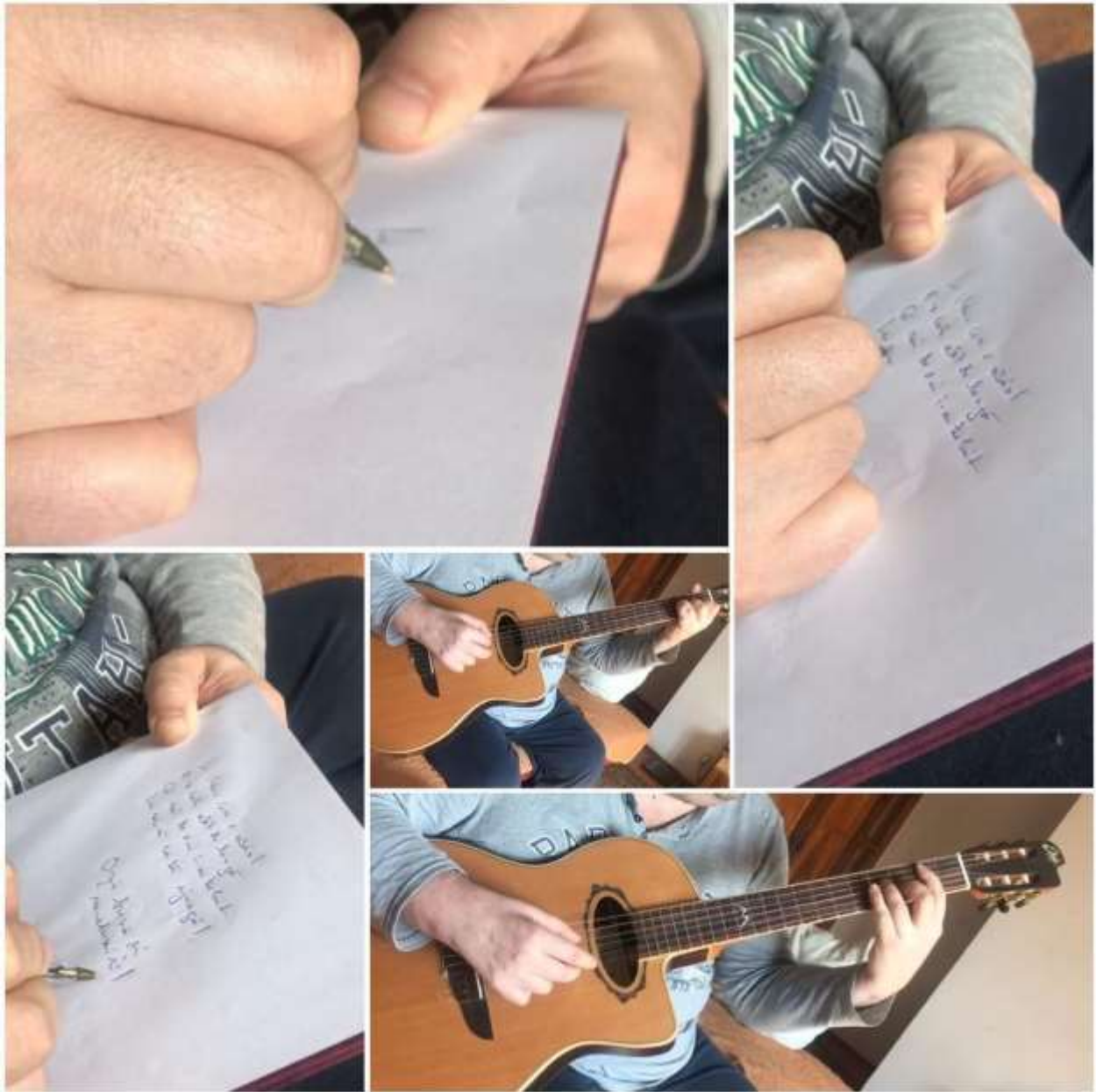


**Image 2a-Mobility at 3 months post-op**



**Image 2b-Mobility at 3 months post-op**





**Image 3-Mobility 2 years post-op**

---

## Conclusions

We estimate that the frequency of severe upper limb trauma is growing with a wide range of mechanisms which explains the complexity of each case and the need for a well-trained trauma team in all major hospitals.

Severe forearm injuries are quite common in some areas and come with a sombre perspective of patients losing their jobs and facing important consequences from social, psychological and aesthetic points of view. Therefore, despite the significant improvement of functional prosthesis, replantation of an amputated limb should be always the first thing to consider and thoroughly evaluation should be prioritised.

The decision to replant a limb should be objective, following the assessment of the tissue viability, the state of the vessels and nerves, the bones and joints integrity and the potential for recovery.

The patient needs to understand the extent of the surgery, the risk of immediate and delayed complications and the long recovery time. He also needs to be fit for a long surgical procedure and other possible concomitant injuries should be excluded or assessed.

The great challenge of the case we present is the fact that the amputated segment was still attached through a skin bridge and a thrombosed but in continuity radial artery which made it impossible for the amputated fragment to be kept in cold ischemia before getting to the hospital and also the relatively late hospital presentation bringing him very close to the 6 hours warm ischemia time which would have contraindicated the replantation due to the risk of life threatening reperfusion injury. At the time of his reperfusion he was at 5 and a half hour of warm ischemia.

Repairing the flexion/extension mechanism in a staged procedure is also a beneficial approach for the patient in terms of recovery and also shortening the first, post trauma surgical procedure.

For this type of procedure, recovery in terms of having a functional hand is as important as saving the limb.

In our experience, very early hand therapy, started at 48 hours post-surgery is very important to avoid adhesions and stiffness. As per some short studies carried out in our clinic, we have reasons to believe that very early mobilisation reduces also the risk of Volkmann Syndrome and improves a lot the functional outcome with almost full range of movement.

---

## References

1. Assessment of hand function after successful replantation of upper limb at arm; V Koteswara Rao Rayidi, Venkata Bhargava Velde, Narsimha Rao, N Ram Babu, Laxman Sambari Department of Plastic Surgery, Nizam's Institute of Medical Sciences, Hyderabad, Telangana, India; CASE REPORT Year : 2016 | Volume : 49 | Issue : 3 | Page : 415-418
2. Prevention and management of complications arising from external fixation pin sites. Bibbo C, Brueggeman J. *J Foot Ankle Surg.* 2010 Jan-Feb;49(1):87-92.
3. Wrist and Forearm Amputations, Scott G Edwards, MD; Chief Editor: Vinod K Panchbhavi, MD, FACS
4. Long-term outcome following upper extremity replantation after major traumatic amputation G. Mattiassich, corresponding author<sup>1,2,3</sup> F. Rittenschober,<sup>1</sup> L. Dorninger,<sup>1</sup> J. Rois,<sup>4</sup> R. Mittermayr,<sup>2,4</sup> R. Ortmaier,<sup>5</sup> M. Ponschab,<sup>1,2</sup> K. Katzensteiner,<sup>1</sup> and L. Larcher<sup>6,7</sup>
5. Replantation of the upper extremity: current concepts. Wolfe VM, Wang AA. ; *J Am Acad Orthop Surg.* 2015 Jun;23(6):373-81. doi: 10.5435/JAAOS-D-14-00039.
6. Bacterial skin and soft tissue infections in adults: A review of their epidemiology, pathogenesis, diagnosis, treatment and site of care, Vincent Ki and Coleman Rotstein, 2008 Mar; 19(2): 173–184, *Can J Infect Dis Med Microbiol*, PMID: PMC2605859.
7. Principles of Plastic and Reconstructive Microsurgery, Ioan Lascar, pag. 99-111, 217-236, 243-250, editura National 2005
8. Saving the upper limb after mutilating trauma, Sebe I T <sup>1,2,\*</sup> , Lascăr I<sup>1,2\*</sup> , Cortan S<sup>3,2,\*</sup> , Plostinariu M <sup>R2,\*</sup> , Carstea A <sup>I2\*</sup> , Ferariu N<sup>2,\*</sup> , Mansur W<sup>2,\*</sup> , Pencu D <sup>A2\*</sup>
9. Early rehabilitation in severe forearm injury, A.I. Carstea, I.T. Sebe, I. Lascar, S. Cortan, B.I. Diaconescu, N. Ferariu, W. Al-Akhras, D.A. Pencu, P.M. Carstea.
10. Physical Medicine and Rehabilitation, vol 2, cap 63, 85 Joel A. Delisa, editura Lippincot, editia a IV-a, 2005.
11. Replantation of an Amputated Hand: A Rare Case Report and Acknowledgement of a Multidisciplinary Team Input, Vipul Nanda,<sup>1,\*</sup> Joe Jacob,<sup>1</sup> Taif Alsafy,<sup>1</sup> Thomas Punnoose,<sup>1</sup> Sudhakar VR,<sup>2</sup> and G Iyasere<sup>3</sup>, *Oman Med J.* 2011 Jul; 26(4): 278–282

---

12. Upper-extremity self-amputation and replantation: 2 case reports and a review of the literature., Schlozman SC1, *J Clin Psychiatry*. 1998 Dec;59(12):681-6.

13. Successful Hand Replantation in a Case of Total Avulsion without Vein Graft, Shatha M. Sulaiman, MBBS, corresponding author Abdulmalik A. Alkhodair, MBBS, Shahd M. Sulaiman, MD, Lama M. Sulaiman, MD, and Ahmed S. Elkafafy, MD, FEBORAS, MRM, *Plast Reconstr Surg Glob Open*. 2018 Jan; 6(1): e1637.

