



## **Ameloblastoma with Nodal Metastasis in an Adolescent: A Multifaceted Diagnostic and Surgical Endeavor**

Hadiya Sibghatulla <sup>1</sup>, Hemkant Verma <sup>\*2</sup>, Sunigdha <sup>3</sup>, Aditi <sup>4</sup>, Himani Sharma <sup>5</sup>

- 1. Department of Pathology.*
- 2. Department of Surgical Oncology.*
- 3. Department of Radiation Oncology.*
- 4. Department of Anaesthesia.*
- 5. Department of ENT.*

**\*Correspondence to:** Hemkant Verma. Consultant Surgical Oncology IVY Hospital, Sector 71 Mohali Punjab 140308.

### **Copyright**

© 2023: **Hemkant Verma**. This is an open access article distributed under the Creative Commons Attribution License, which permits unrestricted use, distribution, and reproduction in any medium, provided the original work is properly cited.

Received: 26 October 2023

Published: 10 November 2023

---

## Introduction

Ameloblastoma, a benign intraosseous epithelial odontogenic tumor, presents a unique clinical challenge characterized by progressive growth and a predilection for local recurrence if inadequately managed. This enigmatic entity exhibits variable geographic prevalence, with a global incidence of approximately 0.92 cases per million person-years [1]. Although often indolent during its early stages, ameloblastoma attains clinical significance as it reaches considerable dimensions, leading to tissue expansion and perforation, thereby causing significant facial deformities.

The genesis of ameloblastoma is influenced by an array of risk factors, encompassing chronic inflammation, chemical exposures, human papillomavirus infections, nutritional deficiencies, suboptimal oral hygiene, and distinctive genetic polymorphisms [2].

In terms of classification, contemporary taxonomy simplifies the spectrum to three main categories: ameloblastoma, unicystic ameloblastoma, and extraosseous/peripheral types. The majority of cases present within the 30-60 years age group, with a slight male predominance, and the mandible emerges as the predominant anatomical site [3].

Metastasizing ameloblastoma, although a rare phenomenon, shares histological similarities with its benign solid/multicystic counterpart at the primary site. Intriguingly, areas of benign histology may also manifest at anatomically distant locations, a phenomenon recognized as metastases [4].

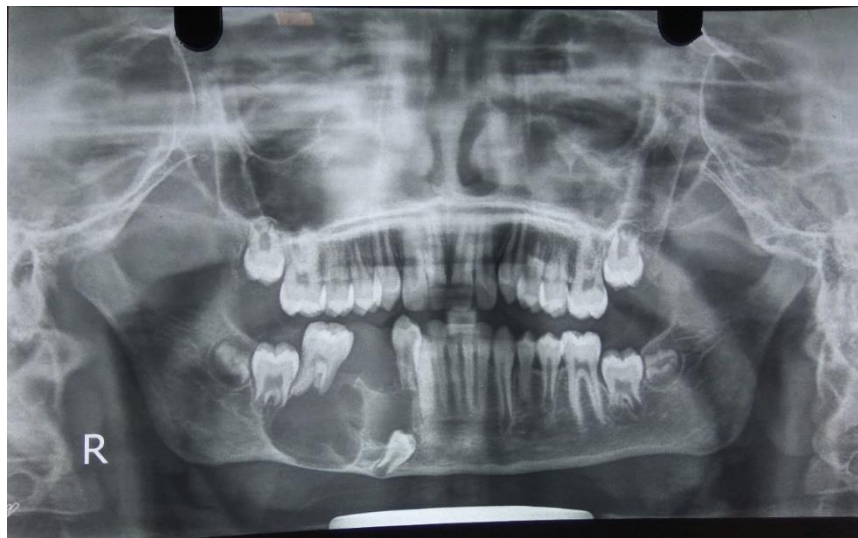Among these secondary sites, follicular ameloblastoma exhibits the highest incidence, followed by the plexiform subtype. The lungs stand as the most commonly affected secondary site [5].

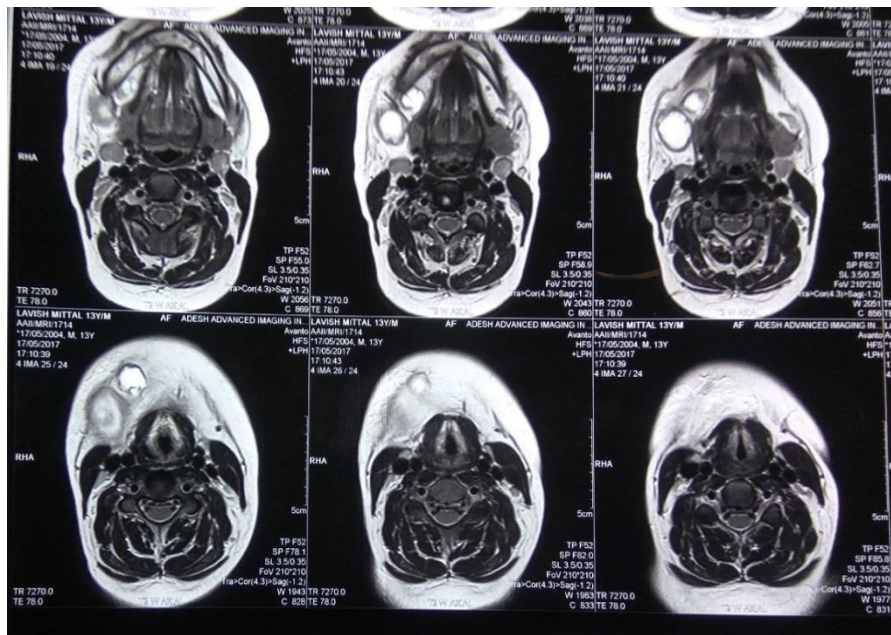
## Case Report

A compelling case of a 14-year-old male with an insidious presentation of a submandibular mass, ultimately diagnosed as ameloblastoma featuring an unusual aspect, regional nodal metastasis. The complex diagnostic approach involved ultrasonography, contrast-enhanced computed tomography (CECT), and fine-needle aspiration cytology (FNAC) to pinpoint both the primary lesion and metastatic involvement. Surgical intervention was executed meticulously, incorporating segmental mandibulectomy for primary lesion extirpation and plating for maintaining mandibular continuity.

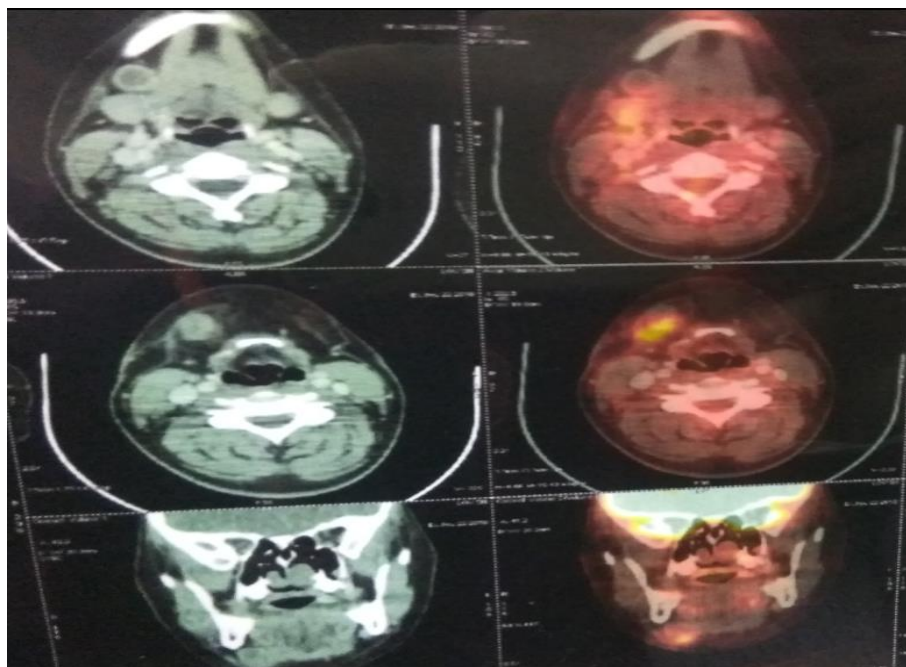
Histopathology examination -Grossly lesion of significant size, measuring 8.5 x 6.4 x 5.7 cm. Microscopically the lesion exhibited a distinctive histological pattern characterized by nests of odontogenic epithelium residing within a fibrous stroma. At the periphery of these nests, columnar cells were observed, displaying a palisading arrangement. These cells exhibited hyperchromatic nuclei and displayed reverse polarity, i.e., displacement away from the basement membrane. In the central region of the nests, the cells exhibited a resemblance to stellate reticulum.

Patient kept on follow up post procedure. Patient resumed his schooling and daily routine. He was able to take solid meals. During post operative follow up submandibular swelling was noticed on ipsilateral side. On bimanual examination submandibular glandular enlargement was ruled out. Then diagnostic radiological imaging including ultrasound and MRI were done. FNAC from level IB lymph node was suggestive of ameloblastoma deposits. To rule out other sites of involvement PET CT scan was done which revealed only level IB group of lymph nodes enlargement with SUV uptake of 8.4. Patient and family counselled for surgical clearance of nodal disease in ipsilateral neck. After pre-anesthetic check up patient was taken for Supraomohyoid neck node dissection under general anaesthesia.

**A**



B



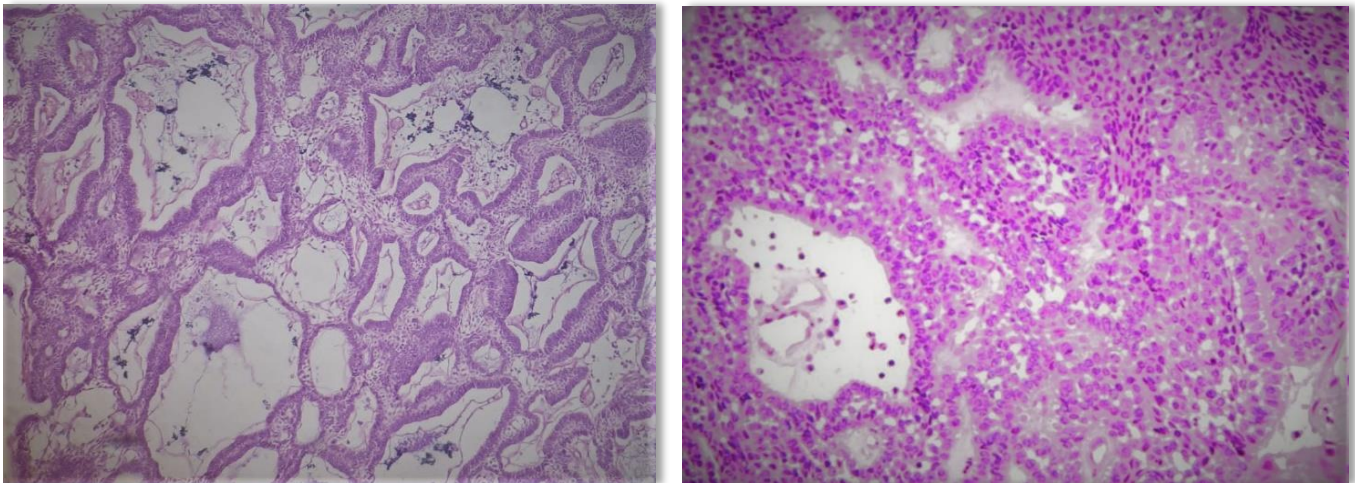
C

**Figure A:** Right mandibular radiolucency in body of it with near complete destruction of it,

**Figure B:** Right submandibular hyperinsensitivity in level IB lymph nodes,

**Figure C:** FDG avid lesion right submandibular region

The assessment of regional lymph nodes (Level I B) identified a total of 22 lymph nodes, with 2 of them showing involvement by the tumor. The larger tumor deposit within the lymph nodes measured 0.8 x 0.7 cm. Additionally, the presence of extra-nodal extension was noted. The comprehensive histopathological examination corroborated the ameloblastoma diagnosis in both the primary mandibular tumor and the implicated regional lymph nodes, thereby affirming alignment with the clinical presentation.

**D****E**

**Figure D:** 40x and **Figure E:**100x Illustrates the histological features of Ameloblastoma.

## Discussion

Ameloblastoma, originating from primitive ectoderm as well as odontomas, exhibit an intricate etiopathogenesis. Studies have elucidated that the incidence of BRAF, RAS, and FGFR2 mutations in examined ameloblastoma cases approximates 79%. Notably, these mutations demonstrate a mutual exclusivity, with a solitary exception where simultaneous BRAFV600E and FGFR-2 mutations were detected [6] This evidence underscores the pivotal role of mutations in the MAPK pathways as an early and critical event in the pathogenesis of ameloblastoma [7,8].

The intriguing occurrence of ameloblastoma in regional lymph nodes, often attributed to the phenomenon of heterotopy, presents an intricate biological process. According to one hypothesis, odontogenic epithelium becomes entrapped within lymphoid tissue during embryogenesis and may subsequently undergo benign neoplastic transformation. This potentially results in the development of ameloblastoma within a cervical

lymph node rather than indicating metastasis or local spread from a primary ameloblastoma. Notably, while histopathological features may closely resemble the primary tumor in metastatic lymph nodes, an elevated cell proliferative index, as revealed by Ki-67 immunohistochemical staining, suggests increased biological aggressiveness within the metastatic lesion. Such findings challenge the heterotopy hypothesis, and while the exact metastatic pathway remains elusive in this context, it is hypothesized that the primary pathway of metastasis primarily involves lymphatics [9].

Metastatic deposits of ameloblastoma are frequently localized within the lungs but have also been documented at alternative sites [10]. The prevailing approach to managing metastasizing ameloblastoma has remained surgical, emphasizing the necessity of some form of neck dissection for cervical lymph node metastasis [11].

A comparable investigation was conducted concerning unicystic ameloblastoma, revealing the potential for metastasis irrespective of histopathological classification [12]. Notably, Verneuil et al. reported a case of malignant ameloblastoma originating in the mandible with metastatic involvement in the submandibular region [13]. Ciment et al. chronicled a rare case of malignant ameloblastoma metastasizing to the lung, an astounding 29 years post-primary tumor excision [14]. Hayakawa et al. detailed a unique instance of metastatic ameloblastic carcinoma affecting both kidneys [18]. Hayashi et al. expounded on a peculiar case wherein mandibular ameloblastoma metastasized to the orbit. Of note, some authors have reported lung metastases seven years subsequent to the removal of the primary tumor in the lower jaw, with subsequent metastatic ameloblastoma in the lung and pleura exhibiting favorable responses to chemotherapy [16].

## Conclusion

Histologically, ameloblastoma with metastatic potential often defy differentiation from their more classical benign counterparts. It has become evident that inadequate surgical resection and prolonged tumor duration are significantly correlated with the emergence of metastatic disease.

This paradigmatic case epitomizes the imperativeness of an all-encompassing surgical approach in managing ameloblastoma with regional nodal metastasis. The rarity of nodal involvement in ameloblastoma warrants scrupulous diagnostic scrutiny and a rigorously orchestrated surgical scheme.

---

**References**

1. Global incidence and profile of ameloblastoma: a systematic review and meta-analysis. Hendra FN, Van Cann EM, Helder MN, Ruslin M, de Visscher JG, Forouzanfar T, de Vet HC. *Oral Dis.* 2020;26:12–21.
2. O.A. Effiom, O.M. Ogundana, A.O. Akinshipo, S.O. Akintoye. Ameloblastoma: current etiopathological concepts and management *Oral Dis.*, 24 (2018), pp. 307-316.
3. Larsson A, Almerén H: Ameloblastoma of the jaws. An analysis of a consecutive series of all cases reported to the Swedish Cancer Registry during 1958--1971. *Acta Pathol Microbiol Scand.* 1978, 86:337-49.
4. McClary AC, West RB, McClary AC, et al.: Ameloblastoma: a clinical review and trends in management. *Eur Arch Otorhinolaryngol.* 2016, 273:1649-61
5. Pandiar D, Anand R, Kamboj M, Narwal A, Shameena PM, Devi A: Metastasizing ameloblastoma: a 10 year clinicopathological review with an insight into pathogenesis. *Head Neck Pathol.* 2021, 15:967-74.
6. Sweeney RT, McClary AC, Myers BR, Biscocho J, Neahring L, Kwei KA, Qu K, Gong X, Ng T, Jones CD, Varma S, Odegaard JI, Sugiyama T, Koyota S, Rubin BP, Troxell ML, Pelham RJ, Zehnder JL, Beachy PA,
7. Pollack JR, West RB. Identification of recurrent SMO and BRAF mutations in ameloblastomas. *Nat Genet.* 2014;46:722–5.
8. Brown NA, Betz BL. Ameloblastoma: a review of recent molecular pathogenetic discoveries. *Biomark. Cancer.* 2015;7(Suppl 2):19–24
9. Kunze E, Donath K, Luhr HG, Engelhardt W, De Vive R. Biology of metastasizing ameloblastoma. *Pathol Res Pract* 1985;180:526–35.
10. Eisenberg E. Discussion (response to Houston G, Davenport W, Keaton W, Harris S. Malignant (metastatic) ameloblastoma: Report of a case. *J Oral Maxillofac Surg* 1993;51:1152. *J Oral Maxillofac Surg* 1993;51:1156.
11. Gilijamse FZ, Leemans CR, Winter HA, Schulten EA, van der Waal I. Metastasizing ameloblastoma. *Int J Oral Maxillofac Surg* 2007;36: 462– 64

- 
12. Noguchi, K., Kishimoto, H., Yamanegi, K., Moridera, K., Takaoka, K., & Urade, M. (2013). Unicystic ameloblastoma metastasizing to multiple cervical lymph nodes. *Journal of Surgical Case Reports*, 2013(5), rjt033.
  13. Verneuil A, Sapp P, Huang C, Abemayor E. Malignant ameloblastoma: classification, diagnostic, and therapeutic challenges. *Am J Otolaryngol* 2002; 23(1): 44-48.
  14. Ciment LM, Ciment AJ. Malignant ameloblastoma metastatic to the lungs 29 years after primary resection: a case report. *Chest* 2002; 121(4):1359-61.
  15. Hayashi N, Iwata J, Masaoka N, Ueno H, Ohtsuki Y, Moriki T. Ameloblastoma of the mandible metastasizing to the orbit with malignant transformation. A histopathological and immunohistochemical study. *Virchows Arch* 1997; 430(6): 501-7.
  16. Golubović, M., Petrović, M., Jelovac, D. B., Nenezić, D. U., & Antunović, M. (2012). Malignant ameloblastoma metastasis to the neck: radiological and pathohistological dilemma. *Vojnosanitetski preglod*, 69(5), 444-448.

