



Popliteo Cyst (Baker's Cyst): Clinical Evidence in Diagnosis and Management

Dr. Jaime Alberto Restrepo Manotas ^{*1}, Dr. Diego Fernando Gómez García ²,
Dra. Jennifer Paola Rayo Pérez ³, Dra. Katherine Restrepo Álvarez ⁴

- 1. Orthopedist and traumatologist, National University of Colombia, full Member of the Colombian Society of Orthopedic and Traumatological Surgery (SCCOT), Member of the Latin American Society of Arthroscopy (SLAR), Professor of Orthopedics and Traumatology at the University of Manizales Colombia. San Marcel clinics chief of orthopedics, Sanitas medical center and VivaLa Ips.*
- 2. Doctor, Faculty of Health Sciences, University of Caldas, Colombia*
- 3. Doctor, Faculty of Health Sciences, University of Manizales, Colombia.*
- 4. Rural doctor in compulsory Faculty of Health Sciences, University of Manizales, Colombia.*

***Correspondence to:** Dr. Jaime Alberto Restrepo Manotas, Orthopedist and traumatologist, National University of Colombia, full Member of the Colombian Society of Orthopedic and Traumatological Surgery (SCCOT), Member of the Latin American Society of Arthroscopy (SLAR), Professor of Orthopedics and Traumatology at the University of Manizales Colombia. San Marcel clinics chief of orthopedics, Sanitas medical center and VivaLa Ips.

Copyright

© 2023: **Dr. Jaime Alberto Restrepo Manotas.** This is an open access article distributed under the Creative Commons Attribution License, which permits unrestricted use, distribution, and reproduction in any medium, provided the original work is properly cited.

Received: 09 November 2023

Published: 30 November 2023

Abstract

Introduction: *The Popliteal cyst or Baker's cyst is a frequent finding in the adult population given its association with several pathologies that affect the knee joint, resulting in one of the most common reasons for orthopedic consultations, often inappropriately induced as it is a topic little known by the general practitioner; Therefore, the purpose of this work is the review and characterization of scientific research in medical practice based on its etiology, clinic, risk factors, prognosis, diagnosis, and management.*

Materials and Methods: *To prepare this article, different bibliographical approaches were carried out in databases such as Medline, Pubmed, update, Elsevier, systematic review queries and scientific studies were selected as clinical evidence, with contents on the popliteal cyst (cyst Baker), diagnosis, management, prevalence in the population, and prognosis, published between 2011 and 2021 of 9 articles related to the topic to be developed.*

Conclusion: *It is important to clearly and broadly understand the clinical relevance of incidentally finding a Baker's cyst in imaging studies or physical examination data, without this being the cause of pain in most cases, approaching this diagnosis properly considering its causes, diagnosis and management options; this with the aim of improving daily medical practice.*

Keywords: *popliteal cyst, Baker's cyst, surgical intervention, arthroscopy, gonalgia, osteoarthritis, thermal therapy, venous diagnosis.*

-Conflicts of interest: The authors have declared that there is no conflict of interest.

Definition

Baker's (or popliteal) cysts are a common disease in orthopedics in patients over 50 years of age (7). They were described in 1877 by Baker (1) and constitute the most prevalent cystic lesions around the knee joint. They increase with age, so it is hypothesized that they are the result of a degenerative tear in the posterior capsule, and chronic synovitis sustained by intra-articular disorders. From an anatomical point of view, six pouches can be identified in the popliteal fossa, and although all of these can suffer inflammation, the Baker cyst is the most frequently involved (1); They are most frequently formed by distension of the

gastrocnemius-semimembranosus bursa, which is found in the medial space of the popliteal fossa, located between the tendons of the gastrocnemius and semimembranosus muscles.

The pathogenesis of popliteal cysts revealed the presence of a valve structure that joins the cyst to the joint cavity (9) in the capsular fold of the posteromedial capsule, and associates them with inflammatory or degenerative processes in the knee joint such as osteoarthritis, meniscus tear or gout. (Table 1). The presence of a one-way valve combined with excessive production of intra-articular synovial fluid and increased intra-articular pressure, lead to a flow of fluid from the joint cavity to the semimembranosus gastrocnemius bursa with fluid accumulation, an essential factor involved in the formation and persistence of cysts (6, 8).

Causes of Baker's cyst	
<ul style="list-style-type: none"> -Meniscus injuries -Osteoarthritis -Traumas -Rheumatoid arthritis -Psoriatic arthritis -Paraneoplastic arthritis -Septic arthritis -Spondyloarthritis -Drop -Chondrocalcinosis 	Others: <ul style="list-style-type: none"> -Systemic lupus erythematosus -Mixed connective tissue disease -Lyme's disease -Sarcoidosis -Amyloidosis -Osteochondritis dissecans

Table 1. Causes of Baker's cyst

Compression phenomena of the popliteal fossa

A prospective study from 2004 established that the popliteal cyst usually develops in the posteromedial popliteal fossa due to lack of anatomical support in this area of the synovial capsule (7). However, the cyst can migrate posterolaterally and cause compression of the components of the popliteal neurovascular bundle and, depending on the affected structures, generate different symptoms.

Symptoms of nerve entrapment manifest as tibial or sciatic neuropathy with pain, burning sensation and paresthesias, and/or atrophy of the gastrocnemius muscle or, rarely, common peroneal neuropathy. Compression of the popliteal vasculature can also cause a true thrombophlebitic or pseudothrombophlebitic syndrome with pain, discomfort, swelling, and lymphedema; Arterial compression with claudication of the lower extremity due to intermittent ischemia has been documented in rare cases (7).

The rupture of the cyst can simulate thrombophlebitic symptoms and can lead to the development of a compartment syndrome, therefore it should not be ruled out that Baker's cyst may be comorbid with other conditions. It is also essential to identify the true cause of the compression because it directly affects the treatment options. (Table 2).

Differential Diagnosis of Syndromes Associated with Neurovascular Bundle Compression
<ul style="list-style-type: none"> • Baker's cyst • Thrombophlebitic syndrome caused by DVT of the lower extremity • Popliteal artery aneurysm • Intra-neural ganglion cyst of the distal divisions of the sciatic nerve • Popliteal artery adventitial cyst • Synovial sarcoma of the knee joint • Popliteal entrapment syndrome • Posterior compartment syndrome of the leg

Table 2. Differential Diagnosis of Syndromes Associated with Neurovascular Bundle Compression

Epidemiology

Baker's cyst is a common clinical condition in patients aged 35 to 70 years and constitutes the most prevalent cystic lesion around the knee joint. In a study Sansone et al. reported that 94% of popliteal cysts were associated with a knee disorder. The most common disorder was meniscal injury, followed by anterior cruciate ligament tears and/or chondral injuries. Of the meniscus injuries, 70.2% were medial meniscus tears, often involving the posterior horn (9). Johnson et al. report a prevalence of 37% in an asymptomatic adult population referring only to the popliteal bursa (1). Volteas et al demonstrated a 4.1% prevalence of underlying popliteal cyst in 1000 patients undergoing venous duplex exploration, while Langsfeld et al established a prevalence of 3.1% (95 patients) in a similar group of 3072 patients (7).

Signs and Symptoms

Clinical problems are related to the size and location of the cyst, and the most common symptoms include: popliteal mass or swelling (76%), knee effusion (32%), pain in the back of the knee and calf (32%),

thrombophlebitis (13%), knee buckling (11%), knee clicking (11%) and knee locking (3%) (8). Stiffness may appear that tends to worsen with exercise and limitations with flexion-extension. During the physical assessment carried out in a standing position, a mass was detected in the popliteal fossa, which when assessed in the supine position with semiflexion of the knee, was palpable and became more tense and evident during extension.

In case of rupture of the popliteal cyst, the outflow of synovial fluid generates an inflammatory reaction, manifested with edema, functional limitation, erythema, heat, pain, or hematoma. Sometimes generating pseudothrombophlebitic syndrome.

While incidentally detected popliteal cysts do not require treatment and are asymptomatic in most cases, large cysts can cause popliteal pain or alterations in knee range of motion, and may be the target of surgical intervention (9).

Diagnosis

It is based on suspicion based on clinical history and physical examination, but diagnostic confirmation by an imaging technique is necessary, highlighting magnetic resonance imaging, with ultrasound being the choice due to its precision, easy access and low cost.

Arthroscopic Anatomy

Arthroscopic anatomy (posterior view of the knee joint) varies depending on the angle of the OPL (oblique popliteal ligament), the level at which it crosses the medial gastrocnemius tendon, and its relationship to the capsular joint and synovium (1). The arthroscopic patterns were then classified into six groups. (Table 3).

Knowing the arthroscopic anatomical patterns of the posteromedial aspect of the knee joint could help identify the cyst and its portal of entry, thus facilitating its treatment.

	Shape	Frequency	Anatomic description
Type A	High shape or Classic form (Fig.1A)	16%	The most common form. The semimembranosus recurrent tendon crosses the medial gastrocnemius tendon very proximally. The popliteal cyst is present in 31% of cases.
Type B	Horizontal (Fig.1B)	8,8%	The semimembranosus recurrent tendon runs transversally or in an arc. A communicating popliteal cyst is present in 33.4% of cases.
Type C	Plica with a small communicating hole (Fig.1C)	6.0%	The popliteal cyst is always present and it communicates with the joint through a small hole (in 0.55% of cases the communication was through two holes).
Type D	Veil type (Fig.1D)	4,4%	The popliteal cyst is always present; a veil is present in the communicating door; the posterior anatomic structures can be seen in transparency in the background. In 75% of cases, the veil is complete; in 25% of cases, it is incomplete.
Type E	Simple Plica (s) (Fig.1E)	3,9%	Single plica with pouch (1.1%): an extroflexed capsular pouch is present under the semimembranosus recurrent tendon. The BC is never present. Double plica (2.2%): Proximally to the semimembranosus recurrent tendon there are two plicae which seem like a cystic hiatus but the cyst was never present. Triple plica (0.55%): Similar to the previous form but with three capsular plicae.
Type F	Wide type (Fig.1F)	1,1%	The popliteal cyst is always present and it communicates with the joint through a large gap.

Calvisi, V., & Zoccali, C. (2016). The arthroscopic patterns of the postero-medial aspect of the knee joint. Tabla I. Recuperado de Arthroscopic patterns of the poster-medial aspect of the knee joint: classification of the gastrocnemiussemimembranosus gateway and its relationship with Baker's cyst. *Muscles, Ligaments and Tendons Journal*.

Table 3. Arthroscopic patterns of the postero-medial aspect of the knee joint

Prevalence and associations of incidental findings of nonvenous duplex discovered during venous imaging of the lower extremities, in relation to Baker's cyst.

In their study by Michael C. Dalsing, MD, Andrew A. Gonzalez (3), they aimed to determine which ancillary elements (nonvenous duplex findings) are discovered during routine venous duplex imaging (Table 4), their prevalence and investigate associations regarding demographics and symptoms within each ancillary findings subgroup, finding the following results per ancillary subgroup:

For Baker's cyst (BC), venous outcome was significantly associated with symptom distribution. Specifically, those with nonvenous (VN) pathology were 2.48 times more likely to report pain than in studies with venous pathology (VP); That is to say, in a patient with a CB with pain as an indication for evaluation, the probabilities favor the finding of VN. In the BC-VP subgroup, the side with a BC was 2.56

times more likely to report pain and 2.15 times more likely to report swelling. In the BC-VN subgroup, the side with BC was 12.8 times more likely to report pain and 10.75 times more likely to report swelling (Table 5). Having documentation of cancer, a local infection, or recent surgery/trauma was not associated with whether the venous outcome was VN or VP.

Some reports associate BC with deep vein thrombosis, while others document them imitating it, establishing a "pseudothrombophlebitis syndrome" with pain and swelling of the calf. However, a BC and venous disease can coexist with overlapping and exacerbated symptoms, as evidenced by more leg symptoms on the side with both findings in the study. The large distribution of leg symptoms on the BC side in the BC-VN subgroup provides an alternative diagnosis for the patient's symptoms.

Ancillary duplex finding	OR [95% CI]	P value
LN(s)	1.804 [1.641-1.983]	<.001
BC	1.528 [1.293-1.806]	<.001
Hematoma	1.542 [1.10-2.16]	.013
AA	0.518 [0.321-0.835]	.009
AO	0.597 [0.313-1.14]	.159

AA, Arterial aneurysm; AO, arterial occlusion; BC, Baker's cyst; CI, confidence interval; LN, lymph node; OR, odds ratio.

Dalsing, M. C., Gonzalez, A. (2021). The odds of an ancillary finding being documented on a venous duplex based on whether venous pathology (VP) is present. Table II. Prevalence and associations of incidental nonvenous duplex findings discovered during lower extremity venous imaging. *Journal of Vascular Surgery. Venous and Lymphatic Disorders*.

Table 4. The odds that an ancillary finding will be documented in a venous duplex based on the presence of venous pathology (PV).

Lymph node (LN) is the most common ancillary finding observed, and was 6.28 times more likely to report pain and 7.32 times more likely to report swelling. In the LN-VN subgroup, the side with LN(s) was 19.32 times more likely to report pain and 17.88 times more likely to report swelling.

For hematoma/mass (HM) in the HM-VP subgroup, the presence of an HM was 9.75 times more likely to report pain and 8.48 times more likely to report swelling. In the HM-VN subgroup, the side with HM was 35.1 times more likely to report pain and 23.67 times more likely to report swelling.

In the arterial aneurysm (AA) subgroup, the venous outcome was not associated with the distribution of symptoms. In the AA-VN and AA-VP subgroups, the side with an AA had no association with symptom distribution.

For arterial occlusion (AO), an infrequent finding (#0.3%), there was no association with symptom distribution dependent on the side of the presence of AO in the AO-VP subgroup. However, in the AO-VN subgroup, there was a significant association ($p = 0.04$). Specifically, the presence of an OA was 12.83 ($p5\%$ CI, 1.69-97.18) times more likely to report pain ($p \frac{1}{4} 0.02$). Remember that an important symptom of arterial occlusive disease is claudication or pain at rest, but not necessarily swelling.

Based on their study it can be concluded that:

- a) Auxiliary findings are not uncommon (8.6% of all venous studies).
- b) Are more common in studies that are free of VP (5.5% VP vs. 10% VN, $P < 0.001$). With an OR of 1.88 that certainly reinforces the justification of the Well criterion to subtract a more probable alternative diagnosis when evaluating DVT.
- c) The most common are lymph node, Baker's cyst and hematoma/mass.
- d) Within ancillary subgroups, leg symptoms are generally more common on the side with ancillary pathology and especially prominent in those free of coexisting VP. In some cases, the ancillary finding may exacerbate venous symptoms, while in others it may explain the patient's symptoms.
- e) A venous duplex study should look for and report ancillary pathology to allow the referring physician to provide care and be able to provide an alternative explanation for the symptoms and/or alert to pathologies that may require immediate investigation (urgent or emergent).

Leg Symptom	VP in limb with BC	VP in limb without BC	VN in limb with BC	VN in limb without BC
Pain	73	38	332	75
Swelling (local)	100 (8)	62 (1)	279 (41)	75 (14)
Asymptomatic	30	40	55	159

The BC may or may not be on the side of primary venous study indication. This is the symptom distribution by VP or VN and by side with and without BC with analytical comparisons. (local) represents the number of studies with primary indication local swelling/mass/lump rather than generalized swelling which are not separated for analysis.

Analytics:

Row × column comparison	P value	Pain vs asymptomatic OR [95% CI]	P value	Swelling vs asymptomatic OR [95% CI]	P value
VP with BC × VN with BC	<.001	2.48 [1.49-4.14]	.001	1.52 [0.92-2.51]	.13
VP with BC × VP without BC	.006	2.56 [1.39-4.74]	.004	2.15 [1.22-3.80]	.012
VN with BC × VN without BC	<.001	12.8 [8.61-19.01]	<.001	10.75 [16.02]	<.001

OR, Odds ratio; VN, no venous pathology.

Dalsing, M. C., Gonzalez, A. (2021). Subgroup of studies with a Baker's cyst (BC) noted on at least one side. Table IV. Prevalence and associations of incidental nonvenous duplex findings discovered during lower extremity venous imaging. *Journal of Vascular Surgery. Venous and Lymphatic Disorders*.

Table 5. Subgroup of studies with a Baker's cyst (BC) annotated on at least one side

Medical Surgical Treatment Options

A small, asymptomatic popliteal cyst found by chance on an MRI or ultrasound is not treated, it may even disappear on its own. In general, the underlying cause of the cyst should be treated rather than the cyst itself.

Treatment of symptomatic Baker's cyst can be conservative or surgical. Some authors report a good success rate for conservative treatment. In case of being symptomatic after ruling out other knee pathologies, and according to the clinic, conservative treatment can be established that includes physical means (ice), elasto-compression, control of physical activity, strengthening physiotherapy and maintenance of ranges of movement and use of anti-inflammatories. If symptoms persist, are recurrent, or there is limited range of motion, puncture of the cyst under local anesthesia, aspiration of the contents, and infiltration may be proposed. Infiltrative therapy could be more effective when intra-articular disease is in an early stage (1).

In cases that remain symptomatic, endoscopic surgical management is indicated, with knee arthroscopy to rule out pathologies that may be associated with the development of the popliteal cyst. That is, when cyst-related symptoms persist, limit the patient's knee function, or become symptomatic due to compression of surrounding structures, surgery may be required (1). Exceptionally, large and symptomatic cysts that cannot be resolved with prior intervention are subjected to open resection.

Smith et al. published the results of ultrasound-guided aspiration, fenestration, and injection of 48 Baker cysts with a median follow-up of 106.5 weeks; reported a recurrence rate of 12.7% identifying advanced osteoarthritis as the main risk factor (1).

Surgical interventions for the treatment of popliteal cysts focus on managing intra-articular lesions, enlarging or repairing the communication between the cyst and the joint cavity, as well as resection of the cyst. However, open surgical resections of cysts typically result in high recurrence rates. The recurrence rate after simple open resection is reported to range from 42% to 63% (1, 8).

In a prospective study in which only intra-articular lesions were managed, favorable therapeutic efficacy was achieved in only 5 of 16 patients during the follow-up period. This finding suggests that the management of intra-articular lesions alone does not achieve favorable therapeutic efficacy. (9) Therefore, if the valve mechanism is not corrected during surgery, a continuous flow of joint fluid will occur. This may explain why the recurrence rate after open surgery remains high in several studies. In addition, there are concerns about cosmetic problems, the large incision in the back of the knee, pain, risk of neural injuries, and the longer time to perform it (4, 5).

The arthroscopic approach becomes more important if we consider the high incidence of recurrence of the Baker cyst after its removal by a posterior approach and without treating the associated intra-articular pathologies, including meniscus lesions, patellofemoral arthritis, rheumatoid arthritis, synovitis, cartilage damage (5). Therefore, the first step to treat a symptomatic Baker's cyst would be to perform a diagnostic arthroscopy, followed by the treatment of knee pathologies or those disorders that cause chronic synovitis, at the time of arthroscopic surgery (1, 6).

A current review reported that arthroscopic management of intra-articular lesions and enlargement of the communication between the cyst and the joint cavity are effective strategies for the management of popliteal cyst. There is no specific scientific evidence on the exact size of the resection, however, in one study the communication channel was expanded to at least 6 cm long and 3 cm wide during surgery, with favorable results (4). In recent years, good achievements have been reported with arthroscopic resection of the communication with a recurrence rate of less than 10%.

A meta-analysis showed that, although communication enlargement was the most common primary procedure, studies in which intra-articular lesions were also treated showed success rates of up to 96.7%; These studies used arthroscopy. Consequently, it can be determined that arthroscopic management of intra-

articular lesions and enlargement of the communication between the cyst and the joint cavity is an effective strategy for popliteal cyst. (9). The success rate of these arthroscopic enlargement procedures is better than that of arthroscopic closure surgeries (80 to 86.4%) and simple open resection (37%), reaching rates of 90 to 100% (4).

Calvisi et al. reported on communication closure surgery and management of intra-articular lesions by arthroscopy. Of 22 patients in this study, the success rate was 86.4%, suggesting favorable efficacy (9). No neurovascular complications were reported. The effectiveness of this technique was evaluated by magnetic resonance imaging 2 years after surgery. The cyst was found to have disappeared in 64%, reduced in size in 27% and persisted in 9% of cases. Lindgren detected pressure in the gastrocnemius semimembranous bursa and knee joint and suggested that such repairs might be ineffective in maintaining normal pressure changes, which could explain the relatively high recurrence rate in these communication closure surgeries (8)

After cyst wall resection, communication enlargement surgery studies showed that the combined success rate was 98.2%; and 94.7% in the absence of wall resection (review by Zhou et al.). Therefore, it could be inferred that resection of the cyst wall can benefit patients with symptomatic popliteal cysts, and although it does not significantly increase the success rate, it is an effective method that can currently be proposed. (9) Relatedly, the benefit of arthroscopic cystectomy is also controversial due to the association with a relatively high incidence of complications (4, 6).

<i>Advantages</i>	<i>Disadvantages</i>
<ul style="list-style-type: none"> -Fast and reproducible procedure that can be performed simultaneously with other procedures for intra-articular injuries. -Possibility of completely eliminating the valve mechanism and controlling bidirectional fluid flow in a fluid environment. -Quick recovery, cosmetic scars. -Early return of range of motion, 1-day surgery. -Only typical arthroscopic instruments are required. 	<ul style="list-style-type: none"> -Working near the popliteal neurovascular bundle with the risk of injuring it. -Experience in posterior portal preparation and knowledge of the endoscopic anatomy of the posterior knee is required. -Preoperative MRI planning is always required -Conversion from supine to prone position may be necessary.

Malinowski, K., Hermanowicz, K. (2019). Advantages and Disadvantages of Arthroscopic Popliteal Cyst Treatment. Table 2. Possible approaches to endoscopic treatment of popliteal cysts: From the basics to troublesome cases. *Arthroscopy Techniques*.

Table 6. Advantages and disadvantages of arthroscopic treatment of popliteal cyst

Ultrasound-guided percutaneous treatment

Ultrasound-guided puncture, aspiration and corticosteroid injection is a conservative treatment that is preferred as an initial plan, with a recurrence rate of 12.7%, reported in a study of 48 BC with a median follow-up of 106.5 weeks, where advanced osteoarthritis was identified as the main risk factor (1).

Regarding ultrasound-guided surgery, it has 3 advantages:

- ❖ Injection of a contrast dye into the cyst makes it more reliable, allowing simultaneous accurate identification. Avoids the risk of neurovascular injury.
- ❖ It is possible to evaluate the interior of the cyst immediately after communication enlargement procedures. And the need for additional procedures such as septal resection.
- ❖ Ultrasound-guided multimodal drug injection can provide a high degree of pain relief (4).

Not all disorders can be definitively treated, as occurs in diffuse chondral lesions or secondary hypertrophy of the synovial membrane, since the knee is predisposed to recurrent effusions and the cyst can reappear.

Ultrasound-Guided Arthroscopic Defect Enlargement Surgery

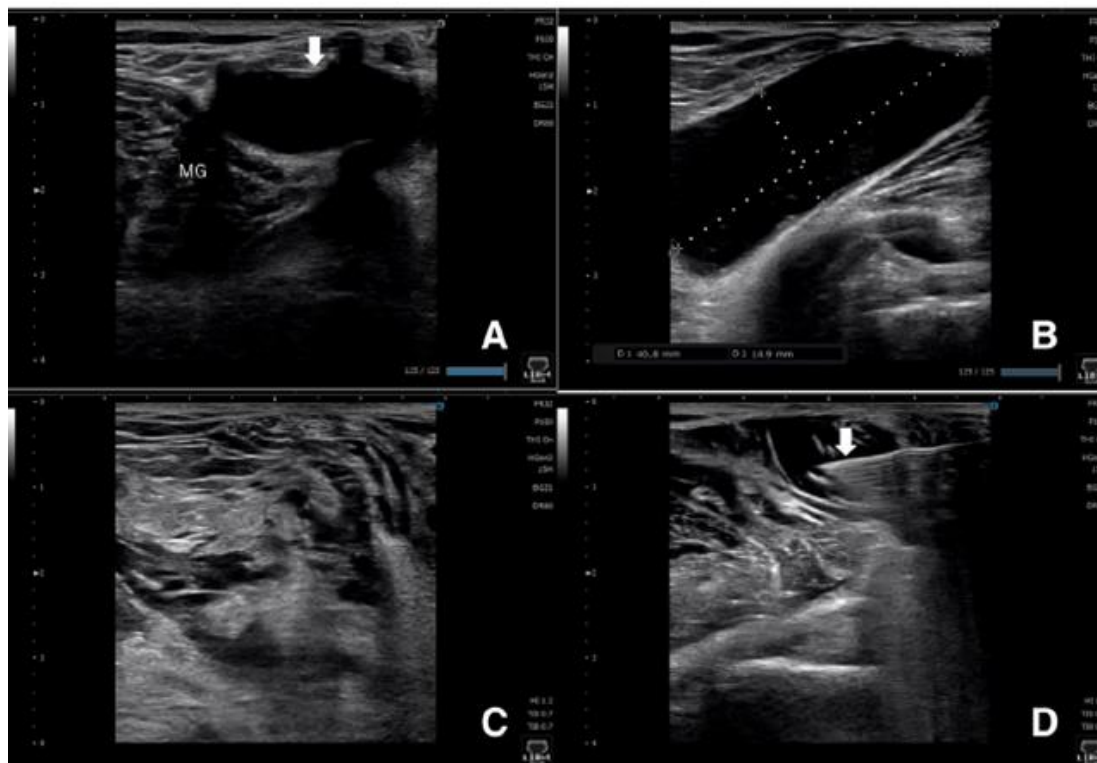
Ultrasound-guided arthroscopic surgery is performed in symptomatic cases refractory to conservative treatment. For asymptomatic cases, expectant management is recommended.

Procedure Description: Ultrasound-guided percutaneous treatment, as described by Koroglu et al., after disinfection and induction of local anesthesia, popliteal cysts are punctured with an 18 G needle under ultrasound. Ultrasound-guided puncture, aspiration, and corticosteroid injection are performed using a freehand technique by the surgeon. The cyst is almost completely decompressed and 4 mg of Kenacort (4 mg of triamcinolone acetonide) is subsequently administered into the cyst under ultrasound guidance.

This treatment has a reported success rate of 87% and should be considered a first-line intervention as it is the most minimally invasive procedure. After 3 months of follow-up, surgical treatment is recommended in case of recurrence. (4)

Surgical technique: With knee flexion at 80°, standard 2-portal approach for observation, a camera is inserted into the posteromedial compartment, needle is inserted into the cyst under ultrasound guidance. Subsequently, a contrast medium (approximately 10 ml of 0.4% indigo carmine) is injected into the popliteal cyst percutaneously. The valve between the semimembranosus and medial gastrocnemius is enlarged with a shaver and radiofrequency ablation, widening the canal of. comunicación a al menos 6 cm de largo y 3 cm de ancho. Se succiona líquido de irrigación y finalmente se inyecta un fármaco multimodal periarticular bajo ecografía en el tabique y la pared interna del quiste (Figura 1).

Se permite el rango completo de movimiento de la rodilla y la carga total de peso desde el primer día posoperatorio (4).



a) Short-axis view of the cyst (thin white arrow). b) Long axis view of the cyst and its size. c) Obviously, the size of the cyst is reduced. d) A periarticular multimodal drug is injected under ultrasound (white arrow) to ensure postoperative pain relief. MG: medial gastrocnemius.

Figure 1. Ultrasound findings of the right knee before and after enlargement of the communication.

Goto, K., & Saku, I. (2020). Ultrasound findings of the right knee before and after communication enlargement. Figura 2. Ultrasound-guided arthroscopic communication enlargement surgery may be an ideal treatment option for popliteal cysts - indications and technique. *Journal of Experimental Orthopaedics*.

Possible approaches for the endoscopic treatment of popliteal cysts

The basic arthroscopic technique presented in the article “Possible Approaches to Endoscopic Treatment of Popliteal Cysts” by Malinowski, K., Hermanowicz, K.), provides the tools to successfully treat different types of popliteal cysts, from the simplest to the most demanding (Figure 2). Furthermore, it allows the surgeon to address each element of popliteal cyst pathogenesis by eliminating the valvular mechanism, enlarging the communication between the cyst and the joint cavity, and excising the cyst walls (6). Within the approaches, the following techniques are described, to name:

- Basic arthroscopic communication technique, enlargement surgery with excision of the cyst wall.
- Undetectable entry to cyst in posteromedial joint capsule or large cyst extending to thigh.
- Approach to the popliteal cyst caused in continuity by pathology of the posterior medial meniscus.
- Popliteal approach for a large popliteal cyst descending into the calf or cyst near the popliteal neurovascular bundle.

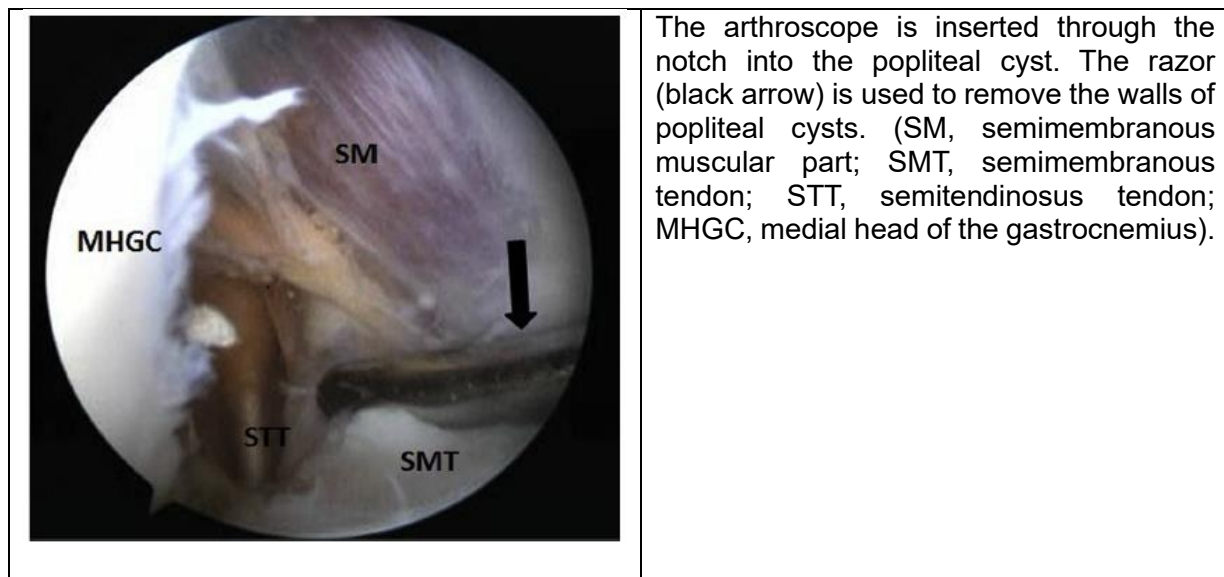


Figure 2. Arthroscopic view from the anterolateral viewing portal in the right knee.

Malinowski, K., Hermanowicz, K. (2019). Arthroscopic view from the anterolateral viewing portal in the right knee. *Figure 5. Possible approaches to endoscopic treatment of popliteal cysts: From the basics to troublesome cases. Arthroscopy Techniques.*

Arthroscopic treatment for popliteal cyst between techniques using one posteromedial portal (OPP) and two posteromedial portals (TPP)

In one study, 53 patients with popliteal cysts were investigated. Twenty-five patients received arthroscopy via OPP and 28 patients received arthroscopy via TPP. Among the patient cohort, 36 (68%) had meniscal injuries, including 17 patients in the OPP group and 19 patients in the TPP group. Degenerative osteoarthritis was observed in 33 patients (62%) in total, including 15 patients in the OPP group and 18 patients in the TPP group. Synovitis was also recorded in 28 patients (53%), including 13 patients in the OPP group and 15 patients in the TPP group. Additionally, 1 patient in the TPP group had plica. In this regard, it was reported that the operation time of the TPP group was significantly longer than that of the OPP group ($p < 0.001$). In the OPP group, the cysts disappeared in 17 patients and reduced in size in 8 patients. In the TPP group, the cysts disappeared in 23 patients and reduced in size in 5 patients. According to the Rauschnig and Lindgren classification, the recurrence rate was significantly lower in the TPP group (0%) than in the OPP group (4%) ($p = 0.03$).

With the above, it was possible to establish that the TPP technique is more effective and superior than the OPP technique for the treatment of popliteal cysts. (5)

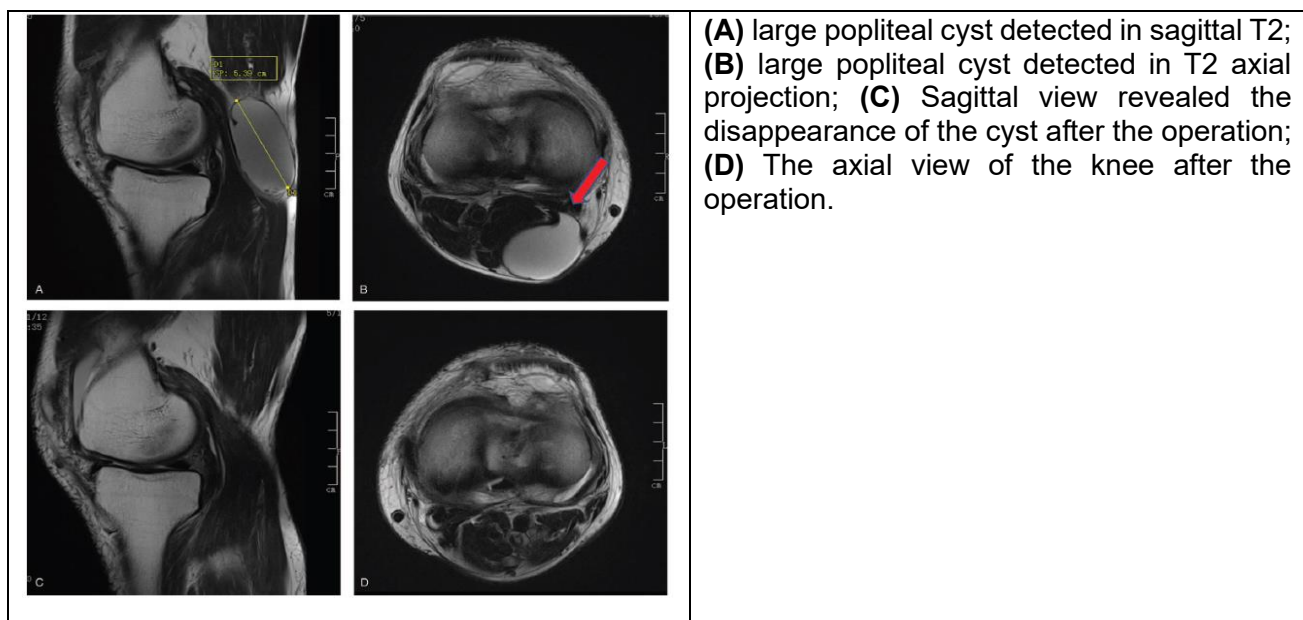


Figure 3. large popliteal cyst detected on T2.

Guo, D., Cheng, L., Chen, G., Yu, X., Zhang, H., & She, Y. (2020). Large popliteal cyst detected in sagittal T2. Figure 6. A comparison of the clinical effects of arthroscopic treatment for popliteal cyst between techniques using one posteromedial portal and two posteromedial portals. *Medicine*.

Arthroscopic internal removal of popliteal cysts with or without resection of the cyst wall

A Chao Su, Shi-da Kuang (8) study aimed to compare arthroscopic internal drainage of popliteal cysts alone or in combination with cyst wall resection in terms of clinical outcomes.

Procedure description

- Arthroscopic internal drainage (AI group): In the supine position, the first step was to create standard anterolateral (AL) and anteromedial (AM) portals and perform a routine arthroscopic examination. The second step was to create a standard posteromedial (PM) portal, with 90° knee flexion. The third step was to remove the capsular fold to enlarge the cyst orifice, to restore normal two-way communication.
- Arthroscopic internal drainage combined with resection of the cyst wall (AICR group): The first three steps are the same as the group AI. The fourth step was to create a high posteromedial portal, a needle no. #12 as a guidance probe under visualization to create it. The fifth step was to perform resection of the cyst wall.

The effects of surgical intervention for popliteal cysts were evaluated with MRI. The results showed that the popliteal cyst completely disappeared in 55% of cases, reduced in size in 30%, and persisted in 15% during a mean follow-up of 24.6 months. Postoperative recurrence of popliteal cysts occurred in 15%, in the AI group. Comparatively, the cyst completely disappeared in 81.8% of cases, reduced in size in 18.2%, and persisted in 0% in the AICR group.

This study demonstrated that additional resection of the cyst wall could result in a lower rate of cyst recurrence, but extend the operation time and slightly increase the incidence of perioperative complications (such as hematoma formation or extravasation under the gastrocnemius muscle). , among others) compared to arthroscopic internal drainage of popliteal cysts alone; Therefore, preoperative planning through MRI is suggested to help confirm whether a posterior knee cyst is a true Baker's cyst, as well as prevent injury to structures.

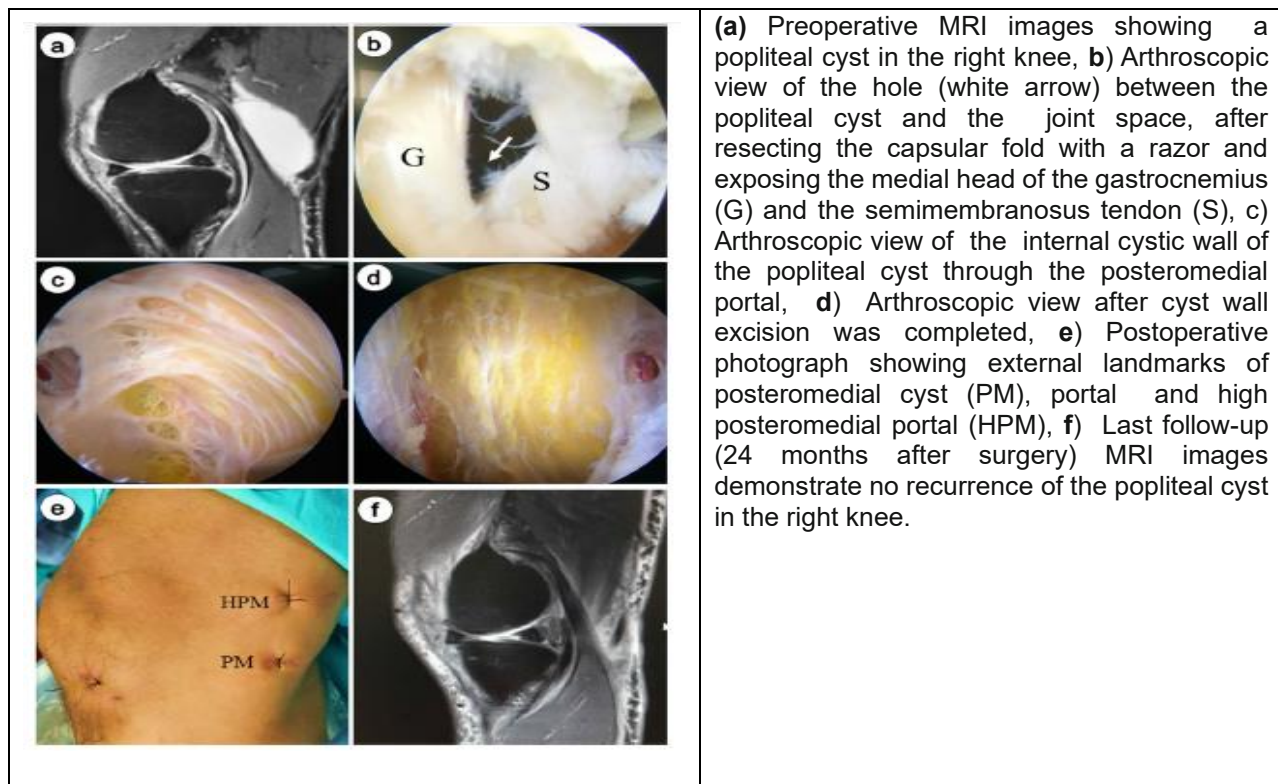


Figure 4. Preoperative MRI images showing a popliteal cyst in the right knee.

Su, C., Kuang, S. Zhao, X. (2020). Pre-operative MR images demonstrate a popliteal cyst on the right knee. Figura 1. Clinical outcome of arthroscopic internal drainage of popliteal cysts with or without cyst wall resection. *BMC Musculoskeletal Disorders*.

Laser Induced Interventional Thermal Therapy (LITT)

It is an emerging technique to treat popliteal synovial cysts, its objective is coagulation and subsequent obliteration of the inosculation and cystic cavity under local tumescent anesthesia, using ultrasound as an imaging method. This technique is based on the fact that obliteration of only the cystic popliteal cavity can provide persistent recovery, however, the authors S.A. Chernyadiev¹, V.B. Aretinskiy in their article (2) expose risks or complications related to the procedure such as burning of the subcutaneous adipose tissue due to the difficulty of ultrasound visualization of the fine light tube through the softer tissues, and do not consider that tumescent anesthesia is an optimal solution for laser-induced thermal therapy of Baker's cyst due to contributing to an overheating effect, not providing a substantial anesthetic effect, and the tendency to tighten the tissues causing light to be completely absorbed with a greatly increased local temperature up to the carbonization point.

Rehabilitation

The rehabilitation protocol will be given according to the procedures performed for knee pathologies. As the soft tissues of the popliteal fossa are affected to avoid a flexion contracture, the patient must fully extend the knee after the operation and if soft tissues are involved around the knee, passive flexion to at least 90° is also recommended immediately after surgery (6).

It is important to train lower extremity quadriceps contraction and ankle pump movements, isometric exercises and extended leg raises (8). For meniscoplasty patients, weight bearing is allowed on the 2nd day after surgery as tolerated. For meniscorepair patients, weight bearing is allowed 2 to 4 weeks after surgery, and then weight bearing is allowed as tolerated with 2 crutches (5). While active knee flexion and muscle strength exercises approximately 3 months after the operation. (8)

Forecast

In most cases, a popliteal cyst does not cause long-term damage, although it is uncomfortable and annoying. Symptoms may appear, disappear, or improve over time and rarely cause disability.

Exceptionally, Baker's cyst may present spontaneous or traumatic rupture and manifest symptoms and signs such as acute pain, edema in the calf area, hematoma, and decreased size. Usually in these cases only anti-inflammatory analgesic management is required, ensuring that complications do not develop due to edema, rest and physical means. It does not usually require other types of treatments.

Conclusions

- Epidemiological studies have shown that Baker's cysts are often associated with knee joint disorders
- According to current evidence, arthroscopic excision of the cyst wall, arthroscopic management of intra-articular lesions and expansion of communication between the cyst and the joint cavity constitute an excellent management strategy for Baker's cyst.
- Ultrasound-guided percutaneous treatment (puncture, aspiration and corticosteroid injection) is a conservative, minimally invasive treatment, with a recurrence rate of 12.7%, reported success rate of 87%, so it should be considered an intervention first line or initial plan.

-
- Further resection of the cyst wall could result in a lower recurrence rate, but extend the operative time and slightly increase the incidence of perioperative complications.
 - Arthroscopic treatment for Baker's cysts compared to open excision is less invasive, is associated with better clinical outcomes, and can address both intra-articular pathology and popliteal cyst directly.
 - Arthroscopic surgery is more effective and allows for a faster recovery and an early introduction to rehabilitation.
 - Arthroscopic management using two posteromedial portals (TPP) is an effective and superior method for the treatment of popliteal cysts.
 - Not all knee disorders that cause the onset of Baker's cyst can be definitively treated, such as in middle-aged patients, in whom the knee is predisposed to frequent effusions and the cyst may eventually recur.
 - Ancillary findings in venous studies, such as Baker's cyst, are not uncommon (8.6%) and are more common in studies that are free of venous pathology.
 - For baker's cyst, venous outcome was significantly associated with symptom distribution. Specifically, those with nonvenous pathology are 2.48 times more likely to report pain than in studies with venous pathology.
 - Laser-induced interventional thermal therapy (LLT) is a promising emerging technique for treating popliteal synovial cysts, however, it has been associated with risks and/or complications such as burning of subcutaneous adipose tissue.
 - In general, the underlying cause of Baker's cyst should be treated rather than the cyst itself.

References

1. Calvisi, V., & Zoccali, C. (2016). Arthroscopic patterns of the poster-medial aspect of the knee joint: classification of the gastrocnemius-semimembranosus gateway and its relationship with Baker's cyst. *Muscles, Ligaments and Tendons Journal*, 6(4), 492–498.

2. Chernyadiev, S. A., Ural State Medical University, Ekaterinburg, Russian Federation, Aretinskiy, V. B., Zhilyakov, A. V., Korobova, N. Y., Kutepov, S. M., ... Ural State Medical University, Ekaterinburg, Russian Federation. (2020). Complication of laser-induced thermal therapy for Baker's cyst. *Genij Ortopedii*, 26(1), 95–98.
3. Dalsing, M. C., Gonzalez, A. A., Maijub, J. G., Rollins, D. M., & Timsina, L. R. (2021). Prevalence and associations of incidental nonvenous duplex findings discovered during lower extremity venous imaging. *Journal of Vascular Surgery. Venous and Lymphatic Disorders*, 9(1), 200–208.
4. Goto, K., & Saku, I. (2020). Ultrasound-guided arthroscopic communication enlargement surgery may be an ideal treatment option for popliteal cysts - indications and technique. *Journal of Experimental Orthopaedics*, 7(1), 93.
5. Guo, D., Cheng, L., Chen, G., Yu, X., Zhang, H., & She, Y. (2020). A comparison of the clinical effects of arthroscopic treatment for popliteal cyst between techniques using one posteromedial portal and two posteromedial portals. *Medicine*, 99(20), e20020.
6. Malinowski, K., Hermanowicz, K., Góralczyk, A., Guszczyn, T., Sadlik, B., Synder, M., & LaPrade, R. F. (2019). Possible approaches to endoscopic treatment of popliteal cysts: From the basics to troublesome cases. *Arthroscopy Techniques*, 8(4), e375–e382.
7. Sanchez, J. E., Conkling, N., & Labropoulos, N. (2011). Compression syndromes of the popliteal neurovascular bundle due to Baker cyst. *Journal of Vascular Surgery*, 54(6), 1821–1829.
8. Su, C., Kuang, S., Zhao, X., Li, Y.-S., Xiong, Y.-L., & Gao, S.-G. (2020). Clinical outcome of arthroscopic internal drainage of popliteal cysts with or without cyst wall resection. *BMC Musculoskeletal Disorders*, 21(1), 440.
9. Zhou, X.-N., Li, B., Wang, J.-S., & Bai, L.-H. (2016). Surgical treatment of popliteal cyst: a systematic review and meta-analysis. *Journal of Orthopaedic Surgery and Research*, 11(1), 22.

