



Recurrent Guillain Barre Syndrome- Case Report and Review of Literature.

Vinayak Jatale *¹, Dr Kanav Gupta ²

1. MBBS MD, SR neurology, Department of neurology, AIIMS Rishikesh.
2. MBBS MS, SR neurosurgery, Department of neurosurgery, AIIMS Rishikesh.

Corresponding Author: Vinayak Jatale, MBBS MD, SR neurology, Department of neurology, AIIMS Rishikesh.

Copy Right: © 2022 Vinayak Jatale, This is an open access article distributed under the Creative Commons Attribution License, which permits unrestricted use, distribution, and reproduction in any medium, provided the original work is properly cited.

Received Date: December 21, 2022

Published Date: January 01, 2023

This 31 years' male came to us with complains of acute onset ascending sensorimotor progressive flaccid quadriparesis with truncal, neck, facial and bulbar weakness without any bowel bladder involvement of total duration 5 days. He gave a preceding history of loose stool about a week ago. He also gave history of having similar weakness episodes two times in seven years. Anatomical localization to nerves in the form of polyneuropathy and post infectious cause was kept, hence a diagnosis of Guillain barre' syndrome (GBS) was made. Examination showed a power of 2/5 proximally in upper limb and lower limb with bilaterally facial LMN weakness with truncal and neck weakness at presentation. His investigation showed normal cerebrospinal fluid and demyelinating neuropathy on nerve conduction studies as shown in the table and figure.

Case was managed with IVIG (2mg/kg total dose) and he required intubation on the third day of admission owing to respiratory insufficiency. Workup was done to rule out recurrent causes of polyneuropathy. His viral markers were negative. ANA ENA profile negative. Serum ACE levels were normal. There was no history for toxin exposure. Due course he developed complication in form of ventilatory acquired pneumonia and IVIg induced transaminitis and recovered from both subsequently. He responded to treatment well and was off ventilator by 3 weeks of illness and was discharged in a month of admission with tracheostomy tube in situ. He was under regular follow and was able to walk independently by five months of onset of illness. By one year of duration, he was able to do all activities by himself except mild residual weakness in both handgrips. There was no further worsening.

History showed his first attack of flaccid quadriparesis was at 24-year age (7 years ago) and second attack at 27 (5 years ago) years of age. Both of the time he required admission with first attack being more severe than the second. He required ventilator during first attack and also had developed complications in form of pneumothorax and tubercular bacilli were found in pleural fluid and received anti-tubercular treatment for 6 months. His investigations were suggestive of albumino-cytological dissociation and demyelinating neuropathy both times. He received plasmapheresis in his first admission and had received methyl-prednisolone during second attack. He recovered completely in between without any residual weakness.

Nerve Conduction Velocity Report:

Motor Nerve Conduction Study

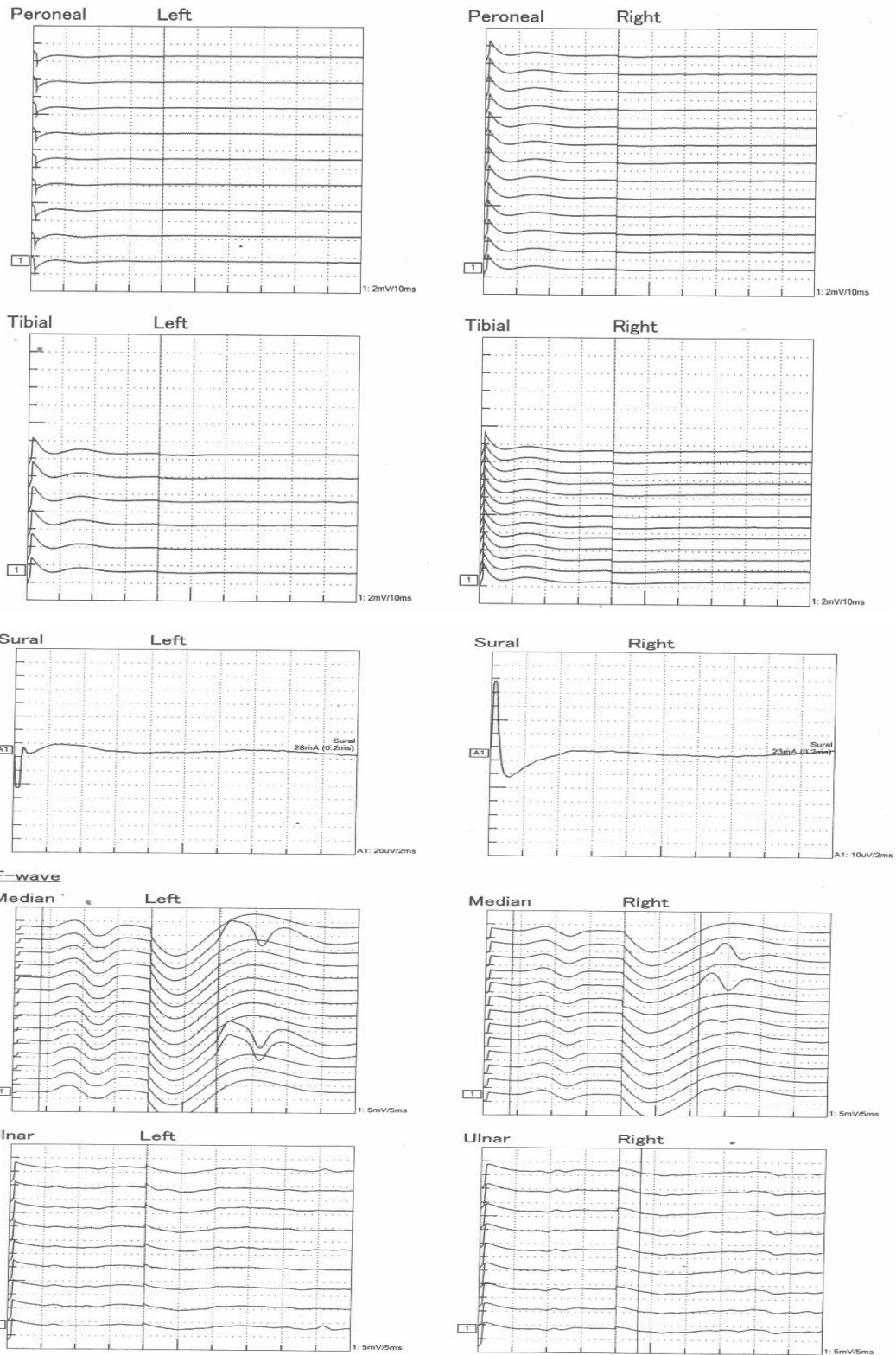
Site	Lat. (ms)	Dur. (ms)	Amp.	Area	Stim. (mA)	Segment	Dist. (mm)	Intvl. (ms)	NCV (m/s)
Median Left									
Wrist	5.0	5.2	3.2mV	10.3mVms	52.0	*Wrist		5.0	
Elbow	8.9	5.6	2.7mV	9.2mVms	52.0	Wrist-Elbow	240	4.0	60.6
						Elbow-Axilla			
Median Right									
Wrist	4.4	6.4	3.3mV	10.0mVms	52.0	*Wrist		4.4	
Elbow	8.6	5.7	2.2mV	6.1mVms	52.0	Wrist-Elbow	240	4.2	57.8
						Elbow-Axilla			
Ulnar Left									
Wrist	4.3	7.7	1.5mV	6.6mVms	50.0	*Wrist		4.3	
Elbow	10.2	5.1	0.7mV	1.6mVms	53.0	Wrist-Elbow	260	5.9	42.0
						Elbow-Axilla			
Ulnar Right									
Wrist	4.5	6.5	0.9mV	3.9mVms	50.0	*Wrist		4.5	
Elbow	9.4	5.7	0.3mV	0.9mVms	49.0	Wrist-Elbow	260	4.9	40.0
						Elbow-Axilla			
Peroneal Left									
Ankle	NR				50.0	*Ankle			
Head of fibula					50.0	Ankle-Head of fibula			
						Head of fibula-Popliteal			
Peroneal Right									
Ankle	NR				50.0	*Ankle			
Head of fibula					51.0	Ankle-Head of fibula			
						Head of fibula-Popliteal			
Tibial Left									
Ankle	NR				52.0	*Ankle			
Popliteal					50.0	Ankle-Popliteal			
Tibial Right									
Ankle	NR				53.0	*Ankle			
Popliteal					53.0	Ankle-Popliteal			

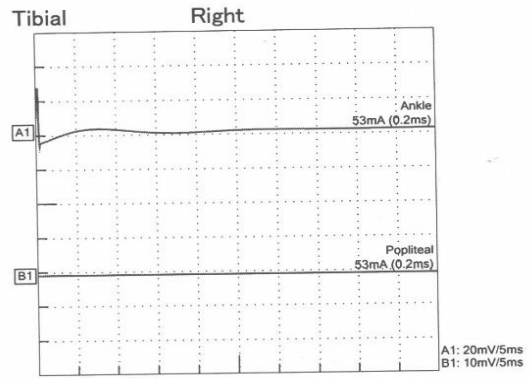
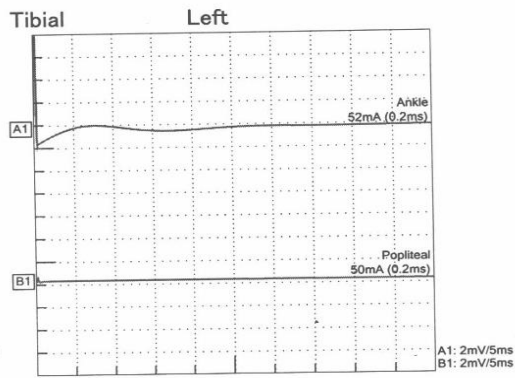
Sensory Nerve Conduction Study

Site	Lat.1 (ms)	Lat.2 (ms)	Amp.	Area	Stim. (mA)	Segment	Dist. (mm)	Intvl. (ms)	NCV (m/s)
Median Left									
Wrist	2.5	3.0	28.5uV	1.0uVms	32.0	Wrist	150	2.5	60.0
Median Right									
Wrist	2.5	3.1	27.7uV	1.2uVms	19.0	Wrist	150	2.5	59.1
Ulnar Left									
Wrist	2.4	3.0	21.1uV	0.9uVms	26.0	Wrist	150	2.4	63.0
Ulnar Right									
Wrist	2.5	3.0	18.2uV	0.5uVms	33.0	Wrist	130	2.5	52.0
Sural Left									
Sural	NR				28.0	Sural			
Sural Right									
Sural	NR				23.0	Sural			

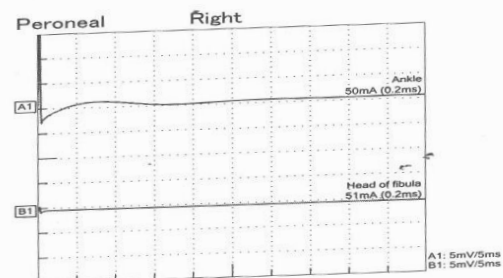
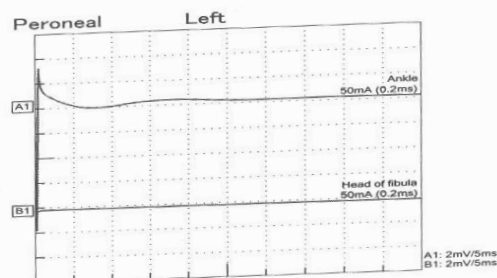
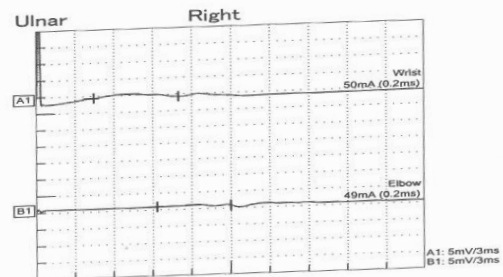
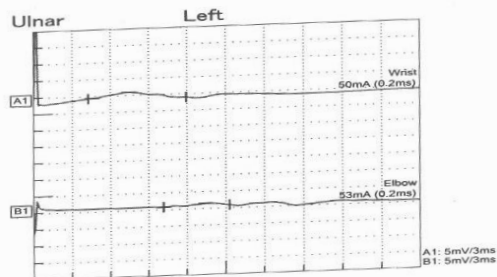
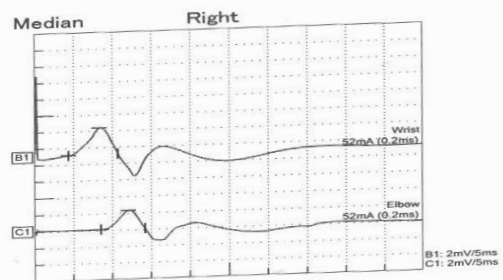
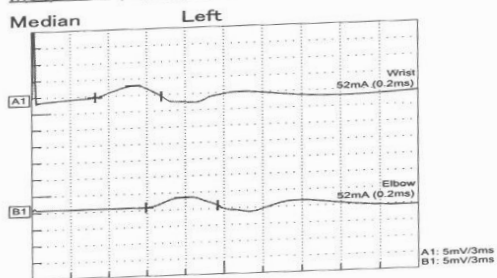
F-wave

Nerve	Side	Stim. Site	F-Lat.	M Lat.	F-M Lat.
Median	Left	Wrist	Imp	3.9ms	26.0ms
Median	Right	Wrist	Imp	3.9ms	27.1ms
Ulnar	Left	Wrist	NR	***	***
Ulnar	Right	Wrist	NR	***	***
Peroneal	Left	Ankle	NR	***	***
Peroneal	Right	Ankle	NR	***	***
Tibial	Left	Ankle	NR	***	***
Tibial	Right	Ankle	NR	***	***

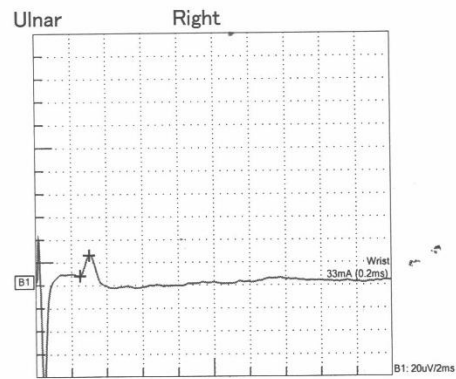
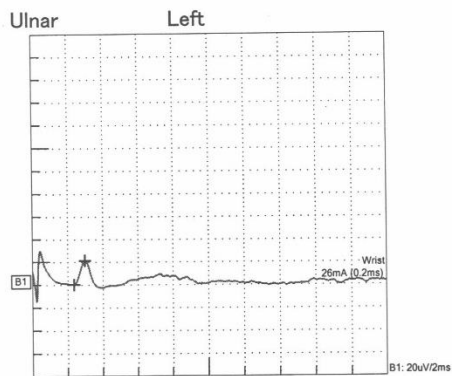
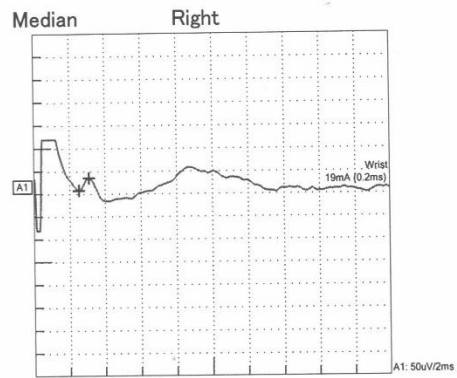
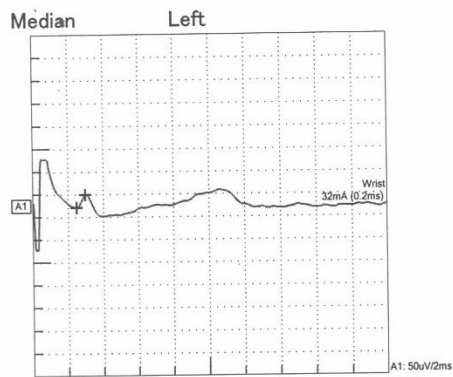




Motor Nerve Conduction Study



Sensory Nerve Conduction Study



CSF studies	
Cells	acellular
Sugar	69
Protein	34
OCB	negative

Remarks:

- a) NVS shows prolonged distal latency in median nerve
- b) Conduction block in ulnar nerve
- c) There is impersistent F-wave in the median nerve and all other F-waves are absent.

Discussion

Guillain barre syndrome is autoimmune inflammatory disorder of peripheral nerve and their root which present with progressive weakness and areflexia (1). Two-third of cases showed gives a preceding history of infective episode in form of loose stool or respiratory tract infection. Infection triggering the auto immune reaction has been found to be campylobacter jejuni, ebstein Barr virus and mycoplasma pneumonia most common among others. Gbs is usually considered as a monophasic illness, recurrence however has been observed in 2-6 % of patient. Diagnosis is made on the basis of clinical history of acute onset weakness with onset to peak in less than 4 weeks with nerve conduction studies suggestive of either demyelinating or sensorimotor neuropathy. Cerebrospinal fluid (Csf) study shows raised protein despite normal cells (albumino-cytological dissociation). Csf can be normal in initial stage of disease or in 5% of cases throughout the illness. Recurrent gbs (RGS) was defined by Kuitwaard as 1) two or more episodes of GBS fulfilling the diagnostic criteria with either minimal interval of 4 months between episodes if the patient did not recover completely (GBS disability scale ≥ 2) or ≥ 2 months when there was complete or near complete recovery (GBS disability ≤ 1) after the previous episode. RGS always needs to be differentiated form GBS treatment related fluctuation (TRF) and acute chronic inflammatory demyelinating polyneuropathy (CIDP).

Index case was diagnosed with gbs based on preceding history of infection followed by clinical worsening within 2 weeks along with Csf and neurophysiological findings. he responded to treatment well. His first and third attacks were more severe than second.

As per various studies incidence of RGS was 3-6 % (2-6). Relapse duration ranges between 2 months – 37 years in patients (2). Preceding infection has been same in same patient and successive patients in studies by moss berg et al, while they were different in same patient with successive episodes in Kuitwara et al. and grand maison F (2,3,5). The frequency of recurrence had a median of 3 episodes per patient, however 7 recurrent in a patient has been observed by Mossberg N. As per Das et al the severity of attacks is not related to number of recurrence (4). Both type of neuropathy has been observed in most of studies except by das et all in which demyelinating neuropathy was observed in all patients. Study published in 1992 features of miller fisher episodes were constant from episodes, in other cases facial bulbar and respiratory involvement varies considerably (6). Kuitwara et al stated that despite different types of preceding infection symptoms and signs were similar in every episode. The recurrent patient was younger more often had MFS and milder course of disease (2). Mossberg et al stated about 50 % of patient s had accumulated moderate neurological deficits in successive attacks and there was shorter time period from onset to peak in successive episodes. Clinical and

neurophysiological findings did not find any fundamental differences between RGS and GBS (3). Das et al reported that there seems to be a tendency to accumulate neurological deficit with increasing frequency of attacks of GBS and severity of attack not related to number in recurrences. Ivana Banta stated that a total 3.2% (13 of 404) of gbs patients had RGS. Patient had both kind of neuropathy on NCS studies, and 25% of patient had different variation on repeat attack on NCV studies (5).

Conclusion

Recurrent GBS always need to be differentiated form GBS-TRS and A-CIDP. There is consensus that each episode of RGS need to be treated as an isolated event, despite difference in preceding infection or type of neurophysiological findings and clinical subtype there is no consensus at present for exact etiology of this rare illness in a specific undefined group of people and any long term treatment after acute attack. Further a biochemical or immunological marker may help in distinguishing the illness.

Reference

- 1) Kuwabara S. Guillain-barré syndrome. *Drugs*. 2004 Mar;64(6):597-610.
- 2) Kuitwaard K, van Koningsveld R, Ruts L, Jacobs BC, van Doorn PA. Recurrent Guillain–Barré syndrome. *Journal of Neurology, Neurosurgery & Psychiatry*. 2009 Jan 1;80(1):56-9.
- 3) Mossberg N, Nordin M, Movitz C, Nilsson S, Hellstrand K, Bergström T, Andersson B, Andersen O. The recurrent Guillain–Barré syndrome: a long-term population-based study. *Acta Neurologica Scandinavica*. 2012 Sep;126(3):154-61.
- 4) Das A, Kalita J, Misra UK. Recurrent Guillain Barre's syndrome. *Electromyography and clinical neurophysiology*. 2004 Mar 1;44(2):95-102.
- 5) Basta I, Bozovic I, Berisavac I, Stojiljkovic-Tamas O, Rajic SL, Dominovic-Kovacevic A, Stojanov A, Djordjevic G, Jovanovic D, Peric S. Recurrent Guillain-Barré syndrome–case series. *Neurology India*. 2019 Nov 1;67(6):1536.
- 6) Grand' Maison F, Feasby TE, Hahn AF, Koopman WJ. Recurrent Guillain-Barré syndrome: clinical and laboratory features. *Brain*. 1992 Aug 1;115(4):1093-106.