



Case Report

Journal of MAR Gynecology (Volume 3 Issue 1)

Complicated (ruptured) Malignant Ovarian Yolk Sac Tumor in a 7-Year-Old female: A Rare Case Report and Literature Review

Yasmine El-Masry¹, MD, Ayman EL-Dorf¹, MD & Ahmed M.E Ossman¹, MD.

1. Obstetrics and Gynaecology department, Faculty of Medicine, Tanta University, Tanta, Egypt.

Corresponding Author: Yasmine El-Masry, Obstetrics and Gynecology Department, Vilnius University.

Copy Right: © 2022 Yasmine El-Masry, This is an open access article distributed under the Creative Commons Attribution License, which permits unrestricted use, distribution, and reproduction in any medium, provided the original work is properly cited.

Received Date: April 30, 2022

Published Date: May 10, 2022

Abstract

Ovarian neoplasms in pediatrics are rare with incidence of 2.6/100,000 girls/year, also ovarian malignancy is even rarer. Mixed germ cell malignancy is relatively rare in the pre-pubertal age group, unlike adult females, the epithelial neoplasms are most common, germ cell tumors (GCT) are the most common tumor in childhood. They account for 3% of pediatric cancers. Yolk sac tumor (YST) often presents in young women with the ages between 18-30 years old; ~33% of YST patients are premenarchal.

YST is highly malignant rapidly growing with a very short duration of symptoms which metastasizes fast and intrudes all intra-abdominal structures and retroperitoneal lymph nodes. YST was life-threatening worldwide before the combination chemotherapy administration. With the introduction of novel chemotherapeutic regimens in the end of 1970s, the 5-year survival rates of YST significantly improved from 14% to nearly 90%. The treatment generally involves debulking surgery of tumors followed by systemic chemotherapy, which improved the survival rates dramatically and fertility preserving surgery has become possible.

Our case highlights the importance of YST in pediatrics, and we provided our valuable experiences in the approaches of diagnosis and, management of a rare complicated case of YST in 7 years old girl. So, it is important to investigate more thoroughly a patient with history of intermittent abdominal pain and fever, as these might be the critical signs for YST that should not be neglected in order to treat the patient earlier. Although YST is rare in children, pediatric physicians should be still aware of this as it can be fatal and prompt treatment should be addressed. In this study, we described a rare case of YST in a 7-year-old girl in terms of the clinical presentation, imaging findings, diagnosis, and treatment.

Key words; *yolk sac tumor, alpha fetoprotein, pediatric, germ cell tumor, tumor markers, chemotherapy.*

Introduction

Ovarian Germ cell tumors (OGCT) constitute 20-25% of all ovarian neoplasms and of these only 3% are malignant. Only 1~2% of OGCTs are malignant called malignant ovarian germ cell tumors (MOGCTs) and constitute around 3-5% of all malignant ovarian neoplasms. The aged adjusted incidence of ovarian malignancy was 0.1/100.000 girl/year in girls < 9 years. The incidence frequency of OGCT in the pediatrics is considered to be the highest one (58-70%) if compared with the other pediatric ovarian tumors. YST accounting the 2nd most common tumor in MOGCTs is rare and typically occurs in gonads. However, in 1st two decades of life 70% ovarian tumors are germ cell in origin & one-third are malignant. They originate from the primitive germ cell and gradually differentiate to mimic tissues of either the embryonic origin like ectoderm, endoderm & mesoderm or of the extraembryonic tissues like the yolk sac and trophoblast. [1-3]. Diagnosis is often done by post-operative pathological examination. YST are one of highly malignant GCT, it was 1st described by Teilmum in 1976. Optimal management includes surgery (most commonly unilateral salpingo-opherctomy) followed by administration of platinum- based multi-agent chemotherapy regimen. However, prognosis is relative unfavorable compared with other GCTS histological subtypes. With the introduction of novel chemotherapeutic regimens in the end of 1970s, the 5-year survival rates of YST significantly improved from 14% to nearly 90%. Therefore, YST is rare in children and malignant; however, it could be cured usually. (4-9)

Case Presentation

A 7-year-old pre-pubertal girl was brought to the Outpatient Department of Obstetrics and Gynecology, Medical College and Hospital, Tanta University, with complaints of lower abdominal pain since 3 months. The pain had increased dramatically over the last 2 days and was associated with a sense of bloating and weight loss. There was a history of vomiting, constipation and fever, but no vaginal bleeding. The weight and height of the patient were 20 kg and 114 cm respectively. Breast and pubic hair belonged to Tanner stage 1. There was sever pallor, jaundice and palpable lymph nodes.

On physical examination, lower abdomen tenderness, muscle guard and huge swelling in right lower abdomen was felt and pale looking were noted. The vital signs of the female child were unstable, tachycardia (110 beat/min), tachypnea, and hypotension 90/60 mm hg. Urgent resuscitation was done for her. Urgent imaging in form of ultrasound & CT on abdomen and pelvis.

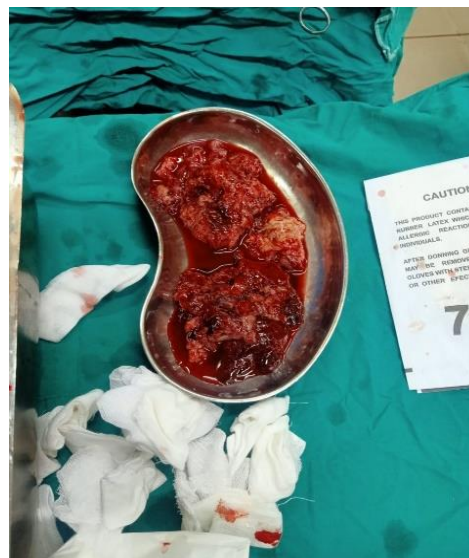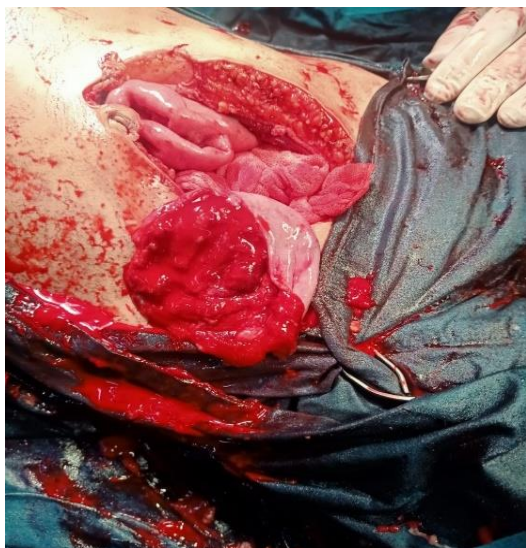Full blood investigations were done for the female child and revealed sever anemia and assay for ovarian tumor markers, alpha fetoprotein, CA125, CEA, lactic dehydrogenase, LDH, B subunit of HCG. The Computed tomography (CT) revealed showed a marked bloody (on aspiration) ascites over right sub-hepatic and lower abdominal area & large midline highly vascular pelvic mass 10 x 8 cm was seen showing intense enhancement in the arterial phase with progressive enhancement in the venous phase.

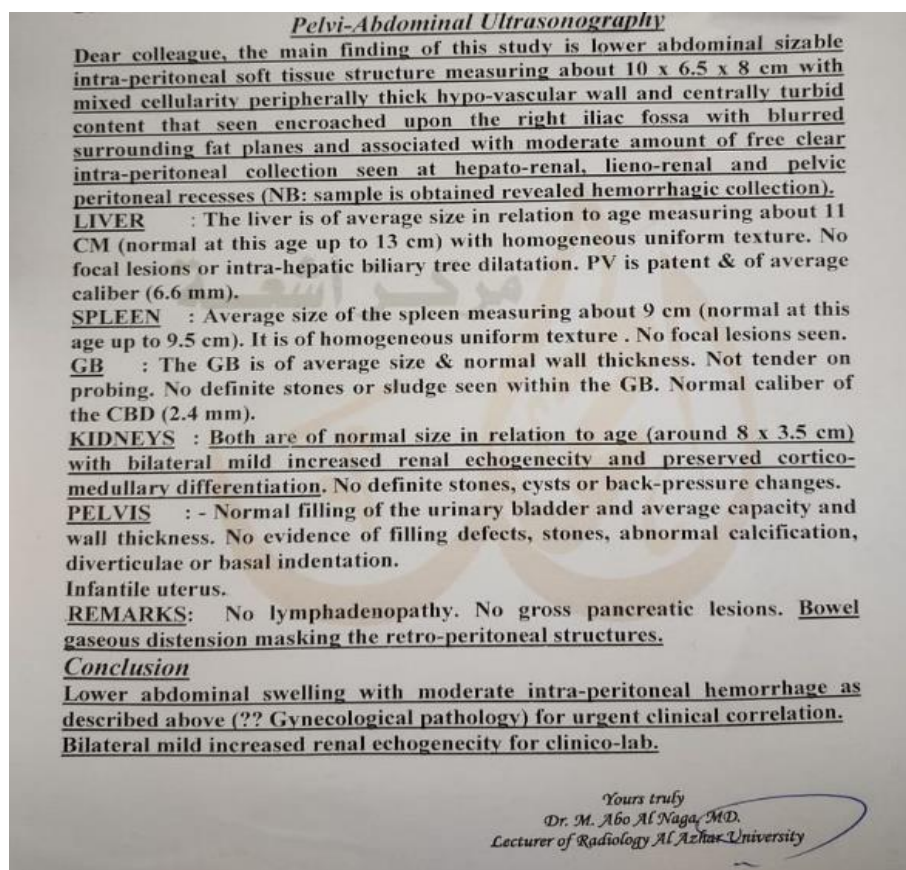
Pelvi- abdominal U/S showed a large pelvic mass, measuring 10 × 15 × 8 cm in size with internal heterogeneity and gynecological origin (ovary or uterus), with thick hypo-vascular wall and turbid content and moderate amount of free fluid in Morrison pouch (sample was obtained revealed hemorrhagic collection).

There was no family history of gynecological cancers. The clinical diagnosis was pelvic mass, possibly neoplastic in nature. The values of tumor markers, alpha-fetoprotein (AFP), CA125, beta human chorionic gonadotropin (hCG) and lactic dehydrogenase (LDH) were as shown in the following table;

Tumor markers	Values'	Normal levels
CA-125	53 U/ml	< 35 U/ml
B-HCG	< 1.2 mIU/ml	< 5 mIU/ ml
AFP	6000 ng/ml	<50 ng/ml
LDH	75 u/1	< 250 u/1

On surgical exploration under general anesthesia, mid-line exploratory incision was made and marked hemorrhagic intraperitoneal free fluid was found and aspirated (as shown in the images 1& 2).





Images of huge ruptured right hemorrhagic adnexal mass, and its mixed hemorrhagic contents during urgent abdominal exploration of young (7 years old) female patient. And the scanned image of her pre-operative pelvi-abdominal ultrasound, which is showing huge complicated adnexal mass and moderate free fluid which was hemorrhagic on aspiration.

The tumor was at the central pelvic cavity, arising from the right ovary, large high vascular adnexal mass with mixed consistency and the capsule was ruptured recently and some content was out of the cyst, also there was areas of necrosis and hemorrhage and degeneration inside the cystic mass as shown in the previous images

Uterus, right tube and ovary were apparently healthy. Other visceral organs appeared to be free from metastasis. Provisional surgical staging was IIIC. Adhesiolysis was done by blunt and sharp dissection. Unilateral salpingo-oophorectomy was done. Considering the age of the patient, uterus with contralateral tube and ovary were preserved. There was no other mass in the pelvis and the nearby organs were free, thus right salpingo-oophorectomy was done and control of bleeding and biopsy was taken from left ovary, and all sent for histopathological examination and intra-abdominal drain was inserted.

The patient was transferred to ICU postoperative, for follow up and she received 3 whole blood units and 1 plasma unit there. Drain output was about 350 ml of hemorrhagic fluid in the 1st 2 days, which gradually decreased and the drain omitted on the 4th postoperative day. She was discharged 5 days after operation and recovered well. Stitches were removed on the 10th postoperative day.

Outcome and follow up

Gross examination of the specimen submitted for pathology showed grayish brown spongy, fleshy, membranous and fatty fragments admixed with blood clots).Microscopic picture showed micro and microcytic pattern with solid, glandular and papillary pattern, extensive vascular invasion was observed, no other germ cell components were observed in the specimen and the hemorrhagic ascetic fluid cytology was positive for malignant cells as rupture of the tumor capsule .The findings were consistent with YST.

The patient was then referred to the oncologist for further treatment and under stringent follow-up. The female child was sent the national institute of oncology in Cairo for further investigations & management. She was planned for four cycles of adjuvant chemotherapy (BEP regimen) and is under follow-up until now and generally become better as regards her general condition and laboratory investigations and tumor markers levels.

Discussion

The aged adjusted incidence of ovarian malignancy was 0.1/100.000 girl/year in girls < 9 years. YST is a rare tumor of childhood, which account for ~3.5% of all childhood cancers (<15 years) and usually arises in gonads, testis or ovary, thus a type of germ cell tumor. The incidence between the ages 15 and 19 rises to 16%. Approximately one-third are extra-gonadal origins, such as vagina, mediastinum, pineal gland, cervix, endometrium, and sacrococcygeal area. It has also been reported that YST occurred in urachus, stomach, liver, lungs, heart, thyroid, nasal region, cranial base, vulva, retroperitoneum, prostate, pericardium, diaphragm, mesentery, mouth, ears, omentum, eyes, and subcutaneous region (10-13).YST is a rare tumor of ovary, contribute for < 0.2% of all ovarian tumors.(6).

Only one third of YST are found in the prepubertal age group which corresponds to our case where the patient's age was seven years. As per treatment protocol, fertility preservation is a priority in prepubertal and young girls. These lesions are best managed by fertility preserving surgery (i.e. unilateral salpingo-oophorectomy in this case as YST are unilateral in 100% cases and it forms the main component). (12-14)

The exact pathogenesis of YST remains obscure. However, some studies propose that it occurs from malignant transformation of misplaced germ cells. During the 4–6th week of embryogenesis, germ cells migrate laterally between the embryonic ectoderm and endoderm; GCT can arise anywhere along the

migration from the mesoderm to the future cranial area. Although the pathogenesis of extra-gonadal GCT is unclear, two possible explanations were proposed: mis-integration of germ cells during development of embryo and distribution of germ cells to other organs. So, more research is required for investigating the mechanism of pathogenesis for effective management of YST. (5-6)

YST are germ cell tumors that are highly malignant, was first described by Teilum in 1976. Most of YST are unilateral and rapidly growing tumors, so duration of clinical picture is short. It has been suggested that alpha-fetoprotein (AFP) can be applied as a feasible tumor marker because its level was elevated in >90% of YST. According to the scheme characterized by Teilum, a germinoma would develop if there is no differentiation; with differentiation, embryonal carcinoma would develop and with extraembryonic differentiation, a yolk sac tumor or a choriocarcinoma [2].

Diagnosis includes the following; Clinical presentations of patient-General and local examinations-Imaging; U/s on abdomen & pelvis-X-ray chest, contrast enhanced CT on abdomen & pelvis – CT chest. Laboratory investigations and serum assay of tumor markers, AFP, LDH, B-HCG.

As regard clinical, abdominal pain is the principal symptom leading the discovery of the disease which may require the emergency surgery especially in cases of ovarian torsion. They have various clinical presentations most common being subacute pelvic pain and feeling of lump but sometimes high-grade fever can be one of the rare presentations. (1) Other symptoms are the presence of an abdominal or pelvic mass with abdominal enlargement, vaginal bleeding, fever, ascites or peritonitis secondary to torsion, infection or rupture of the ovarian tumor [3-6]

Pathology Of Yolk Sac Tumor

It is almost always unilateral and large with a diameter that may vary from 5 to 50 cm (median 15 to 19 cm). The typical neoplasm manifest as a large complex pelvic mass that extends into the abdomen. This tumor is often characterized by extremely rapid growth and extensive intra-abdominal spreading with poor prognosis [8-9].

Nishio et al have reported the type of surgical procedure not to be an important prognostic factor for patients with MOGCTs at all clinical stages, thereby indicating conservative and fertility sparing surgery to be appropriate along with adjuvant chemotherapy. Thus, even in patients with bulky metastases, a normal appearing uterus and contralateral ovary can be safely preserved allowing for future fertility [5-7]. In particular, a postoperative AFP level of >1,000 ng/ml could serve as a prognostic indicator for the ovarian YST patients. However, the studies suggest a slight increase in AFP should not be applied as the sole criterion for chemotherapy decision. (9-12).

Staging Of YST

YST, though rare, is the 2nd commonest histopathological subtype of malignant OGCT after dysgerminoma. Pre-operative diagnosis is difficult, as YST do not have a specific radiological image. These tumors can appear cystic with signs of hyper vascularization and areas of hemorrhage.

YST is highly malignant growing rapidly with a very short duration of symptoms which metastasizes fast and intrudes all intra-abdominal structures and retroperitoneal lymph nodes. YST was universally life-threatening before the development of combination chemotherapy. All patients except those with FIGO stage 1A require combination chemotherapy. This is usually followed by four cycles of adjuvant combination chemotherapy, preferably BEP (Bleomycin, Etoposide and Cisplatin) regimen. The most important prognostic factors in these cases are size of primary tumour and relative size of its most malignant component. For Stage IA lesions less than 10 cm, survival is 100%. (6, 11)

Diagnosis is often done by post-operative pathological examination. YST are one of highly malignant GCT, it was 1st described by Teilum in 1976. YST most frequently occur in 2nd & 3rd decade of life. Some are bilateral, while mostly are unilateral. They are rapidly growing, so short duration for clinical pictures to appear. (3, 4,6)

The Staging of OGCT

The American Joint Committee on Cancer (AJCC) have designated staging for ovarian germ cell tumors. [6-9]

Stage I; - Stage I ovarian germ cell cancer is growth limited to the ovaries.

Stage IA: Tumor is limited to ovary; capsule is intact, and no tumor is present on the ovarian surface. No malignant cells are present in ascites or peritoneal washings.

Stage IB: Tumor is limited to both ovaries; capsules are intact, no tumor is present on the ovarian surface. No malignant cells are present in ascites or peritoneal washings.

Stage IC: Tumor is limited to one or both ovaries with any of the following: Capsule is ruptured-Tumor is present on the ovarian surface -Malignant cells are present in ascites or peritoneal washings.-Note: Malignant ascites is not classified. The presence of ascites does not affect staging unless malignant cells are present

Stage II; Stage II ovarian germ cell cancer is growth involving one or both ovaries with pelvic extension and/or implants.

Stage IIA: Extension and/or implants are present on the uterus and/or fallopian tubes. No malignant cells are present in ascites or peritoneal washings.

Stage IIB: Extension to and/or implants are present on other pelvic tissues. No malignant cells are present in ascites or peritoneal washings.

Stage IIC: Pelvic extension and/or implants (stage IIA or stage IIB) with malignant cells are present in ascites or peritoneal washing. Different criteria for designating cases to stages IC and IIC have an impact on the diagnoses. To evaluate the impact of the differing criteria, determine if rupture of the capsule was the result of any of the following possibilities:- A spontaneous rupture- A rupture caused by the surgeon. It is also important to determine if the source of the malignant cells detected was the result of either of the following: Peritoneal washings-ascites.(9-10)

Stage III; ovarian germ cell cancer is growth involving one or both ovaries with microscopically confirmed peritoneal implants outside the pelvis. Superficial liver metastasis equals stage III. Tumor is limited to the true pelvis but with histologically verified malignant extension to the small bowel or omentum.

Stage IIIA: Microscopic peritoneal metastasis is present beyond the pelvis (no macroscopic tumor).

Stage IIIB: Macroscopic peritoneal metastasis is present beyond the pelvis and is 2 cm or smaller in greatest dimension.

Stage IIIC: Peritoneal metastasis is present beyond the pelvis and is larger than 2 cm in greatest dimension, and/or regional lymph node metastasis is present

Stage IV; ovarian germ cell cancer is growth involving one or both ovaries with distant metastasis. If pleural effusion is present, there must be positive cytological test results to designate a case to stage IV. Parenchymal liver metastasis equals stage IV [6].

Grading Of OGCT

An ovarian tumor can also be described by grade (G), which is how similar the tumor is to normal tissue. Tumor grade is determined by examining the tumor tissue under a microscope. Cells that appear healthy are called well-differentiated. In general, the more differentiated the ovarian tumor, the better the prognosis.

GX: The grade cannot be evaluated.

GB: The tissue is considered borderline cancerous.

G1: The tissue is well-differentiated (contains many healthy-looking cells).

G2: The tissue is moderately differentiated (more cells appear abnormal than healthy).

G3 to G4: The tissue is poorly differentiated or undifferentiated [7-10].

Investigation of O-YST#####

U/S is the 1st line imaging modality for assessing ovarian neoplasms. It is favor for malignancy if large size more than 8-10 cm & presence of solid components. An annual pelvic U/S is recommended in cases with conservative surgery in order to screen for a contralateral recurrence [3]. Magnetic resonance imaging (MRI) is so useful in making a preoperative diagnosis of YST and distinguishing YST from other malignant ovarian tumors. The final diagnosis of YST is usually confirmed following pathologic examination after surgery (9-12)

Tumor markers can be useful in diagnosis as well as to monitor treatment and for post-operative follow up, including B-HCG, AFP, LDH (lactic dehydrogenase) & inhibin are positive in 54-83% of malignant cases. Follow-up of these patients includes determining if there is an initially elevated AFP level and repeating it before each cycle of therapy, soon after the end of the treatment and during the 2 years after the end of chemotherapy. (7)

Alpha fetoprotein is a specific marker, the association of an adnexal mass and an elevated AFP level is specific of a vitelline component, permitting to raise diagnosis with quasi-certainty even before histological proof, and therefore to orientate surgical procedure in young women. Schiller-Duval bodies are cellular structures that resemble fetal glomerulus, pathognomonic of endodermal tissue. High values of AFP orientate strongly to diagnosis of YST. Furthermore, it is a sensible marker for tumor's evolution; in fact a rapid decrease of AFP levels in the serum after surgery is a sign of absence of residual tumor. Also the efficiency of chemotherapy it's related with normalization of AFP [7,8].

Management of O-YST

Treatment of YST, they are treated effectively with a combination of surgery and chemotherapy. BEP therapy & infertility –conservative surgery is the gold standard long remission & successful pregnancy. AFP is useful marker for follow up of cases for response to chemotherapies', AFP declines to normal level within 1st 8-10 months, some cases not until the end of 2nd year of life. Follow-up; consist of clinical presentations imaging & level of AFP. (8-11)

Primary conservative surgery with comprehensive staging laparotomy and surgical cyto-reduction of advanced disease, followed by prompt institution of adjuvant cisplatin-based combination chemotherapy have resulted in high cure rates in this disease. The role of laparotomy for post chemotherapy residue in ovarian germ cell tumors is in a state of evolution. The type of operative procedure in this setting is dictated by initial disease status, histology and operative findings, with fertility preservation always considered a desirable end point. In the studies about second look laparotomy for OGCT, the patients who had initial complete resection of the tumor, with no teratomatous element and clinically no post-

chemotherapy residue with normal tumor markers were not found to benefit from the procedure [12-15].

Surgery, before, treated this neoplasm as adenocarcinoma (extensive surgery: hysterectomy, adnexectomy, omentectomy and lymphadenectomy), it's no more the case since 1976, when it was proven that adnexectomy was equivalent to extensive surgery in patients with stage I yolk sac tumors, the studies including series of ovarian YST had shown equivalent results after adnexectomy compared to more aggressive surgery. Furthermore, YST metastasizes through the hematogenous route in >50% of the pediatric patients in comparison with only 4–6% of the adult patients. This fact modifies the therapeutic strategy. Thus, Retroperitoneal Lymph Node Dissection (RPLND) would not be the appropriate treatment for pediatric patients. Systemic lymphadenectomy does not seem to improve the five-year survival rate [4, 7-9]

Whereas among pediatric oncologists, (O-YST) is considered a chemo-sensitive tumor, it is often cited as an adverse prognostic factor in adult women with ovarian germ cell tumors. Optimal management includes surgery (most commonly unilateral salpingo-opherctomy) followed by administration of platinum- based multi-agent chemotherapy regimen. However, prognosis is relative unfavorable compared with other GCTS histological subtypes. (6-7)

Both national cancer network & European society of medical oncology (EMO) clinical guidelines recommend the administration of multi-agents adjuvant chemotherapy for any stage of OYT. Currently, BEP regimen has become standard of care for all MOGCT including OYST. O-YST have an excellent outcome across all age-groups. It has been suggested that AFP can be applied as a feasible tumor marker because its level was elevated in >90% of YST. The national comprehensive cancer network (2016) recommends that patients who completed clinical course are monitored by AFP every 2~4 months for 2 years after treatment. Also, response to chemotherapy could be assessed by the AFP level (9-11,16, 17).

Age has no apparent impact on the probability of event or death, allowing pediatric and gynecologic oncologists to enroll patients onto joint pediatric and adult trials . This paper presents the clinical picture, course, the diagnostic-therapeutic procedure and outcome of the disease in a 7 year old pre-pubertal girl with a complicated malignant germ cell tumor (endodermal sinus tumor) of the right ovary. chemotherapy has dramatically changed the prognosis of these malignancies; the five-year survival rate has increased from 14% to nearly 90%, various studies has proven the efficacy of BEP protocol in ovarian germ cells tumors with a five-year survival rate of 94% (all stages considered) [4,7-9].

Optimal management includes surgery (most commonly unilateral salpingo- opherctomy) followed by administration of platinum- based multi-agent chemotherapy regimen. However, prognosis is relative unfavorable compared with other GCTS histological subtypes. (6, 12, 14) Fertility sparing surgery can be safely persuaded while omentectomy & lymphadenectomy could be potentially omitted when staging these tumors. (9,13,16)

Neoadjuvant chemotherapy could be considered for the patients having extensive intra-abdominal disorders when initial surgical debulking is not preferred. Chemotherapy is suggested for treating recurrence (10,16,17).

Retroperitoneal Lymph Node Dissection (RPLND) would not be the appropriate treatment for pediatric patients and complications such as wound infection, atelectasis, and pulmonary insufficiency secondary to bleomycin-induced interstitial fibrosis, chylous ascities and small bowel obstruction (11-17). BEP chemotherapy is considered as a gold-standard 1ST line treatment for GCT at all stages. An important issue to consider for treating young patients is to reserve fertility by using fertility sparing strategy, and it is possible to achieve because most tumors are unilateral. (9,14,16)

Our case highlights the importance of YST in children, and we provided our valuable experiences in the approaches of diagnosis and treatment for YST in children. So, it is important to investigate more thoroughly a patient with history of intermittent abdominal pain and fever with previously multiple accesses, because these might be the critical signs for YST that should not be neglected in order to treat the patient earlier. Although YST is rare in children, pediatric physicians should be still aware of this as it can be fatal and prompt treatment should be addressed. In this study, we described a rare case of YST in a 7-year-old girl in terms of the clinical presentation, imaging findings, diagnosis, treatment and follow up of the case.

Conclusion

It is importance to raise awareness especially in parents of pediatric patients, about the importance of an early diagnosis of ovarian tumors - that treated in stage I could lead to a 5-year survival rate of more than 95%. Alpha-fetoprotein is a crucial tumor marker in the diagnosis and especially in the follow-up of yolk sac tumors, being a predictive factor of residual malignant tissue and of recurrence. Adjuvant chemotherapy should be used in 3-4 cycles of Bleomycin, Etoposide and Cisplatin (BEP) after surgical resection, to improve outcome and overall survival rate. Parents should be counselled and they need to understand that even if surgery was performed it is of great importance that the adjuvant chemotherapy should be followed thoroughly to minimize recurrence and increase the overall. YST of ovary requires early diagnosis and management. Neoadjuvant therapy can be considered in women with suspected stages 3 and 4 tumors in order to reduce tumor burden preoperatively, followed by tumor debulking while preserving at least the uterus or the contralateral ovary depending on the intraoperative findings.

References

1. Kojimahara T, Nakahar K, Takano T, Yaegashi N, Nishiyama H, Fujimori K et al. Yolk sac tumor of the Ovary: A retrospective multicenter study of 33 Japanese women by Tohoku Gynaecologic Cancer Unit (TGCU). *Tohoku J Exp Med.* 2013; 210:211-217.
2. Dallenbach P, Bonnefor H, Pelte MF, Vlastos G. Yolk sac tumors of the ovary: an update. *Eur J Surg Oncol.* 2006;32:1063-1075.
3. Guida M, Pignata S, Palumbo A R, Miele G, Marra ML, Visconti F et al. Laparoscopic treatment of a yolk sac tumor: case report and literature review. *Translational Med.* 2013;7(1):1-5.
4. Moniaga NC, Randall LM. Malignant mixed ovarian germ cell tumor with embryonal component. *J Pediatr Adolesc Gynecol.* 2011;24(1):e1-e3. oi:10.1016/j.jpag.2010.05.001.
5. Nishio S, Ushijima K, Fukui A, et al. Fertility-preserving treatment for patients with malignant germ cell tumors of the ovary. *J Obstet Gynaecol Res.* 2006;32:416.
6. Kurman RJ, Norris HJ. Endodermal sinus tumor of the ovary: a clinical and pathologic analysis of 71 cases. *Cancer.* 1976;38(6):2404-19.
7. Ovary. In: American Joint Committee on Cancer: AJCC Cancer Staging Manual. 6th ed. New York, NY: Springer, 2010, pp 275-284.
8. Kehila M , Skhiri R , Boughizane S , Fekih M , Kebaili S , Rameh S , Agina M , Khairi H . Yolk sac tumor revealed by an ascite of great abundance .*J Gynecol Obstet Biol Reprod (Paris)* . 2009 Oct ; 38 (6) : 516 – 20 . Epub 2009 May 28. [PubMed] [Google Scholar]
9. Lu KH , Gershenson DM . Update on the management of ovarian germ cell tumors *J Reprod Med.* 2005 June; 50 (6) : 417 – 25 . Review. [PubMed] [Google Scholar].
10. Eddaoualline H, Sami H, Rais H, Belbaraka R, El Omrani A, Khouchani M. Ovarian Yolk sac tumor: a case report and literature review. *Clin Case Rep Int.* (2018) 2:1057
11. Guida M, Pignata S, Palumbo AR, Miele G, Marra ML, Visconti F, et al. Laparoscopic treatment of a Yolk Sac Tumor: case report and literature review. *Transl Med UniSa.* (2013) 7:1–5.
12. Telium G . Endodermal sinus tumors of the ovary and testis. Comparative morphogenesis of the so called mesonephroma ovarii (Shiller) and extraembryonic (yolk sac allantoic) structure of the rat's placenta . *Cancer* . 1959 Nov-Dec; 12 : 1092 – 105 .
13. Beurdeley M , Gauthier T , Piguët C , Fourcade L . Conservative treatment of big yolk sac tumour of the ovary in young girl . *J Visc Surg* . 2010 Aug ; 147 (4) : e265 – 7.

14. Prat J; FIGO Committee on Gynecologic Oncology. Staging classification for cancer of the ovary, fallopian tube, and peritoneum. *Int J Gynaecol Obstet* 2014;124(1):1-5.
15. Talerman A. Germ cell tumors of the ovary. *Curr Opin Obstet Gynecol* 1997; 9(1):44-7.
16. Gershenson DM, Del Junco G, Copeland LJ, Rutledge FN. Mixed germ cell tumors of the ovary. *Obstet Gynecol* 1984;64(2):200-6.
17. de la Motte Rouge T, Pautier P, Rey A, Duvillard P, Kerbrat P, Troalen F, et al. Prognostic factors in women treated for ovarian yolk sac tumor: A retrospective analysis of 84 cases. *Eur J Cancer*. 2011; 47(2):175-82