



Ca 19-9 in Ovarian Pathology: Should it be Taken Seriously?

Dr. Rahul Manchanda ¹, Dr. Apoorva Dave ^{2*}

1. Head of the Department, Department of Gynae Endoscopy, PSRI and Holy Family Hospital, New Delhi.
2. Attending consultant, Department of Gynae Endoscopy, PSRI, New Delhi.

Corresponding Author: Dr. Apoorva Dave, Attending consultant, Department of Gynae Endoscopy, PSRI, New Delhi.

Copy Right: © 2022 Enric Güell Penas, This is an open access article distributed under the Creative Commons Attribution License, which permits unrestricted use, distribution, and reproduction in any medium, provided the original work is properly cited.

Received Date: September 19, 2022

Published Date: October 01, 2022

Abstract

Introduction:

We aimed to identify clinical characteristics of Ovarian pathologies in association with CA19-9 elevation encountered in our gynaecology department, and to determine if CA19-9 should be of any significance in gynaecology practice.

Methods: *We present a series of three cases of benign ovarian pathologies and their presentation in gynaecology OPD and association of tumour markers such as elevated CA19-9. Also we have reviewed the various case reports on association of elevated CA19-9 levels and its association with ovarian pathologies and discussed them in detail.*

Results: *We report a series of three cases encountered in our gynaecology department with benign ovarian pathologies associated with elevated CA 19-9 levels and we discuss the management of these cases and post-operative diagnosis on the basis of operative findings and histopathology reports. All the three cases were unmarried girls and two out of three cases were diagnosed as bilateral mature cystic teratoma (MCT) and the third patient had endometrioma in the left ovary along with grade III endometriosis. Among the two cases of MCT, one had presented in emergency with acute pain abdomen and intraoperatively she was found to have torsion of the ovarian cyst as well as fallopian tube. To our knowledge, very few cases on association of CA 19-9 with benign ovarian pathologies have been reported in the literature.*

Conclusion: *CA19-9 could be an important tool in the diagnosis of benign gynaecological conditions such as ovarian mature cystic teratoma and endometrioma. Biomarkers such as CA19-9 might be useful in reducing the time lag between the diagnosis and initiation of treatment that could have been otherwise caused due to misinterpretation of the symptoms in young adolescents.*

Key words: *CA 19-9, CA 125, mature cystic teratoma, endometrioma, tumor marker.*

Introduction

In modern clinical practice tumor markers have gained great significance to ascertain the effectiveness of the therapy, to find out recurrence and to anticipate prognosis in known carcinomas. For the detection of ovarian cancer there are various tumor markers which include CA-125 antigen, carcinoembryonic antigen (CEA) and CA-15-3 antigen. However, for cancer screening the use of serum tumor markers is limited due to their low specificity [1].

Mucinous tumors of the gastrointestinal tract, including those of the pancreas and biliary tree secrete an antigen called CA-19-9, which is a monosialoganglioside [2]. Koprowski et al. first reported CA-19-9 antigen in the year 1981 [3]. Its levels can be raised in various conditions, both malignant as well as benign. According to Steinberg significantly raised levels of CA-19-9 antigen (greater than 1,000 U/mL) are associated with advanced stages of malignant conditions such as colorectal carcinoma, pancreatic adenocarcinoma and epithelial ovarian carcinoma [4]. Cho and Kyung [5] also stated that CA-19-9 was appreciably raised in malignant and borderline mucinous tumors than in benign ovarian tumors. Herein we aimed to present two cases with MCT and one with endometrioma and their clinical characteristics in association with elevation of CA19-9 levels, and to review the available literature to see if CA19-9 is a useful marker in benign ovarian pathology detection and its associated complications.

Aims and Objectives:

1. To report series of three cases with benign ovarian cyst and elevated CA 19-9.
2. To review the available literature on ovarian pathologies and elevated CA 19-9.

Material and Methods

In this Article we present a series of three cases with ovarian cysts having raised CA 19-9 levels and also we have reviewed various articles on MCT and endometrioma and its association with raised CA 19-9 levels. Review was undertaken by searching the data base using PubMed, Scopus, EMBASE, Web of Science, Science direct etc. The studies describing elevated CA 19-9 and its association with various benign gynaecological pathologies such as MCT and endometrioma were included in the present study. In MCT special attention was given on association of CA19-9 levels with its severity and associated complication, size of the tumour and bilaterality. We searched studies till January 2022.

The search strategy included keywords such as tumour marker, CA 19-9, CA 125, Mature cystic teratoma, MCT, dermoid cyst, Torsion, Adnexal Mass etc.

Result and Discussions:

Following are the cases with abnormally high CA 19-9 in association with benign ovarian pathology discussed in detail.

Case1

A 32-year-old adult was admitted to our clinic because of pelvic pain lasting for 1 week. Abdominopelvic ultrasonography revealed The right adnexa showed a well-defined cystic lesion measuring approx. 6.6 X 6.1 X 5.0 cm showing echogenic areas a non-dependent location and a dot and dash pattern of echoes within the cyst. Left adnexa shows another cystic lesion with fluid- fluid levels with hyperechoic component in dependent portion of the cyst. Findings were suggestive of bilateral benign cystic lesions – Teratomas.

Abdominopelvic MR revealed a 16 cm cystic lesion consisting of heterogeneous solid structures. The left ovary and other intra-abdominal structures were normal. Tumor markers were as follows: CEA: 1.90 U/mL, AFP: 0.94 U/mL, CA 15-3: 13.4 U/mL, CA 19.9: 141.2 U/mL, and CA 125: 12.37 U/mL. Another possible gastrointestinal system pathology was ruled out by imaging modalities. Diagnostic and operative laparoscopy with bilateral ovarian cystectomy was performed

Laparoscopic findings are as follows:

- Bilateral ovarian cyst right sided measuring 8 cm. X 7 cm. and left sided measuring 6cm. X 7 cm.
- Peritoneal fluid was taken and sent for cytology.
- Left ovary adhered to the abdominal wall.
- Frozen section sent intraoperatively for histopathology (HPE) revealed benign mature cystic teratoma.
- Bilateral ovarian cystectomy done keeping normal ovarian stroma preserved and cystectomy specimen sent for histopathology.

laparoscopic appearance is depicted in figure 1

Post-operative period was uneventful. Pathological evaluation was compatible with benign cystic teratoma, bilateral ovaries. Microscopic examination of right ovary revealed mixture of mature benign tissue of all the three germ layers. Component of ectoderm are squamous epithelium, sebaceous glands, hair follicle, conjunctival lining with pigment. Component of mesoderm are bone, cartilage, mature adipose tissue and components of endoderm are respiratory epithelium seen. No area of immature neuroepithelium seen.

Her postoperative CA 19-9 came down to 46.17 U/ml.

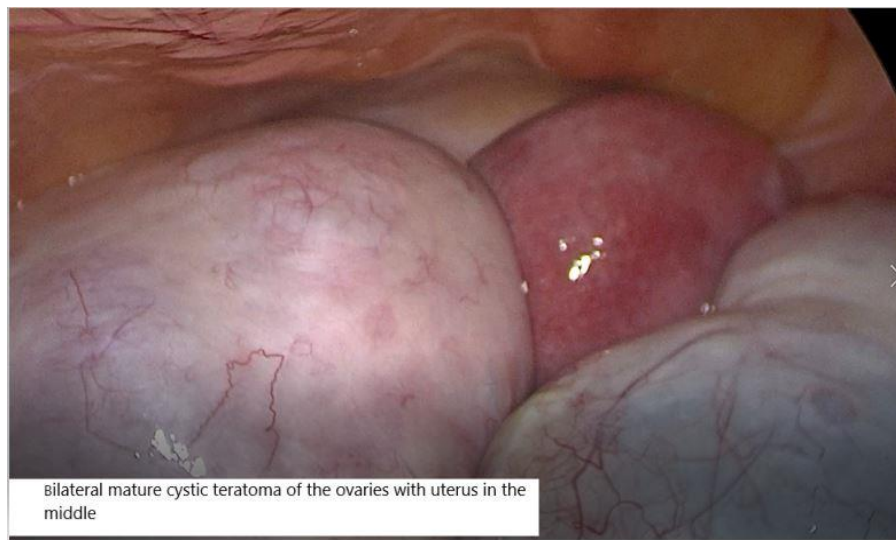


Figure 1: Bilateral mature cystic teratoma on laparoscopy in case 1.

Case 2

A 30-year-old unmarried girl was brought to our casualty with complaints of acute abdominal pain not relieved with medication. On abdominal examination there was tenderness on superficial palpation. Urgent ultrasound was done which revealed bilateral adnexal mass, right sided being 4.5cmX 4.5cm X 2.9 cm and volume 32.0 cc and Left adnexal mass measures approximately 5.0cm X5.0 cm X4.4 cm volume being 60 cc and is homogenously hyperechoic. with suspicion of torsion of left ovarian cyst with probe tenderness and minimal fluid in pouch of douglas noted on the ultrasound. Her Preoperative CA 19-9 levels were 884 U/ml and other tests were within normal limits. Then she was quickly taken up for emergency laparoscopy and bilateral cystectomy was done under general anaesthesia. Her intraoperative findings on laparoscopy were as follows:

- Left ovary along with dermoid cyst and the fallopian tube revealed torsion with two and a half twists, untwisting done. No necrosis or hemorrhage was noted.

- Left ovarian dermoid multilobulated cyst of around 14X 12 cm. noted and intact cyst removal was done in bag piecemeal to avoid spillage.
- Right ovarian bilobed dermoid cyst around 10cm. X 8 cm. removed keeping the capsule intact and specimen sent for histopathology and healthy ovarian tissues preserved.
- Adhesions present on right anterior uterine wall- adhesiolysis done.
- Clear fluid noted in pouch of douglas.

Figures 2, 3, 4 and 5 depict laparoscopic findings in case 2.

Post operatively her CA 19-9 levels came down to 255.12 U/ml. The post-operative period was uneventful. She was discharged the next day of the surgery.

Her histopathology report was compatible with benign cystic teratoma, bilateral ovaries. Microscopic examination revealed contents like skin and its appendages, respiratory mucosa with seromucinous glands, cartilage, benign glandular tissue, lymphoid aggregates and fat. No immature element identified.

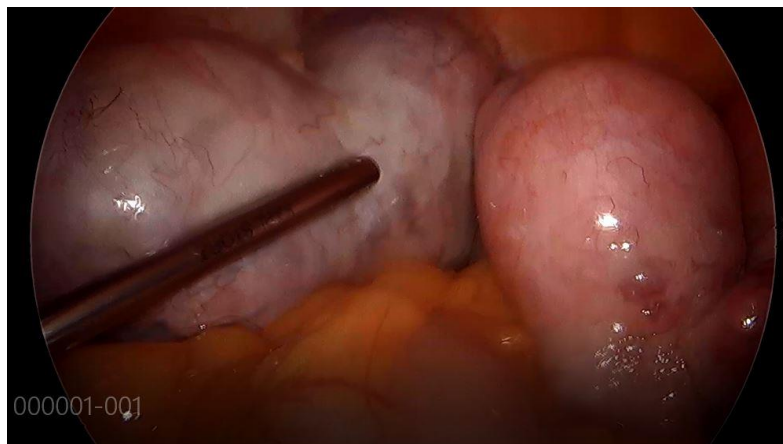


Figure 2: Bilateral mature cystic teratoma on laparoscopy in case 2.

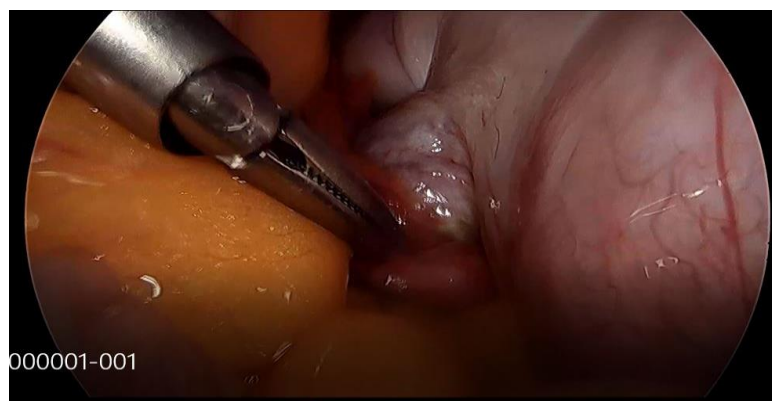


Figure 3: Twisted left ovarian cyst in case 2

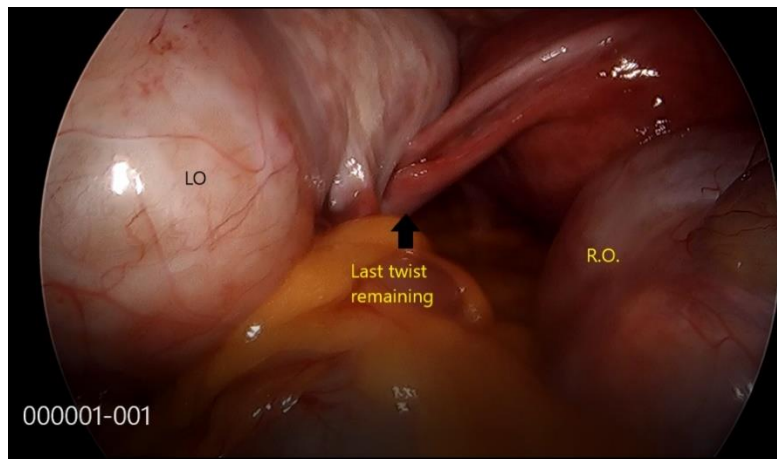


Figure 4: Twisted left fallopian tube in case 2.

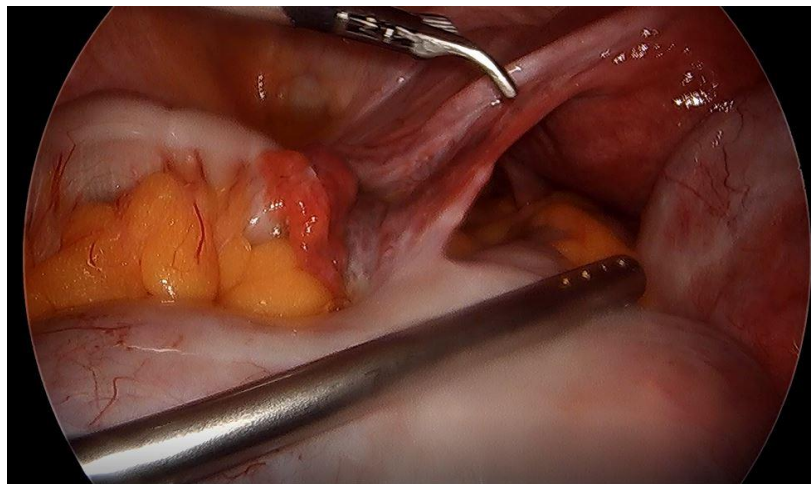


Figure 5: Left fallopian tube after untwisting in case 2.

Case 3

A 30-year-old unmarried girl presented to our clinic with history of heavy menstrual bleeding and pain abdomen for 1 year. Her ultrasound revealed Minimal subendometrial adenomyosis with endometrial thickness being 8.3mm with minimally tender left ovary containing 29X 26X 21mm. avascular cyst completely filled with low level internal echoes containing fluid- fluid debris level suggestive of endometriotic cyst. And her preoperative CA 19-9 was 481 and she was taken up for Hysteroscopy guided endometrial biopsy with Robotic endometriotic cystectomy with endometriotic ablation under General anaesthesia. Her intraoperative findings were as follows:

On robotic surgery:

- Endometriotic deposits present on posterior surface of uterus and on uterosacral ligaments which we ablated.
- Endometriotic nodules present on uterosacral ligament and the same excised.
- Left ovary showed endometriotic cyst of around 2.0cm. X 2.5cm., cystectomy done and specimen sent for histopathology.
- Left tube adherent to the left ovary – was released
- Right tube and ovary normal.

Robotic appearance is depicted in figure 6.

Her postoperative CA 19.9 came down to 87.57 U/ ml and she was discharged next day of the procedure. Pathological evaluation was compatible with endometrioma.

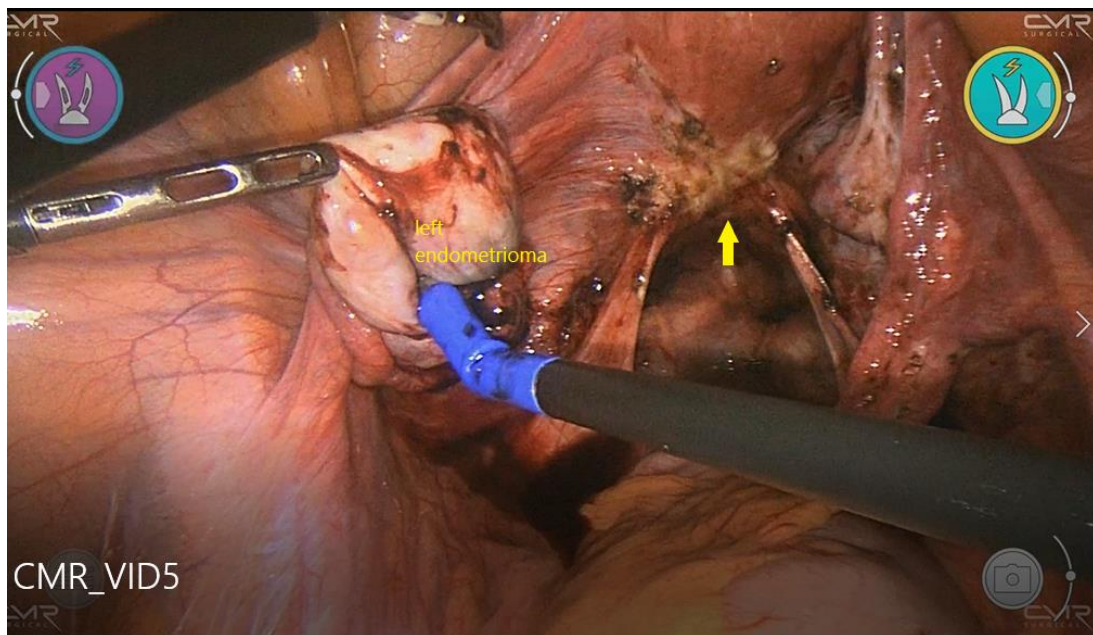


Figure 6: Left ovarian endometrioma along with ablated endometriotic deposits around the uterosacral ligament during robotic surgery.

	Case 1	Case 2	Case 3
Age	32	30	30
Presenting symptom	Bloating and abdominal discomfort	Acute abdominal pain in emergency	Severe dysmenorrhoea
Marital status	Unmarried	Unmarried	Unmarried
Examination Findings		Per abdomen: tenderness on superficial palpation	
Ultrasound findings	The right adnexa show a well-defined cystic lesion measuring approx. 6.6 X 6.1 X 5.0 cm showing echogenic areas a non-dependent location and a dot and dash pattern of echoes within the cyst. Left adnexa shows another cystic lesion with fluid- fluid levels with hyperechoic component in dependent portion of the cyst. Findings are suggestive of bilateral benign cystic lesions – Teratomas.	bilateral adnexal mass, right sided being 4.5cmX 4.5cm X 2.9 cm and volume 32.0 cc and Left adnexal mass measures approximately 5.0cm X5.0 cm X4.4 cm volume being 60 cc and is homogeneously hyperechoic. with query torsion of left ovarian cyst with probe tenderness and minimal fluid in pouch of douglas noted on the ultrasound.	Minimal subendometrial adenomyosis with endometrial thickness being 8.3mm with minimally tender left ovary containing 29X 26X 21mm. avascular cyst completely filled with low level internal echoes containing fluid-fluid debris level suggestive of endometriotic cyst.
Ca 125	12.37	15.2	6.4
CA 19-9	141.2	884	481
AFP	0.94		
Surgery Performed	Diagnostic and operative laparoscopy with bilateral ovarian cystectomy	Emergency laparoscopy and bilateral ovarian cystectomy	Hysteroscopic endometrial biopsy with Robotic endometriotic cystectomy with endometriotic ablation
Intra operative findings	<ul style="list-style-type: none"> • Bilateral ovarian cyst right sided measuring 8 cm. X 7 cm. and left sided measuring 6cm. X 7 cm. • Peritoneal fluid was taken and sent for cytology • Left ovary adhered to the abdominal wall adhesion released. • Frozen section sent intraoperatively for histopathology (HPE) revealed benign mature cystic teratoma. 	<ul style="list-style-type: none"> • Left ovary along with dermoid cyst and the fallopian tube revealed torsion with two and a half twists, untwisting done. No necrosis or hemorrhage was noted. • Left ovarian dermoid multilobulated cyst of around 14X 12 cm. noted and intact cyst removal was done in bag piecemeal to avoid spillage. • Right ovarian bilobed dermoid cyst around 10cm. X 8 cm. 	<ul style="list-style-type: none"> • On Hysteroscopy: • Endometrial biopsy was taken and specimen sent for histopathology. • On laparoscopy: • Endometriotic deposits present on posterior surface of uterus and on uterosacral ligaments which we ablated.

Citation: Dr. Apoorva Dave "Ca 19-9 in Ovarian Pathology: Should it be Taken Seriously?"

	<ul style="list-style-type: none"> Bilateral ovarian cystectomy done keeping normal ovarian stroma preserved and cystectomy specimen sent for HPE 	<p>removed keeping the capsule intact and specimen sent for histopathology and healthy ovarian tissues preserved.</p> <ul style="list-style-type: none"> Adhesions present on right anterior uterine wall- adhesiolysis done. <p>Clear fluid noted in pouch of douglas.</p>	<ul style="list-style-type: none"> Endometriotic nodules present on uterosacral ligament same excised. Left ovary shows endometriotic cyst of around 2.0cm. X 2.5cm., cystectomy done and specimen sent for HPE. Left tube adherent to the left ovary – sam released Right tube and ovary normal.
Histopathology results	Mature cystic teratoma	Mature cystic teratoma	Endometrioma
Post-operative period	CA 19-9: 46.17 U/ml	CA 19-9: 255.12 U/ml	CA 19-9: 87.57 U/ ml

Table 1: Comparison of various parameters among the three cases.

One of the most common benign ovarian tumors are mature cystic teratoma (MCT) which accounts for approximately 10–20% of all ovarian neoplasms [6]. In most of the cases MCT is incidentally detected on imaging studies or routine pelvic examination as it is asymptomatic in nature. In about 20% of cases complications can be seen in association with MCT, which includes rupture, torsion, infection and transformation into malignancy, that is why it is important to diagnose and treat MCT. Histopathologically, MCT comprises of tissue derivatives of 1 or more of the 3 germ layers which is ectoderm, mesoderm and endoderm. Therefore, several tumor markers may be raised in ovarian MCT like CA125 and CA19-9. Particularly, CA19-9 which is considered as a potential marker for the diagnosis of ovarian MCT, is a monosialoganglioside also linked with gastrointestinal adenocarcinomas [7-11]. Despite the fact that the ultrasound characteristics of ovarian MCT have been well accepted, imaging study alone cannot determine the nature of MCT.

Article	Type of study	Inclusion criteria	Number of cases	Age (years)	CA19-9 Elevation (%)	Tumor size	Bilaterality (Bil/ R/ L)	Torsion	Components on Histology	CA -125 elevation
Dede et al. [9]	Retrospective	N/A	31 vs 49 Total =80	31.9±12.5 vs 33.6 ±10.9b	38.8%	10.1±6.7 vs 5.9±2.4	Bil 16/31 vs 6/49	N/A	N/A	N/a
Frimer et al. [12]	Retrospective	Diagnosis of MCT on HPE; tumour markers data available; without incidental pathology	52 vs 87 Total = 139	42.6±15.5 vs 41.2±13.7	37.4%	7.9±3.6 vs 7.5±4.2	Bil 6/52 vs 6/87	N/A	N/A	N/A
Kyung et al. [11]	Retrospective	Without any ovarian or uterine pathology	52 vs 111 Total = 163	33.5±12.5 vs 33.75±8.17	32%	9.5±3.5 vs 9.25±3.17	Bil 10 vs 23 R 28 vs 50 L 14 vs 38	11 vs 10	N/A	N/A
Cengiz et al. [13]	Retrospective	Tumour markers data available; no emergent cases	32 vs 78 Total =110	N/A	29%	<4 cm 2 vs 13; 4-10 cm 27 vs 58; >10 cm 3 vs 7	Bil 0 vs 5 R 18 vs 44 L 14 vs 29	5 vs 9	Sebum: 25 vs 52; Hair: 21 vs 48; Keratin: 2 vs 20; Cartilage : 4 vs 14; Teeth: 3 vs 1	N/A
Yesilyurt et al. [14]	Retrospective	Age ≤ 35 years; no pregnancy ; no other pelvic pathology, like fibroid or endometriosis; no malignant lesion; no severe disease of kidney and liver; laparoscopic surgery	18 vs 59 Total =77	N/A	23.4%	N/A	Bil 4/18 vs 11/59	N/A	N/A	N/A
Üstünyurt et al. [15]	Retrospective	Without malignant changes	74 vs 113	36.9±13.4 vs 37.5±12.6	39.6%	8.8±4.5 vs 7.1±4.5	Bil 9/74 vs 9/113	N/A	N/A	33/74 vs 13/113

Citation: Dr. Apoorva Dave "Ca 19-9 in Ovarian Pathology: Should it be Taken Seriously?"

MAR Gynecology Volume 3 Issue 6

www.medicalandresearch.com (pg. 11)

			Total =187							
Cho et al. [5]	Retrospective	MCT confirmed on HPE; tumour markers data available	105 vs 134 Total =239	N/A	44%	8.53±3.8 4 vs 6.95±3.9 7	Bil 19/105 vs 18/134		Fat: 55/105 vs 27/134; Calcification: 32/105 vs 31/134; Soft tissue: 30/105 vs 38/134; Solid portion: 7/105 vs 9/134; Septation: 10/105 vs 13/134	11/105 Vs 9/134
Present study	Case report	N/A	2 cases		100%		Both Bil	1 case		None

Table 2. Various studies on Mature cystic teratoma and its association with CA 19-9 levels.

Many a times it is difficult to make a differential diagnosis by pelvic imaging studies alone despite having MCT specific features such as fat component and calcification, a study done by Mais et al., stated that due to the presence of associated pelvic abnormalities, approximately 30% of MCT may not be noted on ultrasound [16]. Actually, 80% cases with an echo pattern that should suggest malignancy were actually cystic teratomas [17].

The challenge with diagnosis of MCT is that it has got a huge tumor size along with that remarkably raised tumor markers may be misinterpreted as malignant. For benign and malignant tumors, the surgical procedure is totally different, hence it is very important for women with an adnexal mass to have a differential diagnosis. Various studies have proposed importance of serum CA19-9 levels as a tool to help in making the diagnosis of MCT [9-11]. CA19-9 seen in association with gastrointestinal adenocarcinomas containing mucins and is very often manifested in the mucinous histotype of ovarian cancers, is basically a sialylated Lewis A antigen [8].

The reason behind elevated CA 19-9 in the cases with MCT can be due to the histological characteristics as it comprises of various tissues. According to our case report, CA 19-9 was more frequently elevated than CA 125 and thus can be a potential marker in MCT. As per various studies the rate of CA19-9 elevation in MCT varies from 23.4% to 59% [10,14] whereas in our case report both the cases with MCT had increased levels of CA 19-9.

As CA 125 expression has got a wide distribution, its levels may be raised in various inflammatory and benign conditions, including MCT. For the early detection of ovarian malignancy, the combination of CA125 level and imaging studies are frequently used as a tool. Sometimes additional data is needed to differentiate MCT from ovarian carcinoma [19,20]. Features such as morphology and serology including its large size and elevations of various tumor markers pose a challenge in differentiating MCT from ovarian carcinoma.

The CA 19-9 is also considered to be a pentasaccharide with fructose as a carbohydrate component which is a group of oncofetal antigens. During intra uterine period, it is produced in the epithelium of the stomach and its synthesis is remarkably decreased in the adulthood. Recent studies suggest that CA 19-9 may be synthesized in bronchus, glandular structures of the gall bladder, pancreas and some gynecological tumors. [21] Some studies show that CA-19-9 may be demonstrably elevated in endometriosis and exhibit the same or decreased sensitivity as CA-125. [21]

Gynaecological cases	Non gynaecological cases
<ul style="list-style-type: none"> • Mature cystic teratoma (Dermoid cyst) [9-15] • Mucinous ovarian tumour [5] • Epithelial ovarian carcinoma [4] • Endometriosis [11] 	<ul style="list-style-type: none"> • Colorectal carcinoma, [4] • Pancreatic adenocarcinoma [4] • Biliary tree malignancy [2] • Gall bladder carcinoma [21]

Table 3: Causes of Elevated CA 19-9 in Various Gynaecological and Non-Gynaecological Cases.

Harada T et al. in their retrospective study on one hundred one women having endometriosis and 22 without endometriosis showed that there was significant association of mean serum CA19-9 levels with all stages of endometriosis and it correlated with the Revised American Fertility Society classification scores. [22]

There is a delay of 8 to 10 years in making the diagnosis of endometriosis as there is usually a misjudgment of symptoms in adolescents and young girls. [23] CA 19-9 is nonspecific marker of endometrial and ovarian pathology, but it may be helpful in timely diagnosis and management of such

cases. It is of utmost importance to look for new tumor markers and validation of these markers for prognostication in order to reduce the time lag between making the diagnosis and initiation of treatment. There is a need for a large-scale study on higher number of participants to help in reaching a conclusion.

Conclusion

Although raised CA 19-9 level alone cannot differentiate benign ovarian pathologies from malignant ovarian masses, but cases with ultrasound characteristics of MCT and an elevated biomarker doesn't require any supplementary preoperative investigations. However, the diagnostic value of CA 19-9 is still a question mark and CA 19-9 can serve only as an additional diagnostic tool in patients with suspected MCTs. Further studies are needed in this field to explain the particular role of the tumor marker and the various pathological and physiological steps leading to the increase in CA 19-9.

References

1. Berek JS, Bast RC., Jr Ovarian cancer screening: the use of serial complementary tumor markers to improve sensitivity and specificity for early detection. *Cancer*. 1995;76(10 Suppl):2092–2096.
2. Kelly PJ, Archbold P, Price JH, Cardwell C, McCluggage WG. Serum CA19.9 levels are commonly elevated in primary ovarian mucinous tumours but cannot be used to predict the histological subtype. *J Clin Pathol*. 2010;63:169–173.
3. Koprowski H, Herlyn M, Steplewski Z, Sears HF. Specific antigen in serum of patients with colon carcinoma. *Science*. 1981;212:53–55.
4. Steinberg W. The clinical utility of the CA 19-9 tumorassociated antigen. *Am J Gastroenterol*. 1990;85:350–355.
5. Cho HY, Kyung MS. Serum CA19-9 as a predictor of malignancy in primary ovarian mucinous tumors: a matched case-control study. *Med Sci Monit*. 2014;20:1334–1339.
6. Ayhan A, Bukulmez O, Genc C, Karamursel BS: Mature cystic teratomas of the ovary: case series from one institution over 34 years. *Eur J Obstet Gynecol Reprod Biol*, 2000; 88: 153–57

7. Scharl A, Crombach G, Vierbuchen M et al: Antigen CA 19-9: presence in mucosa of nondiseased mullerian duct derivatives and marker for differentiation in their carcinomas. *Obstet Gynecol*, 1991; 77: 580–85
8. Rosen DG, Wang L, Atkinson JN et al: Potential markers that complement expression of CA125 in epithelial ovarian cancer. *Gynecol Oncol*, 2005; 99: 267–77
9. Dede M, Gungor S, Yenen MC et al: CA19-9 may have clinical significance in mature cystic teratomas of the ovary. *Int J Gynecol Cancer*, 2006; 16: 189–93
10. Coskun A, Kiran G, Ozdemir O: CA 19-9 can be a useful tumor marker in ovarian dermoid cysts. *Clin Exp Obstet Gynecol*, 2008; 35: 137–39
11. Kyung MS, Choi JS, Hong SH, Kim HS: Elevated CA 19-9 levels in mature cystic teratoma of the ovary. *Int J Biol Markers*, 2009; 24: 52–56
12. Frimer M, Seagle BL, Chudnoff S, Goldberg GL, Shahabi S: Role of elevated cancer antigen 19-9 in women with mature cystic teratoma. *Reprod Sci*. 2014, 21:1307-11. 10.1177/1933719114525274
13. Cengiz H, Yasar L, Kaya C, Erkin M, Karakaş S: The role of tumor markers in predicting mature cystic teratoma of the ovary. *Gineco.eu*. 2012, 8:158-61. Accessed: November 19, 2019: <http://www.gineco.eu/system/revista/20/158-161.pdf>.
14. Yesilyurt H, Seckin B, Aktulay A, Ozyer S: Age-stratified analysis of tumor markers and tumor characteristics in adolescents and young women with mature cystic teratoma. *J Chin Med Assoc*. 2018, 81:499-504. 10.1016/j.jcma.2017.07.005
15. Üstünyurt E, Gungor T, Iskender C, Ustunyurt BO, Bilge U, Mollamahmutoglu L: Tumor markers in mature cystic teratomas of the ovary. *Arch Gynecol Obstet*. 2009, 279:145-47. 10.1007/s00404-008-0688-2
16. Mais V, Guerriero S, Ajossa S et al: Transvaginal ultrasonography in the diagnosis of cystic teratoma. *Obstet Gynecol*, 1995; 85: 48–52
17. Quinn Sf, Erickson S, Black WC: Cystic ovarian teratomas: the sonographic appearance of the dermoid plug. *Radiology*, 1985; 155: 477–78
18. Kikkawa F, Nawa A, Tamakoshi K et al: Diagnosis of squamous cell carcinoma arising from mature cystic teratoma of the ovary. *Cancer*, 1998; 82: 2249–55

19. Jacobs IJ, Skates S, Davies AP et al: Risk of diagnosis of ovarian cancer after raised serum CA 125 concentration: a prospective cohort study. *BMJ*, 1996; 313: 1355–58
20. Jacobs IJ, Skates SJ, Macdonald N et al: Screening for ovarian cancer: a pilot randomised controlled trial. *Lancet*, 1999; 353: 1207–10
21. Fassbender A, Burney RO, O DF, et al. Update on biomarkers for the detection of endometriosis. *Biomed Res Int* 2015;130854.
22. Harada T, Kubota T, Aso T. Usefulness of CA19-9 versus CA125 for the diagnosis of endometriosis. *Fertil Steril*. 2002 Oct;78(4):733-9. doi: 10.1016/s0015-0282(02)03328-9. PMID: 12372448.
23. Ahn SH, Singh V, Tayade C. Biomarkers in endometriosis: challenges and opportunities. *Fertil Steril* 2017;107:523–32.