



Torsion of the Para Ovarian Cyst and Fallopian Tube in Adolescent Girl -- High Index of Suspicion Helps Salvage the Fallopian Tube.

Dr Divyatha Jayaram *

Corresponding Author: Dr. Saima Najam, FCPS, PG Certification in Medical Education (dundee), Head of the Obgyn Department, Dr. Sulaiman Al Habib Hospital, Sweidi, Riyadh, Saudi Arabia.

Copy Right: © 2022 Dr. Saima Najam, This is an open access article distributed under the Creative Commons Attribution License, which permits unrestricted use, distribution, and reproduction in any medium, provided the original work is properly cited.

Received Date: September 21, 2022

Published Date: October 01, 2022

Abstract

Para ovarian cyst makes about 10 % of all adnexal cyst.

Fallopian tube torsion secondary to paraovarian or paratubal cyst is a rare gynecological cause of acute abdomen

There are no characteristic features on radiological imaging, making preoperative diagnosis very difficult and results in irreversible damage to fallopian tube.

Physicians should be cautious and have a high index of suspicion , so that timely surgical intervention can prevent complications such as fallopian tube necrosis, gangrene, removal of the tube, and its long-term implications especially in women of the reproductive age group.

Conclusion

Fallopian tube torsion should be considered in the differential diagnosis for young girls who present with mild to moderate acute pelvic pain and who demonstrate a cystic mass in a midline position associated with a normal ipsilateral ovary

In this report, we present a case of isolated fallopian tube torsion with para ovarian (fimbrial) cyst in a young female patient.

Case report

A 13 year old girl presented to emergency department with complaints of mild to moderate lower abdominal pain & constipation of two day duration .

She visited another facility emergency department with similar complaint of lower abdominal pain and constipation about 8 hours before for which she was treated for constipation and discharged with medications . The pain was moderate intensity, pain score of 4/6 , constant , suprapubic location and associated with nausea , vomiting & frequency of urine .

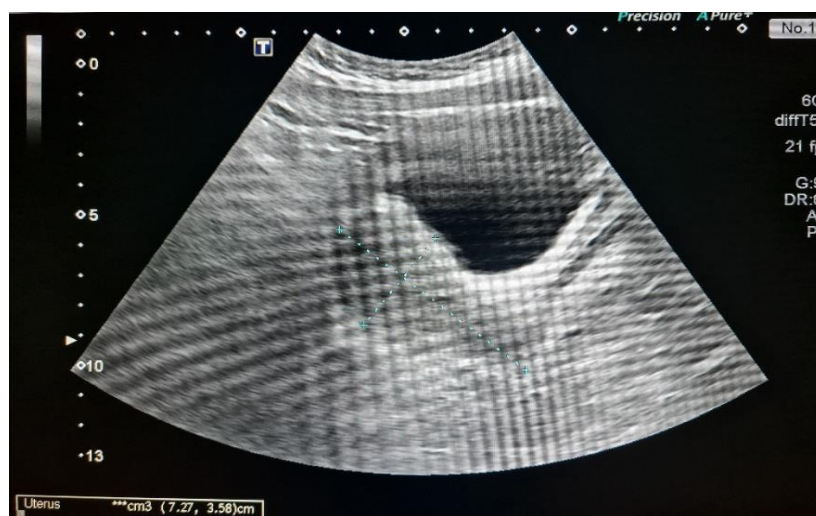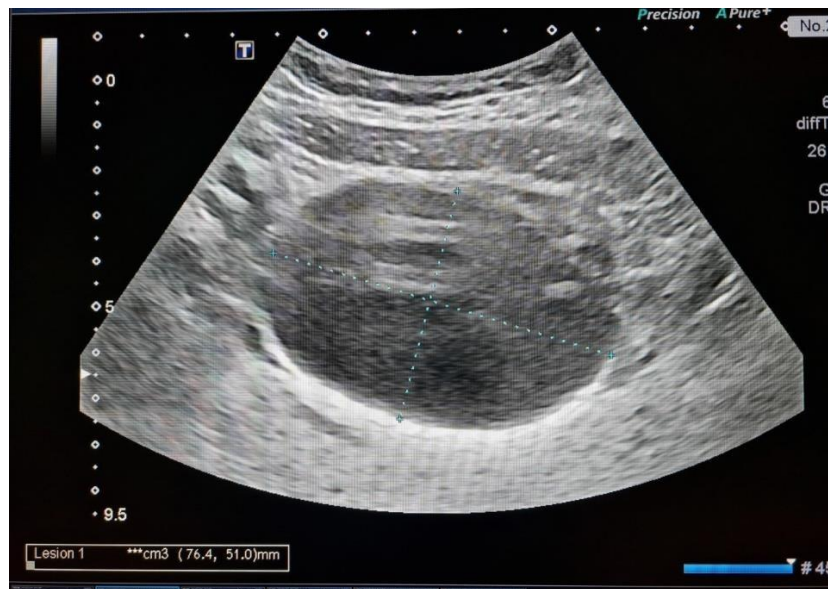
There was no history of fever or fainting attacks. Her menstrual history was normal with regular cycles. Her last menstrual cycle was a week before presentation. she is unmarried.

She gave history of cyst diagnosed by ultrasound about 32 days back- On examination, her general condition was found to be stable, she was afebrile, and her pulse rate was 90 / min & Blood pressure was 110 / 80 mm of hg. well hydrated and calm patient.

Per abdominal examination - slight supra pubic tenderness, no guarding / rigidity, Ultrasonography -- showed a clear cyst of size 7.6 x 5.1 cms, placed anterior to uterus. Both ovaries seen separately and is normal. flow on Doppler appeared normal. pouch of Douglas was normal

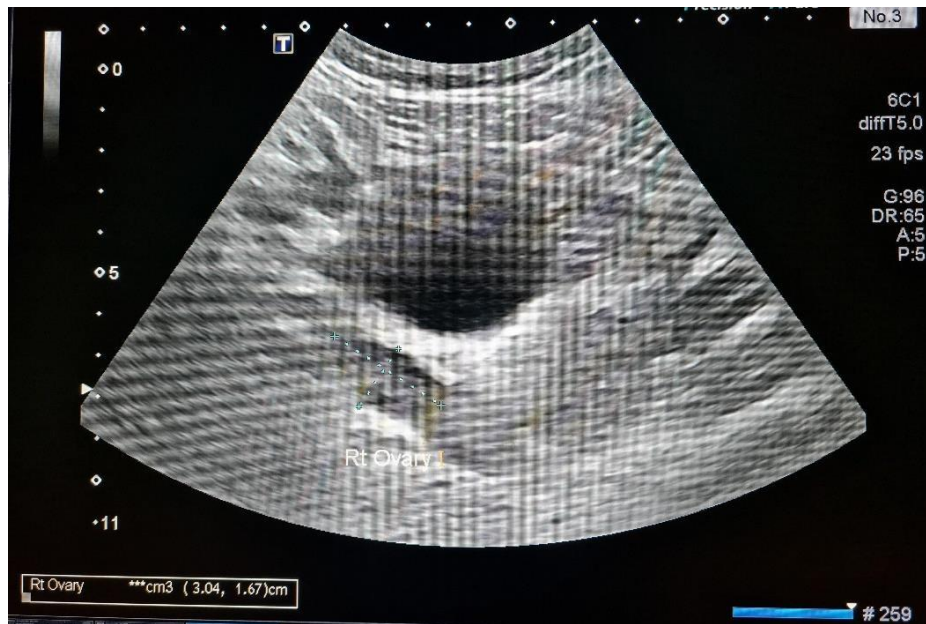
Admission Scan Images

Clear cyst anterior to the uterus

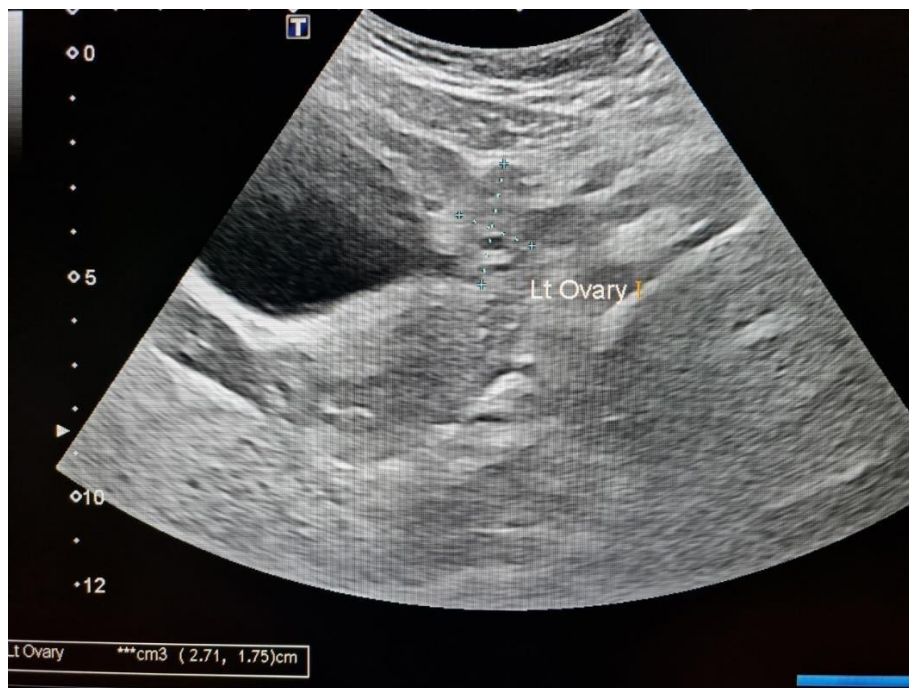

Uterus normal size

Citation: Dr Divyatha Jayaram "Torsion of the Para Ovarian Cyst and Fallopian Tube in Adolescent Girl -- High Index of Suspicion Helps Salvage the Fallopian Tube" MAR Gynecology Volume 3 Issue 6



Right ovary normal & Doppler flow normal



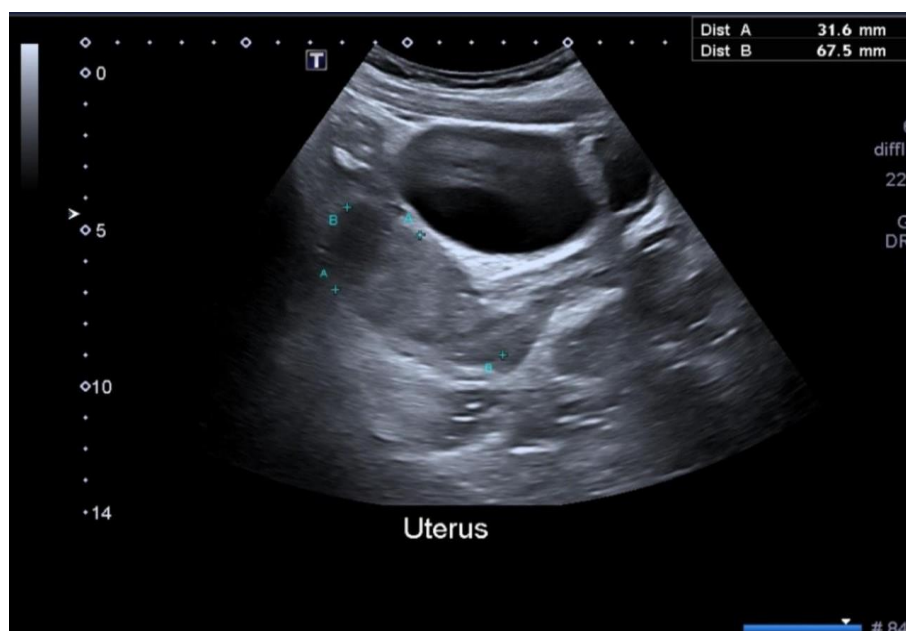
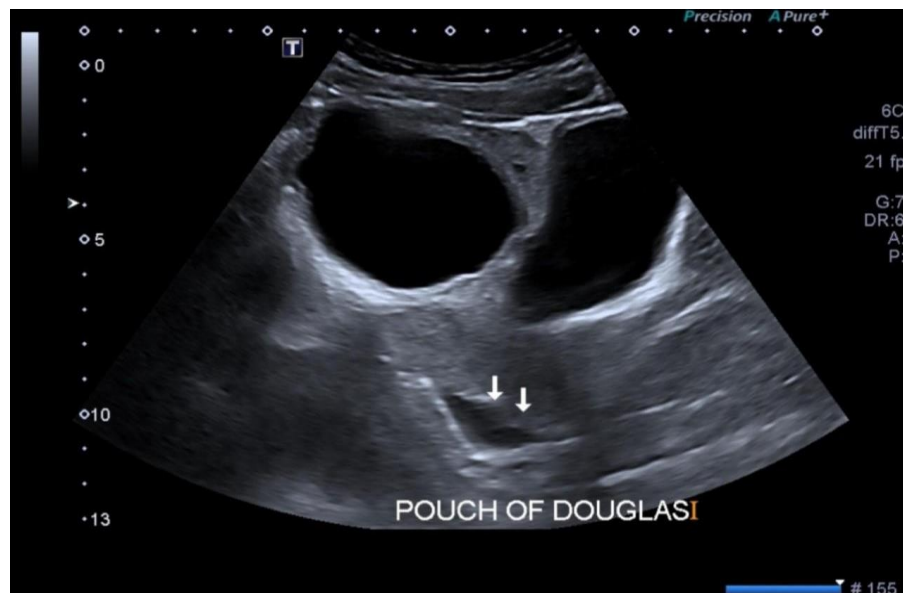
Left ovary normal & Doppler flow normal

Investigations revealed - Hemoglobin 10.60 g/dL. WBC Count $9.98 \times 10^3/uL$ 4.0 - Neutrophils (Absolute count) 7.64 Pregnancy test was negative USG done 32 days back in other facility said - Anechoic cystic lesion is seen in the umbilical region measuring approximately 6.0 x 5.1 cm.

The differential diagnosis of Para ovarian cyst done, and patient was admitted for medical management. she was symptomatically treated with analgesics and antacids and anti-emetics. Patient was comfortable and had complaint of moderate pain. no vomiting / nausea.

Per abdominal examination was soft with mild supra pubic tenderness. no guarding / rigidity Repeat ultrasound was done next day in view of persistent mild tenderness.

Repeat Ultrasound - next day showed same picture with mild fluid in pouch of douglas and Doppler ultrasound showed normal blood flow to both ovaries



Decision to proceed with laparoscopy taken in view of fluid in pod and persistent moderate pain.

Peri-operative findings revealed

Cystic about 7 x 6 cms occupying the pelvis and sitting anterior to the uterus About 100 ml hemorrhagic fluid in the pelvi

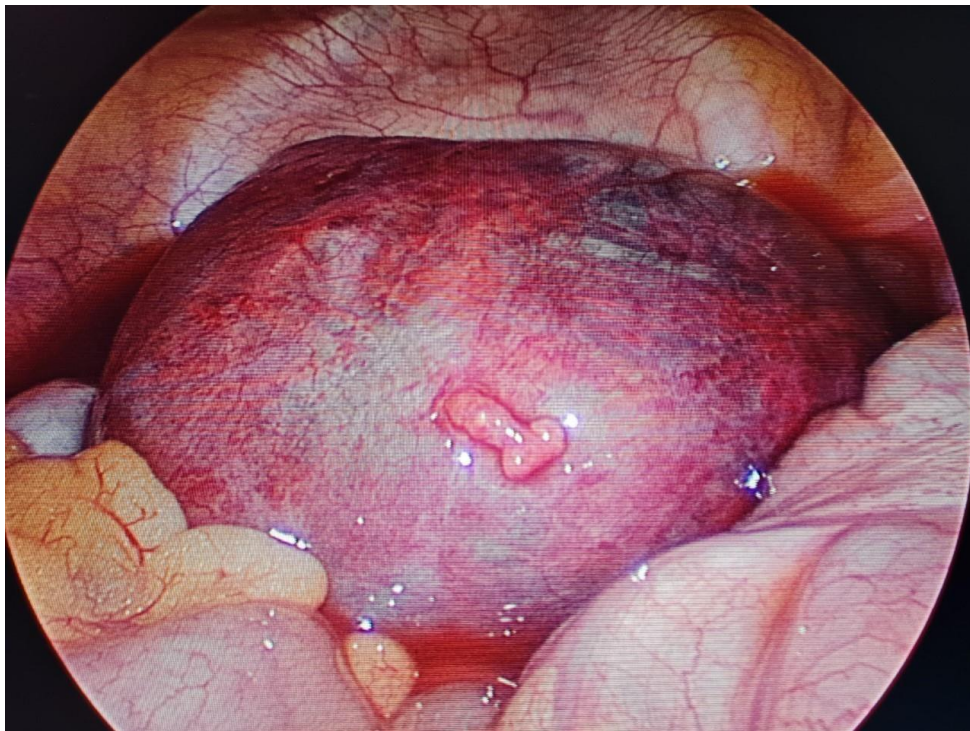
Torsion of tube with the cyst noted

On Detorsion, it was noted that the cystic structure was Left paraovarian cyst with secondary torsion of Left tube which was edematous and mild bluish only.

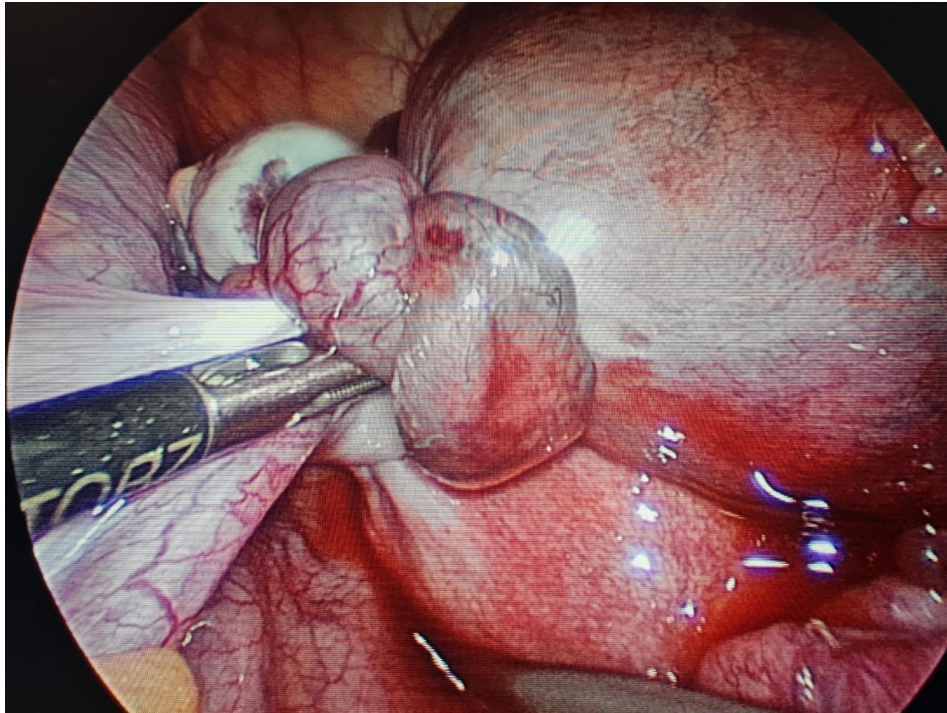
Left ovary was completely normal Uterus and right tube and ovary normal.

Laparoscopic Detorsion and paraovarian cystectomy was performed. Tube was conserved which appeared normal color at the end of surgery but edematous.

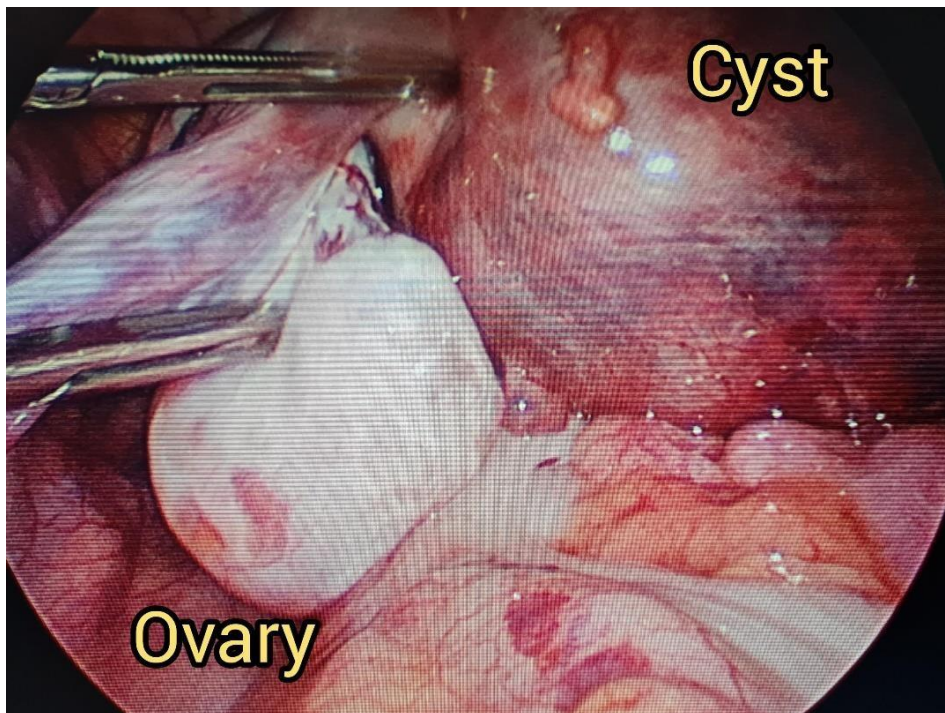
Laparoscopic Images



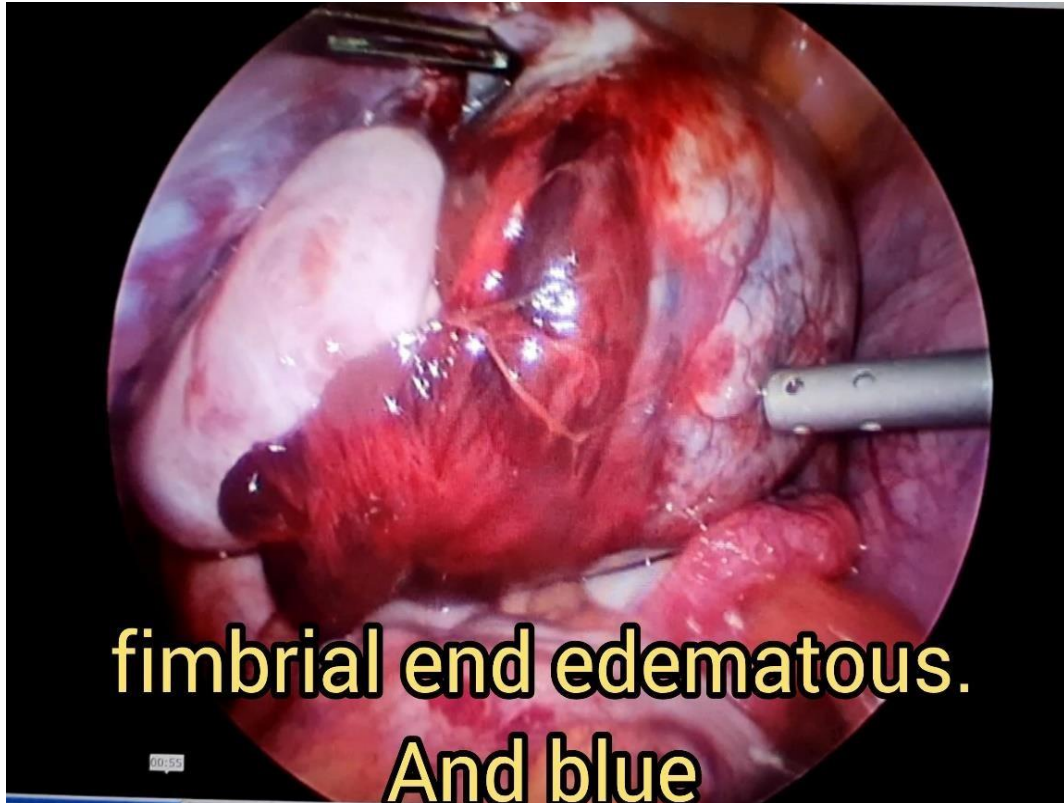
Huge Cyst Occupying Anterior to Uterus



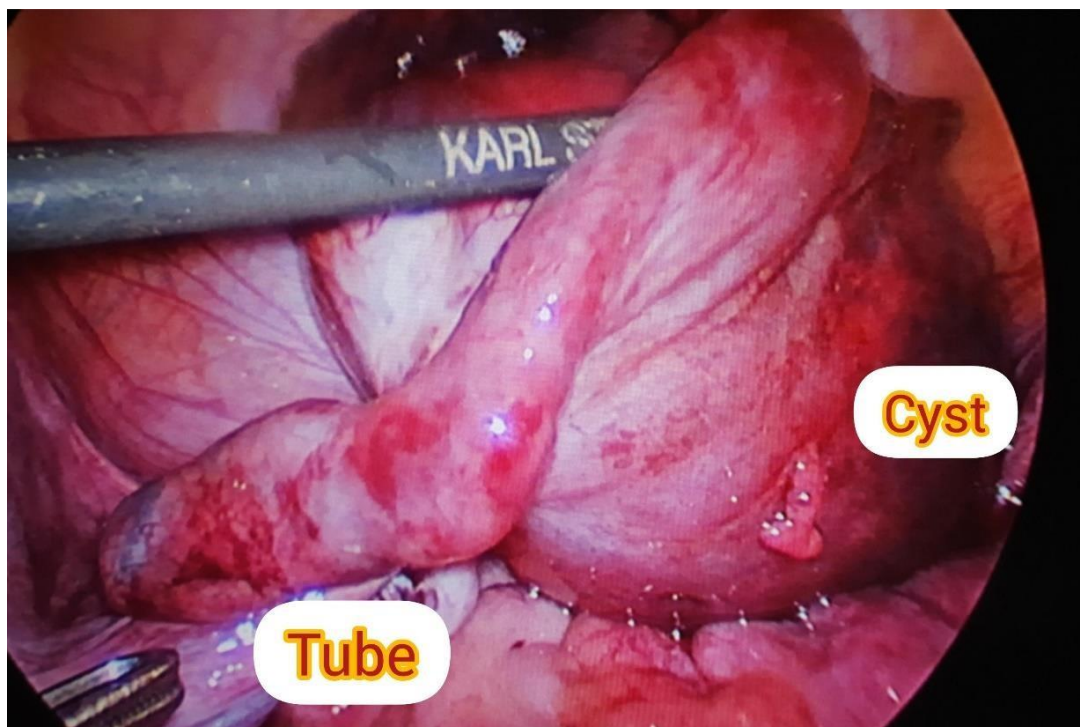
Multiple Twists of Tube

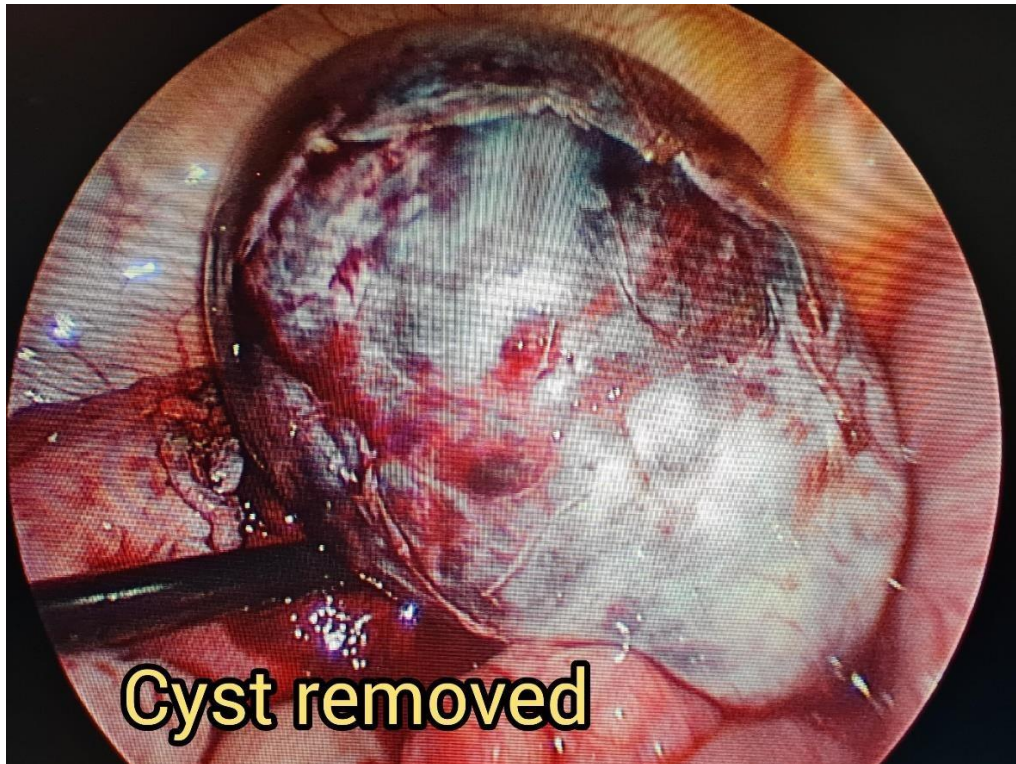


Left Ovary Looks Completely Normal



Tube and fimbrial end edematous & bluish





Cystectomy Done

Her Post operative period was uneventful

Histopathology -

Fimbrial Cyst fluid FNAC:

- Cytological features are consistent with a Cyst.
- No abnormal cells seen in the smears studied.

Cyst capsule - fimbrial left side:

- Hemorrhagic cyst wall: morphological features are consistent with Torsion of a simple tubal cyst.
- Negative for atypia/malignancy in the sections studied.

Acknowledgement

I would thank radiologist & anesthesia and OT team of Burjeel farha hospital and administration Dr Ramadan and DR Edwin who supported in literature and permitted to publish this case.

Keywords: acute abdomen; fallopian tube torsion; fimbrial cyst ; laparoscopy; paraovarian cyst.

References

1. Ardicli B, Ekininci S, Oguz B et al Laparoscopic detorsion of isolated idiopathic fallopian tube torsion; conservative management in a 13 year old girl Turk J Pediatr , 2013 :55 :451-4 Pub med
2. Wael Hosni & Carl-Michael Schmidt Isolated fallopian tube torsion A rare cause of acute pain abdomen Clinmed international library ISSN ;2377-9004
3. Devi Balasubramaniam, Kavitha yogini duraiswamy & saranya ravi Isolated fallopian tube transfer; A rare twist with a Diagnostic challenge that may compromise fertility Journal of human reproduction -9-jul-2020
4. H krissi et al. J Am Board Fam Pract2001 jul-aug Fallopian tube torsion: Laparoscopic evaluation & treatment of a rare gynecological entity