



Altered Hormonal Milieu Causing HSIL Mimicker in a Young Female with Secondary Amenorrhoea

Dr. Kiran Mehndiratta ^{1*}, Dr. Sreekala Sreehari ², Dr. Gunjan Singh ³,

1. Specialist Obstetrician-Gynecologist, NMC Specialty Hospital, Abu Dhabi, UAE.

2. Cytopathologist, NMC Specialty Hospital, Abu Dhabi, UAE.

3. Obstetrician-Gynecologist, NMC Specialty Hospital, Abu Dhabi, UAE.

Corresponding Author: Dr. Kiran Mehndiratta, Specialist Ob/Gyn, NMC Specialty Hospital, Abu Dhabi, UAE.

Copy Right: © 2022 Dr. Kiran Mehndiratta, This is an open access article distributed under the Creative Commons Attribution License, which permits unrestricted use, distribution, and reproduction in any medium, provided the original work is properly cited.

Received Date: December 12, 2022

Published Date: January 01, 2023

Introduction

Altered hormonal milieu and its influence in false interpretation of cervical Papanicolaou (Pap) smear as ASC-H or HSIL are well documented in literature 1. Previous studies have confirmed the low predictive value of a diagnosis of atypical squamous cells, cannot exclude a high-grade squamous intraepithelial lesion (ASC-H) in a Papanicolaou (Pap) smear for subsequent high-grade dysplasia in the postmenopausal, postpartum, pregnancy and contraceptive use. Here we present an interesting case report where the patient with a history of secondary amenorrhoea for two years showed HSIL (high grade squamous intraepithelial neoplasia) like picture in PAP smear. On further evaluation, HPV test was found to be negative. Hormonal treatment for 3 weeks showed an amazing morphologic change in the repeat PAP smear and follow up colposcopic biopsy. Such a drastic response to short term hormonal treatment is a novel idea. This unique treatment made a sudden impact in patient management and gave the whole diagnostic and treatment procedure a new dimension.

Case Report

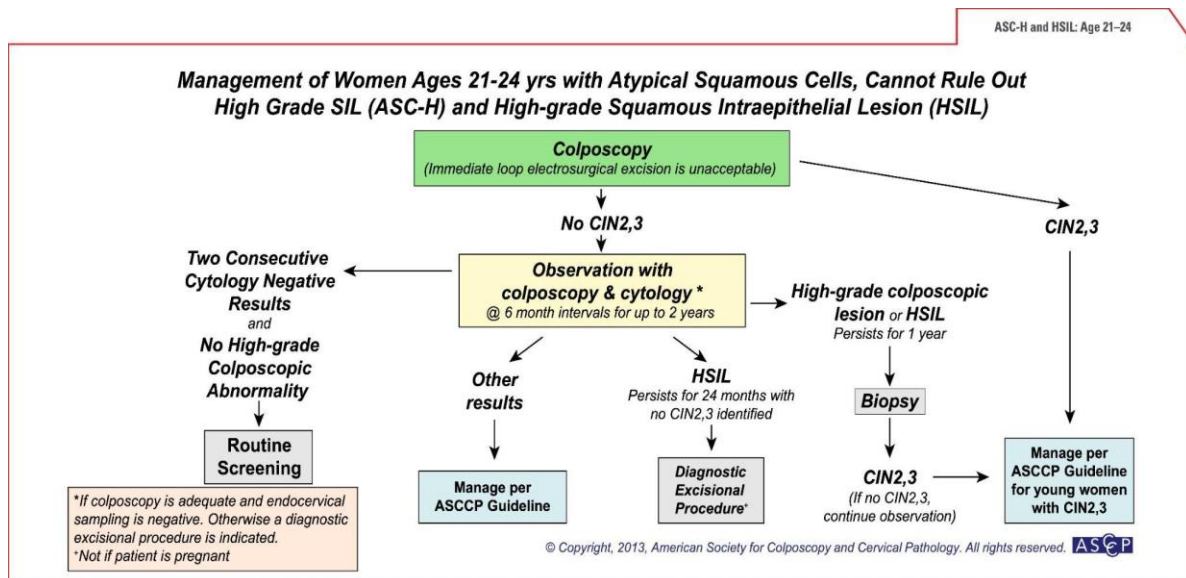
The patient was a 24-year-old lady who presented to the gynaecology outpatient department of our hospital on 23/3/14 with complaints of irregular cycles since menarche. She attained menarche at the age of 17 years and had once a year menstrual period. There was no history of medical consultation done for the same. At the time of presentation, she was married for 3 months and was keen for conception. Her past medical and surgical history was not significant. As per the family history, father had diabetes mellitus and mother had bronchial asthma. No history of malignancy in the family. She was not on any medication at present and had no allergies.

On clinical examination, the patient's general condition was good. Her height was 161 cm, weight 83.3 kg with a BMI of 32.2 kg/m². The general physical examination was within normal limits. During gynaecological checkup, per abdomen examination showed a soft abdomen with no organomegaly. Per speculum showed clinically healthy cervix, mucoid discharge for which PAP smear and high vaginal swab were taken. Per vaginum examination showed anteverted uterus, normal size, mobile, bilateral fornices clear and non-tender.

As part of the secondary amenorrhoea and primary infertility work up, routine biochemistry and hormonal profile were done. Her serum beta hCG was negative, haemoglobin was 13.1 mg/dl, platelets 295 x 10⁹/l, fasting blood sugar 89 mg/dl, fasting insulin 7.0 mIU/l serum TSH and prolactin were 4.15mIU/l and 326mIU/l respectively. The pelvic ultrasound showed a relatively small sized uterus

5.88 x 2.07x 2.89 cm, endometrium thin and homogeneous measuring 4.6mm. Bilateral ovaries showed peripheral multiple small follicles with dense echogenic stroma and ovarian volume of more than 10cc. The diagnosis of polycystic ovarian syndrome was made. High vaginal swab showed group B streptococcus which is a vaginal coloniser and no treatment was given. PAP smear was done.

The PAP smear showed predominantly superficial squamous cells with clusters and scattered atypical looking squamous cells having high nucleocytoplasmic ratio, nucleomegaly, hyperchromasia and irregular nuclear borders. Perinuclear halo is noted in some cells. The angry looking chromatin with the high N/C ratio led to the diagnosis of HSIL. The smears were reviewed intradepartmentally before finalization of the report. The smears were sent for review to two independent histopathologist/cytopathologists who agreed with the diagnosis of HSIL. The HPV testing and colposcopic biopsy were advised.



As per the ASSCP protocol, HPV test was done on 25/3/14 and the report came as negative for the high-risk HPV DNA. Recapitulating her clinical results and after discussing with the cytopathologist, diagnosis of secondary amenorrhea due to polycystic ovaries and abnormal PAP smear with HPV negative was made. A review of literature was done and it was seen that in conditions of menopause, disturbed hormonal milieu and contraceptive use, PAP smear diagnosis of ASC-H (atypical squamous cells- cannot exclude a high-grade lesion) may have a low sensitivity. Patient was given sequential estrogen and progesterone hormone tablets (estradiol valerate 2mg and norgestrel 0.50 mg) for 21 days for a withdrawal bleed. Simultaneously, for correction of the hormonal milieu locally, vaginal lactic acid gel and estrogen cream for 3 weeks were prescribed.

The patient had a withdrawal bleed after the 21-day estrogen and progestin sequential treatment and her day 2 FSH and LH were 4.9 and 9.6 mIU/ml respectively. She was planned for a colposcopy and cervical biopsy in the postmenstrual phase. At the time of colposcopy, just prior to the procedure a repeat PAP smear was taken. On colposcopy, acetowhite areas were seen at 12o'clock and 9o'clock positions. Punctation was seen at 12o'clock position, punch biopsy was taken from these areas and endocervical curettage was done. The repeat smears showed normal morphology with no evidence of atypical cells. The biopsy result showed cervical transformation zone with immature squamous metaplasia. No evidence of CIN or invasive malignancy noted.

Discussion

Worldwide, cervical cancer is the most common cancer affecting women after breast cancer. The disease has a long natural history and intervention and treatment of pre malignant conditions is highly effective. The easy accessibility of the cervix during a gynaecologic exam and the availability of a simple test for diagnosing pre invasive conditions make it suitable for mass screening. However, as mentioned in the introduction, screening is always a trade-off between sensitivity and specificity especially in certain situations like menopause, postpartum and contraception.

The Bethesda system was published initially in 1988 as a standardized system of Papanicolaou (Pap) test reporting. A 1991 revision recommended subdividing results designated atypical squamous cells of undetermined significance (ASCUS) into favor reactive or neoplastic categories. The early Bethesda system ASCUS designation was developed to allow maximum detection of both low-grade and high-grade squamous lesions. However, subsequent studies demonstrated that low-grade lesions often spontaneously regress, whereas high-grade squamous lesions do not.¹ Therefore, many studies were conducted to determine the clinical relevance of an ASCUS subcategory that would convey a higher level of concern for a high-grade squamous intraepithelial lesion (HSIL). Many authors conducted comparative studies of ASCUS Pap tests-favor HSIL and subsequent tissue specimens. These studies concluded that ASCUS Pap tests subcategorized into a favor HSIL category had histologically proven HSIL in from 40% to 60% of cases.^{2–6} Because of these and other studies, the ASCUS-favor reactive category was eliminated from the 2001 Bethesda system, and a separate designation of atypical squamous cells, cannot exclude a high-grade squamous intraepithelial lesion (ASC-H) was introduced.

Although studies have demonstrated the relatively high positive predictive value in the subsequent tissue diagnosis of high-grade dysplasia for the ASC-H category in the general population, (2–9) challenges still exist in the evaluation of atypical cells in the Pap tests of postmenopausal women as

well as pregnant, post-partum, contraceptive use and women with altered hormonal milieu. Many atrophy-related epithelial changes invoke difficulties in postmenopausal Pap test evaluation. Such difficulties include parabasal cells with reactive changes, pseudoparakeratosis and reactive metaplasia, which possibly may result in misinterpretation as ASCUS or even HSIL. Flynn and Rimm correlated ASCUS Pap tests with results of subsequent tissue biopsy and observed that 57.8% of their study patients had a subsequent negative biopsy, 5% had atypia associated with atrophy, 20% had low-grade squamous lesions, 8.9% had high-grade squamous lesions, and 2.2% had carcinoma.¹⁰ These authors reported that 22% of perimenopausal patients and only 6% of postmenopausal patients had HSIL in subsequent tissue specimens or Pap tests, suggesting that older women who are diagnosed with ASC-H are less likely to have HSIL than younger women. It seems likely that estrogen deficiency-related changes in postmenopausal Pap tests mimic HSIL.¹⁵ It appears plausible that the decrease in estrogen inherent in the postmenopausal state likely produces reactive cytologic atypia, which is misinterpreted as ASC-H. Consequently, the change in hormone levels observed in pregnant, postpartum, and contraceptive-use patients potentially may create a similar diagnostic dilemma. These results suggest that age rather than hormone alterations affect the capacity of ASC-H to predict subsequent HSIL, a finding that is typified in the average age of the study groups (postmenopausal women, 61.3 years; pregnant women, 26.7 years; postpartum women, 27.5 years; and contraceptive-use women, 27.5 years).

Altered hormonal milieu and its influence in false interpretation as ASC-H or HSIL are well documented in literature. But such a drastic response to short term hormonal treatment is such a novel idea, which made a sudden impact in patient management and gave the whole diagnostic and treatment procedure a new dimension. Overall, Pap tests from the pregnant, postpartum, and contraceptive-use groups had an intermediate cell-predominate pattern. An intermediate cell-predominant pattern has been described by other authors in the setting of medroxyprogesterone acetate and oral contraceptive-use.^{18,19} Pregnancy and postpartum states have been described previously as having increased numbers of metaplastic cells.^{20,21} Although an intermediate cell-predominate pattern was observed in some postmenopausal women, large numbers of women who had parabasal and even basal cellpredominate patterns were noted. Despite the differences in the level of maturation in the postmenopausal group relative to the other study patients, the cytomorphology of atypical cells that resulted in an ASC-H diagnosis was similar in all patients studied. Moreover, there were no morphological differences between Pap tests that had negative low-grade, and high-grade follow-up in any subgroup. Atypical cells that resulted in an ASC-H diagnosis were metaplastic in appearance

with increased nuclear-to-cytoplasmic ratios, nuclear hyperchromasia, and nuclear membrane irregularity.

No definite cytologic features were delineated that reliably could differentiate Pap tests with high-grade follow-up versus negative follow-up in any of the patient groups. Saad et al. also observed that there were no significant cytologic differences between the squamous intraepithelial lesion (SIL) and negative follow-up groups in their investigation of postmenopausal women.¹⁴ Thus, future studies focusing on reproducible morphologic differences between the negative and high-grade follow-up groups are needed to develop standard criteria for the diagnosis of ASC-H.

Secondary amenorrhea could be due to multiple factors. After ruling out pregnancy, it can be broadly classified into three categories - associated with normal ovarian function where conditions like asherman's syndrome and endometrial destruction due to tuberculosis, schistosomiasis and radiation have been described. The other category which is associated with decreased ovarian function could be hypergonadotropic (premature ovarian failure, iatrogenic due to chemotherapy and radiotherapy) or hypogonadotropic - normal gonadotropins (psychogenic, nutritional- starvation, anorexia nervosa, central nervous system lesions, endocrine disorders like thyroid dysfunction, hyperprolactinemia, and drugs. The third category is increased ovarian androgen production like polycystic ovarian syndrome which was found in this patient. The patient examination revealed a high BMI, ultrasound showed polycystic ovaries and a thin endometrium, hormonal profile ruled out thyroid and prolactin disorders and she had a withdrawal bleed after sequential estrogen and progestin hormone therapy, thus clinching the diagnosis of polycystic ovaries.

In our case the initial smear was so eye-catching with the atypical looking cells, that we could not ignore the possibility of a high-grade lesion. Hence, when the HPV result came as negative it was difficult to accept the same. This encouraged us to thoroughly understand the background alteration in hormonal milieu in the patient with secondary amenorrhoea, which led to a watchful waiting with short term hormonal treatment for 3 weeks, finally deciphering the crux of the disease process. The repeat PAP smear and colposcopic biopsy at the end of the hormonal treatment confirmed the same, finally leading to quality patient management, giving the patient peace of mind and a new lesson to all of us.

In conclusion, the diagnosis of ASC-H in patients with altered hormonal milieu due to ovarian or unexplained long-term amenorrhoea, like in postmenopausal, pregnant, postpartum and contraceptive-use categories Pap tests has a low predictive value in the subsequent diagnosis of high-grade squamous lesions. In addition, there are no definite cytomorphologic criteria that can be used reliably to distinguish between benign cellular changes and possible high-grade squamous lesions in these Pap

tests. HPV testing, although helpful, does not have 100% correlation with subsequent tissue/Pap test follow-up and cannot be used alone to triage this group of women for colposcopy. Therefore, continued Pap tests, colposcopic tests, and HPV testing are required for management in this group of patients.

References

1. Patton AL, Duncan L, Bloom L et al. Atypical squamous cells, cannot exclude a high grade squamous intraepithelial lesion and its clinical significance in postmenopausal, pregnant, postpartum and contraceptive- use patients. *Cancer* 2008; 114(6):481-488
2. Renshaw AA, Mody DR, Wang E et al. Hyperchromatic crowded groups in cervical cytology- differing Appearances and interpretation in conventional and Thin Prep preparations: a study from the College of American Pathologists Interlaboratory Comparison Programme in Cervicovaginal Cytology. *Arch Path Lab Med* 2006; 130(3):332-336
3. Solomon, D., Nayar, R.(eds). *The Bethesda System for Reporting Cervical Cytology: Definitions, Criteria and Explanatory Notes*. 2004, XXII, 191P
4. ASSCP PROTOCOL
5. Capewell AE. McIntyre MA. Elton RA. Postmenopausal atrophy in elderly women: is a vaginal smear necessary for diagnosis? *Age Ageing*. 1992. 21(2):117-120.
6. De May RM. *The Art and Science of Cytopathology*. Volume I- Exfoliative Cytology
7. Society of Obstetricians and Gynaecologists of Canada. SOGC clinical practice guidelines: the detection and management of vaginal atrophy. *Int J Gynaecol Obstet*.2005.88(2):222-228.
8. Secondary Amenorrhoea.