



## Unusual Ureteric Abnormalities on Robotic Hysterectomy- Series of 2 Cases and Review of Literature

Dr Rahul Manchanda \*<sup>1</sup>, Dr Sonika Sharma <sup>2</sup>, Dr PP Singh <sup>3</sup>, Dr Amit Malhotra <sup>4</sup>

1. MBBS, MD (obstetrics and gynaecology), Head of the department, Department of Gynae Endoscopy, PSRI Hospital, Delhi.
2. MBBS, MD (obstetrics and gynaecology), Senior resident, Department of Gynae Endoscopy, PSRI Hospital, Delhi.
3. MBBS, MS, MCH(AIIMS) Urology, Head of department, Department of Urology and Kidney Transplant, PSRI Hospital, Delhi.
4. MBBS, DNB (General Surgery), DNB Urology, Senior consultant, Department of Urology and Kidney Transplant, PSRI Hospital, Delhi.

**Corresponding Author: Dr Rahul Manchanda**, MBBS, MD (obstetrics and gynaecology), Head of the department, Department of Gynae Endoscopy, PSRI Hospital, Delhi.

**Copy Right:** © 2022 Dr Rahul Manchanda, This is an open access article distributed under the Creative Commons Attribution License, which permits unrestricted use, distribution, and reproduction in any medium, provided the original work is properly cited.

**Received Date: December 28, 2022**

**Published Date: January 05, 2023**

**Abstract**

**Objective:** *The objective of our study was to report 2 cases of ureteric abnormalities discovered on robotic hysterectomy and review of literature available.*

**Introduction:** *Urinary system congenital anomalies more commonly seen than other systems congenital anomalies. These developmental anomalies can lead to intra-operative injuries, even by surgeons with a stronghold on normal ureteric anatomy.*

**Material & Method:** *We describe the first case of duplex ureter diagnosed with cystoscopy and retrograde pyelography. Another case of ectopic ureteric orifice revealed during cystoscopy. Review of literature was undertaken of available literature by google search of databases for last 35 yrs.*

**Results & Discussion:** *The lower urinary tract injuries are serious complications with high morbidity, especially during delayed diagnosis. The knowledge of urological variants, meticulous tracing of the course of ureter, and use of postoperative cystoscopy could reduce these complications, particularly in phase of increasing minimally invasive surgeries. In this study we have reviewed various published articles dealing with intraoperative cystoscopy during hysterectomy*

**Conclusion:** *Routine cystoscopy performed during hysterectomy may lead to early diagnosis of any urological injuries and reduce delayed postoperative urologic complications. Large scale studies still need to be done in order to say whether it should be a part of one's protocol post hysterectomy.*

**Keywords:** *bladder, ureter, complications, hysterectomy, laparoscopy, cystoscopy*

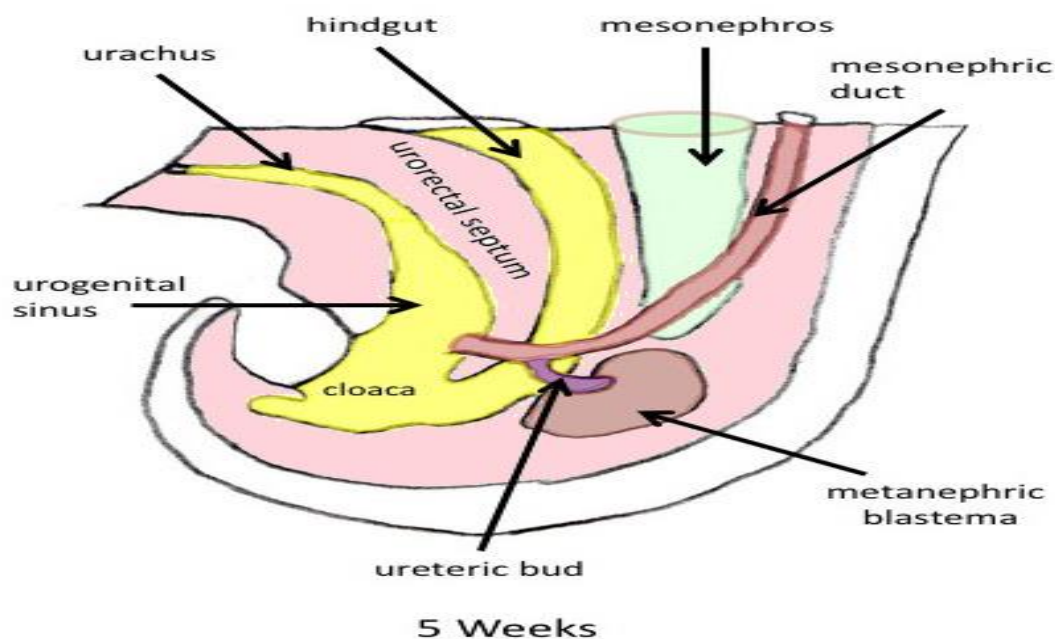
## Introduction

One of the most troublesome problems in gynaecological surgeries for hysterectomy is the potential occurrence of ureteric or bladder injury. Seventy-five percent of ureteric injuries occur during gynaecological procedures, especially

hysterectomies, while the rest occur during other abdominal operations [1]. The injuries in gynaecology have been noted to occur after total or subtotal hysterectomy by laparotomy (TAH/STAH), after laparoscopic total or subtotal hysterectomy (TLH/STLH), and after laparoscopically-assisted vaginal hysterectomy (LAVH) or vaginal hysterectomy (VH). The injury has also been recorded after ovarian or endometriosis operations; 85% of cases occurred during dissection of the cervix. According to the literature, the rate for such injuries resulting from hysterectomy by laparotomy is 0.03–2% [2-4], is 0.02-5% in VH [2-5], is up to 0.2-6% in LH, and 3.8% in LAVH [6].

Anatomy of the urinary structures should be taken into consideration during surgery but unrecognised congenital abnormalities can present unfamiliar anatomy to the surgeon thus further increasing the rate of urological complications.

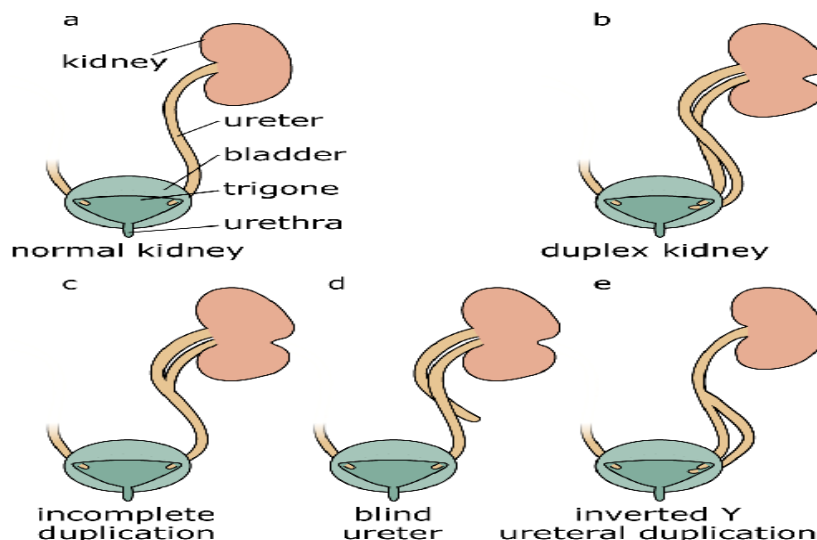
During the embryological process in the end of the 4th week ureter bud which rises from distal mesonephric duct unites with metanephric mesenchyme blastema and generates permanent kidney. Permanent kidney ascends to lumbar zone under adrenal glands in between 6th and 9th weeks [7].



Duplex collecting system occurs from two different ureter buds being generated from one Wolffian duct or incomplete fusion of ureter buds' upper and lower poles.

Normally ureteral orifices should be located on vesical trigone. Ureteral orifice being opened to bladder neck or other than vesical trigone is called ectopic ureter. More often in females (6:1). Ectopic orifice may open into vestibule (38%), urethra (32%), vagina (27%), uterus (3%)<sup>8</sup>. Ectopic ureter usually diagnosed at pediatric ages. Usual complaints are persistent and recurrent urinary tract infections, voiding dysfunctions and urinary incontinence [9].

It is often with duplex collecting system. Duplex collecting system classified as complete or incomplete duplication. If ureters have two separate pyelocalyceal systems but enters through two separate orifices in bladder it is called complete ureteral duplication, if ureters have two separate pyelocalyceal systems but enter through the same orifice it is called incomplete ureteral duplication. Two ureteric buds arising from mesonephric duct leads to formation of complete duplicate ureter whereas one bud that bifurcates during development leads to incomplete duplication of ureter. Complete ureter duplication has more clinical symptoms. It is more often in girls.



Duplex kidney can occur with other abnormalities of your urinary system. One common abnormality is an ureterocele, which occurs when the end of the ureter does not develop properly, and urine flow is obstructed. This results in a balloon-like swelling as urine builds up at the point where the ureter and bladder connect. In addition, urine can reflux back toward the kidney through the second ureter, which often has a weak valve because it joins the bladder in an abnormal location.

Duplicated ureter incidence is about 0.7% of healthy adult population & 2% to 4% of patients with urinary tract issues. The incidence rate of incomplete duplicated ureter is three times more than complete duplicated ureter, which is estimated to appear in about 1 in every 500 people. In this paper,

Citation: Dr Rahul Manchanda "Unusual Ureteric Abnormalities on Robotic Hysterectomy-Series of 2 Cases and Review of Literature" MAR Gynecology Volume 4 Issue 3

we report the detailed case of unilateral incomplete duplicated ureter which merged just proximal to the ureterovesical junction and another case of ectopic ureteric orifice.

Presence of various anomalies of the ureter is associated with increased risk of urinary tract infections and many other clinical complications. Advances in diagnostic imaging have resulted in an increase in the number of clinical cases reported.

In view of the fact that the equipment for cystoscopy is used during surgery for TLH/STLH and is sterile and available. Therefore, we conclude that cystoscopy at the end of surgery for TLH/STLH is an important evaluation and beneficial because of the following reasons: In patients presenting with postoperative flank pain, cystoscopy may prevent the need for further evaluation and expensive testing, and cystoscopy increases the surgeon's and the patient's confidence in the integrity of the urinary tract during the recovery period.

## **Case Reports**

### **Case Study-1**

A 47-year-old female was hospitalized in the parent institution in November 2022, due to abnormal uterine bleeding AUB(A)

Local examination

Per speculum-cervix and vagina healthy

Per vaginal- Ut 8 weeks, anteverted, mobile, uterine tenderness was present, bilateral fornices free

General and Systemic examination did not reveal any abnormality.

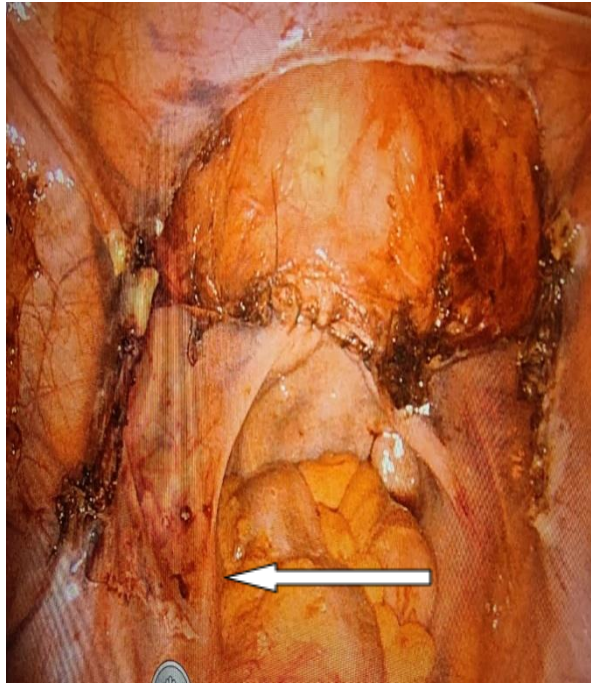
USG Abdomen revealed normal study with normal kidneys (no hydronephrosis), normal bladder.

USG Pelvis revealed bulky uterus with patchy adenomyosis and left ovarian avascular cyst with internal echoes? endometriotic? hemorrhagic cyst.

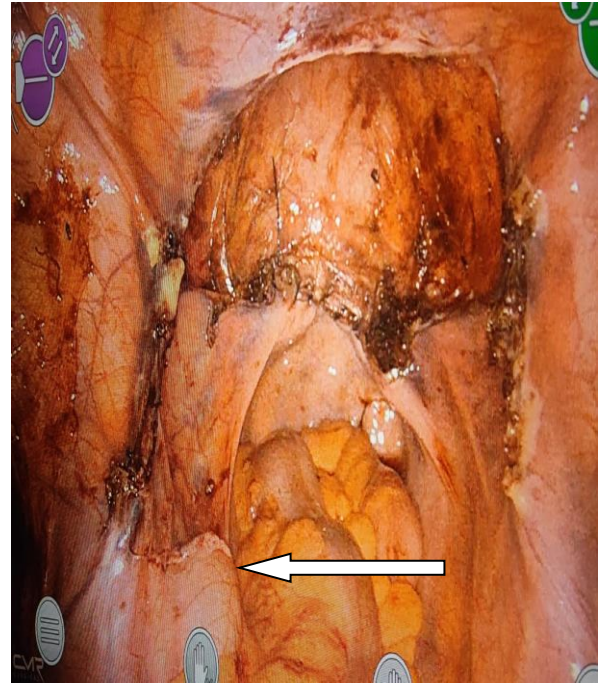
Routine investigations were performed including urine routine, RFTs which were normal.

Robotic hysterectomy with bilateral salpingoophorectomy was planned.

Intraoperatively, after vault closure ballooning of ureter was visualised. It was initially thought to be due to kinking of ureter so urologist was consulted. Cystoscopy was performed which showed bilateral efflux of urine through both the ureteric orifices.

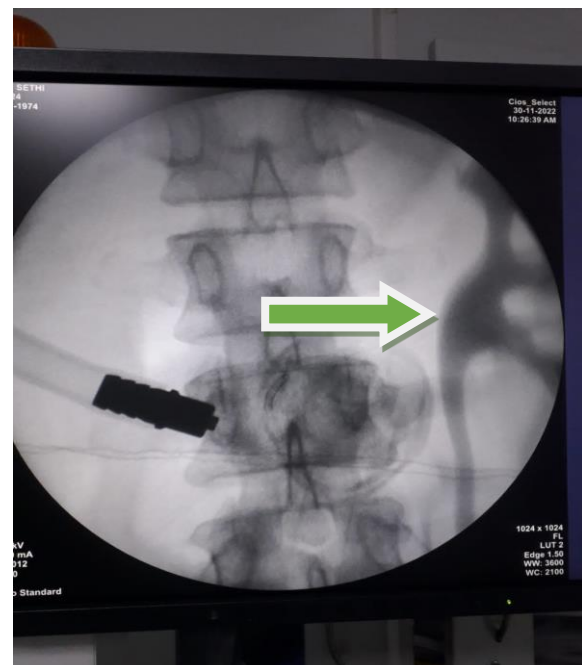
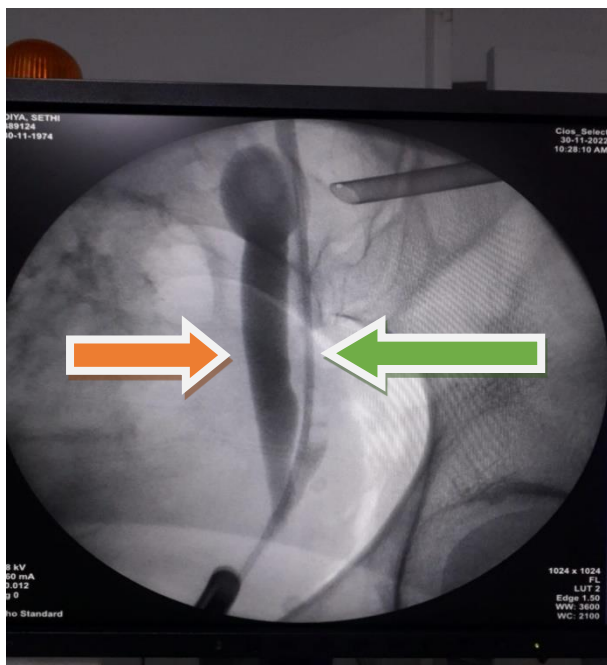


**Normal**



**Ballooning of Ureter**

Then retrograde pyelography was performed in OT, which revealed duplication of left ureter approximately 3cm from left ureteric orifice. The medial limb was dilated with blind end and lateral limb was draining left pelvicalyceal system normally. On right side RGP was normal.



**Fig:** RGP showing incomplete duplex ureter with blind medial limb which is dilated and left lateral limb which is draining left pelvicalyceal system normally.

During the hospitalization, the patient was treated conservatively with a positive clinical effect. Antibiotics were given and urine routine and culture were sent after 5 days. Patient was counselled regarding red flag signs like recurrent UTI, pain abdomen and was discharged in good condition and was advised regular follow up.

### **Case Study 2**

A 37-year-old patient presented to gynaecology department in August 2022 with history of heavy menstrual bleeding since 1 year (AUB-L).

General examination –anemic but vitals were stable

Systemic examination was normal

Per abdomen-uterus 18-20 weeks, midline scar (1 scs)

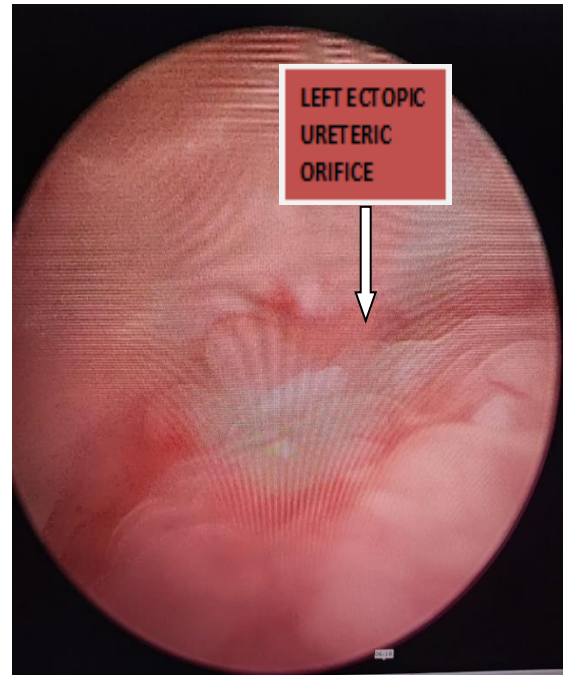
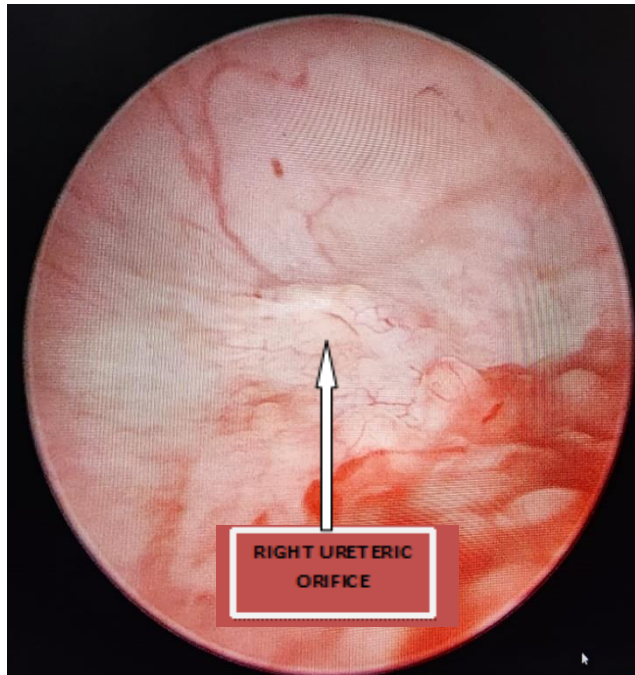
Per speculum-cervix and vagina healthy

Per vaginal-uterus 18-20 weeks, bilateral fornices free

Routine investigations were performed and 6 units PRBC were transfused preoperatively as patient was anemic (Hb-3.3g/dl). Usg revealed fibroid of 13\*11 cm

Robotic Hysterectomy with bilateral salpingectomy with preservation of ovaries was performed in september.1 unit blood was transfused intraoperatively.

Cystoscopy was performed as a part of procedure and we found left ectopic ureteric orifice opening in proximal urethra left side. Findings were further confirmed by urologist with additional finding of follicular cystitis.



## Result and Discussion

Ureteral bud develops as an outgrowth from the mesonephric duct and ascends with increase in vertical length till it fuses with metanephric blastoma, which gives rise to future adult ureter and kidney. Sun and colleagues suggested that if two ureteral buds form and one fails to contact with the metanephrogenic blastema, the blind ending bifid ureter with double ureteral orifices presents<sup>10</sup>. According to Dähnert, the prevalence of partial duplication of the ureter is three times more than complete duplication of the ureters as found on urograms. Dähnert reported that occurrence of complete duplication in first-degree relatives of a patient with complete duplication of the ureters is sixty times more likely [11]. Hascalik and associates reported that ureteral duplication may be genetically determined by an autosomal dominant trait with incomplete penetrance [12]. On the contrary, Bruno and colleagues said that ureteropelvic obstruction is more common when a duplex kidney exists and can be inherited as an autosomal dominant pattern [13]. In approximately 85% of subjects with complete double ureters, according to Weigert-Meyer rule, the orifices of the ureters draining the upper pole open inferior and medial to the orifice draining the lower pole of the kidney [14].

Duplex ureters if undiagnosed pre or intraoperatively can get injured during gynaecological surgeries. Alexander et al has reported a case of duplex ureter which got damaged during laparoscopic hysterectomy and was diagnosed postoperatively<sup>15</sup>. Surgeons while performing the surgeries in pelvic region should be well aware of such anomalies as congenital anomalies in genitourinary region has an

incidence of about 10% and duplication is one of the commonest anomalies of upper urinary tract. Though duplication of ureter may remain asymptomatic but it has a wide clinical significance especially in presence of yo-yo reflex, urogenital or gynaecological surgeries or laparoscopic procedures where it may get injured if not diagnosed earlier.

50% of ureteral injuries are diagnosed intra operatively without the use of cystoscopy [16]. This means that up to 75% of patients with bladder injuries can be discharged home with injuries that go unrecognized [17]. Conversely, with the use of intraoperative cystoscopy, Glimour found that 100% of ureteric and 80% of bladder injuries were identified prior to leaving the OR. This was systematic search of 47 studies where rates of ureteric and bladder injuries were found to be more when routine cystoscopy was performed than the studies without routine cystoscopy. The advantage of intraoperative diagnosis is the ability to repair the injuries at the time of surgery, thus, avoiding postoperative complications, medico-legal issues, and patient dissatisfaction [18].

Mahendran et al, reported a better prognosis when urinary tract injuries are recognized and addressed early [19]. Morozov et al study revealed 7 delayed (post-operative) diagnoses of ureteral injuries. Five of the seven delayed cases presented with ureterovaginal fistulas. Delayed recognition of these injuries can lead to infection, permanent renal impairment, ureterovaginal fistulas, need for percutaneous nephrostomy tubes, etc. Intraoperative diagnosis significantly decreases the risk of the aforementioned complications [17]. Wu and colleagues found that early detection of ureteral injury allowed for more conservative management of the injuries [20]. For instance, in cases that had delayed diagnosis (diagnosed on an average of 19 days postoperatively) five of the 8 patients required laparotomy compared to one of the 7 patients whose injuries was diagnosed intraoperatively or within 3 days post-operatively [17].

In a systematic review and meta-analysis by Teeluckdharry et al, the different rates of injury to the bladder and ureters by route of surgery showed the highest risk being during prolapse and incontinence procedures [21]. Otherwise, the rate of bladder injury was highest for laparoscopic and robotic hysterectomy with 6.9–16.5 injuries per 1000, and lowest for vaginal hysterectomy with only 5.1 per 1000. As to the ureters, the risk remained highest for laparoscopic and robotic hysterectomies with 3.1–4.1 per 1000, and lowest for the vaginal approach with 0.4 injuries per 1000 [22].

Prevention is the best treatment. It would be best for gynecologists to be aware of the places where the ureters and bladder are more likely to be injured in pelvic surgery. The knowledge of pelvic anatomy and urinary collecting system is of utmost importance. These injuries may also be prevented by appropriately selecting the patients for open versus minimally invasive surgeries. Even if all of the

necessary precautions are taken, injuries will still occur. Recognizing that it is our duty as surgeons to minimize the damage of these complications, routine cystoscopy is one of the best ways to complete this task.

In 2012, the American Association of Gynaecologic Laparoscopists recommended that routine cystoscopy be performed after all laparoscopic hysterectomies. Also, a study at the University of Michigan for implementation of a universal cystoscopy policy at the time of hysterectomy for benign indications was associated with a significant decrease in delayed postoperative urologic complications [23]. The authors concluded that a universal cystoscopy policy is a low-cost intervention that poses minimal risk to patients. A systematic review and meta-analysis that included 79 studies with 41,482 hysterectomies found that although universal cystoscopy increase intraoperative ureteric injury detection rates but did not decrease the incidence of delayed genitourinary injuries [21].

Risk of cystoscopy is extremely low and includes increased rates of urinary tract infection, bladder and urethral trauma, allergic reaction to intravenous dyes, increased cost, and operating room time [23]. In a decision analysis study to evaluate cost-effectiveness of cystoscopy, it was concluded that for universal cystoscopy to be cost-effective, the risk of ureteral and bladder injuries should be ~32% and 35% for ureteral and bladder injuries, respectively. The study concluded that cystoscopy would be better preserved to when the clinical index of suspicion for injury is high [24]. To bridge the cost barriers, some surgeons adopted the use of the 5 mm laparoscope for cystoscopy.

## **Conclusion**

Prevention, early detection and management of urinary tract injuries can significantly minimize the long-term complications and adverse outcome. So, to accomplish this task routine intraoperative cystoscopy is the best way. Surgeons early in their career may adopt universal cystoscopy until surgical experience is established in assessing the level of risk possible. Training gynaecologists to be competent in performing intra-operative cystoscopy can greatly reduce the amount of time used while waiting for urologist to perform the procedure which will take less than 15 minutes. At that stage, selective cystoscopy shall be utilized in cost effective manner such that when index of suspicion is high or when injury is detected, timely consultation with urologist may help alleviating long term complications by early diagnosis and treatment when needed.

## References

1. Dowling RA, Corriere JN Jr, Sandler CM. Iatrogenic ureteral injury. *J Urol* 1986; 133:912–915.
2. Carley ME, McIntire D, Carley JM et al. Incidence, risk factors and morbidity of unintended bladder or ureter injury during hysterectomy. *Int Urogynecol J Pelvic Floor Dysfunct* 2002; 13(1):18–21.
3. Cosson M, Lambaudie E, Boukerrou M et al. Vaginal, laparoscopic, or abdominal hysterectomies for benign disorders: immediate and early postoperative complications. *Eur J Obstet Gynecol Reprod Biol* 2001;98(2):231–236
4. Makinen J, Johansson J, Tomas C et al. Morbidity of 10,110 hysterectomies by type of approach. *Hum Reprod* 2001;16(7):1473–1478
5. Mathevet P, Valencia P, Cousin C et al. Operative injuries during vaginal hysterectomy. *Eur J Obstet Gynecol Reprod Biol* 2001;97(1):71–75
6. Visco AG, Barber MD, Myers ER. Early physician experience with laparoscopically assisted vaginal hysterectomy and rates of surgical complications and conversion to laparotomy. *Am J Obstet Gynecol* 2002;187(4):1008–1012
7. Kelly CR, Landman J. The netter collection of medical illustrations-urinary system. Elsevier Health Sciences 2012;5(2 Ed):34-6.
8. Fernbach SK, Feinstein KA, Spencer K, Lindstrom CA. Ureteral duplication and its complications. *Radiographics* 1997;17(1):109-7
9. Jednak R, Kryger JV, Barthold JS, González R. A simplified technique of upper pole heminephrectomy for duplex kidney. *J Urol* 2000;164(4):1326-8.
10. Sun MH, Kung KL, Tsai HM, Lin YM. Blind ending bifid ureter and its embryological correlation: a case report. *Chin J Radiol* 2002;27:263-6
11. Dahnert W. Radiology review manual. 6 ed. Philadelphia: Lipincott Williams Wilkins; 2007
12. Hascalik S, Celik O, Yilmaz M, Kinimlioglu H. Coexistent Uterine Myoma, Colon Adenocarcinoma Ureteral duplication in a young female patient. *Inonu Universitesi Tip Fakultesi Dergisi* 2004;1:181-3
13. Bruno D, Delvecchio FC, Preminger GM. Successful management of lower pole moiety ureteropelvic junction obstruction in a partially duplicated collecting system using minimally invasive retrograde endoscopic techniques. *J Endourol* 2000;14:727-30.

14. Prakash, Thimmiah R, Jayanthi V, Ajay KB, Deepak KS, Gajendra S. Double Ureter and Duplex System: A Cadaver and Radiological Study. *Urology Journal* 2011;8:145-48.
15. Alexander P. B. Dalzell, Richard G. Robinson, Kirsten M. Crooke. Duplex ureter damaged during laparoscopic hysterectomy. *Pelvipерineology* 2010; 29: 88.
16. AAGL Advancing Minimally Invasive Gynecology Worldwide. AAGL Practice Report: Practice guidelines for intraoperative cystoscopy in laparoscopic hysterectomy. *J Minim Invasive Gynecol* 2012; 19:407–11.
17. Morozov VV, Murphy L. Cystoscopy at the time of Hysterectomy. Does it make a difference?. *Austin J Obstet Gynecol* 2015; 2(1):1036.
18. Gilmour DT, Das S, Flowerdew G. Rates of urinary tract injury from gynecologic surgery and the role of intraoperative cystoscopy. *Obstet Gynecol* 2006;107:1366–72.
19. Mahendran HA, Praveen S, Ho C, Goh EH, Tan GH, Zuklifli MZ. Iatrogenic ureter injuries: eleven years experience in a tertiary hospital. *Med J Malaysia* 2012; 67:169-172.
20. Wu HH, Yang PY, Guang-Perng Yeh, Pan-Hsin Chou, Jui-Chang Hsu, Kuo-Cherng Lin. Detection of Ureteral injuries after Hysterectomies. *Journal of Minimally Invasive Gynecology* 2006; 13: 403-408.
21. Teeluckdharry B, Gilmour D, Flowerdew G. Urinary Tract Injury at Benign Gynecologic Surgery and the Role of Cystoscopy: A Systematic Review and Meta-analysis. *Obstet Gynecol* 2015; 126(6):1161-1169.
22. Khalife T, Fatchikov T. Intraoperative genitourinary injuries during a hysterectomy. *Journal of Gynecologic Surgery* 2021;37(3).
23. Chi AM, Curran DS, Morgan DM, Fenner DE, Swenson CW. Universal cystoscopy after benign hysterectomy. *Obstet Gynecol* 2016;127:369–375.
24. Cadish LA, Ridgeway BM, Shepherd JP. Cystoscopy at the time of benign hysterectomy: A decision analysis. *Am J Obstet Gynecol* 2019;220:369.e1–e369.e7.