



## Acute Heart Failure and Deep Venous Thrombosis Associated with Septic Abortion. Case Report and Literature Review

Carolina F. Kandel-Varsano <sup>\*1</sup>, Carlos Lopez-Valencia <sup>1</sup>, Jose Rogelio Vazquez-Gonzalez <sup>2</sup>,  
Sonia Vorhauer-Ramirez <sup>1</sup>, Alvaro E. Peña-Jimenez <sup>1</sup>

1. Obstetrics and Gynecology, Centro Medico ABC, Mexico City

2. General Surgery, Urology, Centro Medico ABC, Mexico City

**Corresponding Author: Carolina F. Kandel Varsano**, Obstetrics and Gynecology, Centro Medico ABC, Mexico City.

**Copy Right:** © 2023 Carolina F. Kandel Varsano, This is an open access article distributed under the Creative Commons Attribution License, which permits unrestricted use, distribution, and reproduction in any medium, provided the original work is properly cited.

**Received Date: April 04, 2023**

**Published Date: April 20, 2023**

**Abstract**

*Septic abortion with multisystem involvement is associated with significant morbidity and mortality. We present the case of a 42-year-old woman who developed thrombosis in the right great saphenous vein, severe acute mitral insufficiency and heart failure, ten days after undergoing manual uterine aspiration for an incomplete abortion, without prophylactic antibiotic administration. She required management at the intensive care unit with use of vasopressors, systemic antibiotics, and anticoagulant treatment. Septic abortion with life-threatening systemic complications is rarely encountered. Prompt surgical management and the use of broad-spectrum prophylactic antibiotics are indicated to reduce the risk of a systemic complication. However, the use of antibiotics based only on the diagnosis of incomplete early pregnancy loss has not been found to reduce infectious complications if unsafe induced abortion is not suspected. The benefit of antibiotic prophylaxis for the medical management of early pregnancy loss is unknown; however, recent recommendations suggest its use.*

**Categories:** Cardiology, Obstetrics/Gynecology, Infectious Disease

**Keywords:** abortion, venous thrombosis in sepsis, incomplete abortion, prophylactic antibiotics in obstetrics, septic abortion.

**Introduction**

The American College of Obstetricians and Gynecologists (ACOG) defines early pregnancy loss as a nonviable intrauterine pregnancy and empty gestational sac or a gestational sac containing an embryo or fetus without fetal heart activity within the first 12.6 weeks of gestation. Spontaneous miscarriage occurs in 10% of all pregnancies, 50% of these are due to fetal chromosomal abnormalities [1]. Early pregnancy loss comprises many entities, including incomplete, inevitable, or complete spontaneous abortion, anembryonic gestation and fetal demise or missed abortion [2].

The diagnosis of early pregnancy loss may be suspected based on symptoms, but is usually made by transvaginal ultrasound, or serial beta human chorionic gonadotropin levels [2].

Ultrasonographic findings that are characteristic of pregnancy failure include crown-rump length of 7 mm or greater and no fetal heartbeat, mean sac diameter of  $\geq 25$  mm and no embryo, absence of embryo with heartbeat 2 weeks or more after a scan that showed a gestational sac without a yolk sac and/or absence of embryo with heartbeat 11 days or more after a scan that showed a gestational sac with a yolk sac [1].

Management may be expectant, medical, or surgical. Expectant management is successful in up to 80% of miscarriages within less than 8 weeks that have begun with symptoms such as tissue passage or ultrasound findings consistent with incomplete expulsion [3]. Medical management is often a viable treatment, except for patients that present infection, hemorrhage, severe anemia, or bleeding disorders. Different regimens with misoprostol and mifepristone have been proposed, with ultrasound follow-up 7 to 14 days after the initial treatment to confirm complete expulsion. Other alternative regimens include methotrexate and tamoxifen among others; however, they are less common in daily practice [3]. Surgical uterine evacuation is indicated in cases of hemorrhage, hemodynamic instability, or signs of infection. A single dose of 200 mg of doxycycline 1 hour before surgical evacuation is recommended to prevent infection [1].

A septic abortion defined as an infection of the products of conception of a previable pregnancy. The infection is centered in the placenta, with the potential risk of spreading to the uterus, causing pelvic infection or systemic infection and septicemia and potential damage of distant organs. This accounts for a case fatality ratio in Latin America to 10 cases per 100,00 abortions [4]. Some women undergoing a septic abortion may not originally present signs and symptoms corresponding sepsis criteria, other patients develop sepsis and multiorgan system failure secondary to initial medical or surgical treatment [5].

The objective of the case is to present the potential risks from retained products of conception when a spontaneous or induced abortion is treated medically without follow up to ensure adequate expulsion.

### **Case Presentation**

We present the case of a 42-year-old multiparous female patient that presents to the emergency department with oppressive chest pain without irradiation, dyspnea at rest, dizziness, pain in both pelvic extremities, predominantly the right leg, edema ++/+++. Bradycardia of 35 beats per minute on admission with blood pressure 94/65 mmHg, a single dose of atropine 0.5 mg was administered with improvement of symptoms and heart rate of 87 beats per minute.

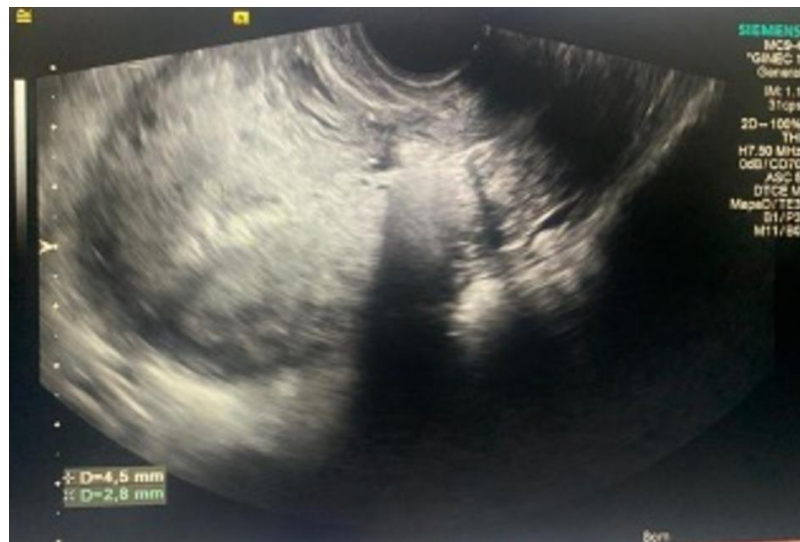Ten days prior, she was treated with misoprostol after a nonviable pregnancy diagnosis, after which she presented abundant transvaginal bleeding for which she underwent an in office manual uterine aspiration. After the procedure she was sent with ambulatory analgesic treatment. Three days after the office procedure she began with an unquantified rise in temperature and general discomfort, she presented to a different emergency department with fever and discomfort/malaise; dilation and curettage was performed and began antibiotic management (gentamicin, clindamycin, and metronidazole) + prophylactic enoxaparin 40 milligrams every 24 hours.

Important medical history includes allergy to penicillin and iodine, three prior cesarean sections, and multiple surgeries in lower right extremity secondary to dog bite.

At her arrival, during physical exploration, the patient was alert, oriented, pale, with signs of dehydration. Grade I jugular engorgement. Rhythmic yet hypodynamic heart sounds with the presence of bradycardia, mitral holosystolic murmur intensity III/IV with irradiation to the axilla. R2 with wide splitting. Lung fields with vesicular murmur with bilateral pleural effusion syndrome predominantly right, left subscapular rales. Abdomen soft, depressible, not painful on palpation, normal active peristalsis, without signs of peritoneal irritation. Lower extremities with right circumference of 34 centimeters and left 32.5 centimeters, bilateral pedal pulses present, bilateral edema ++/+++, without the presence of thermal or color changes. Homans and Ollow signs were positive in the right extremity. Neurologically Glasgow 15.

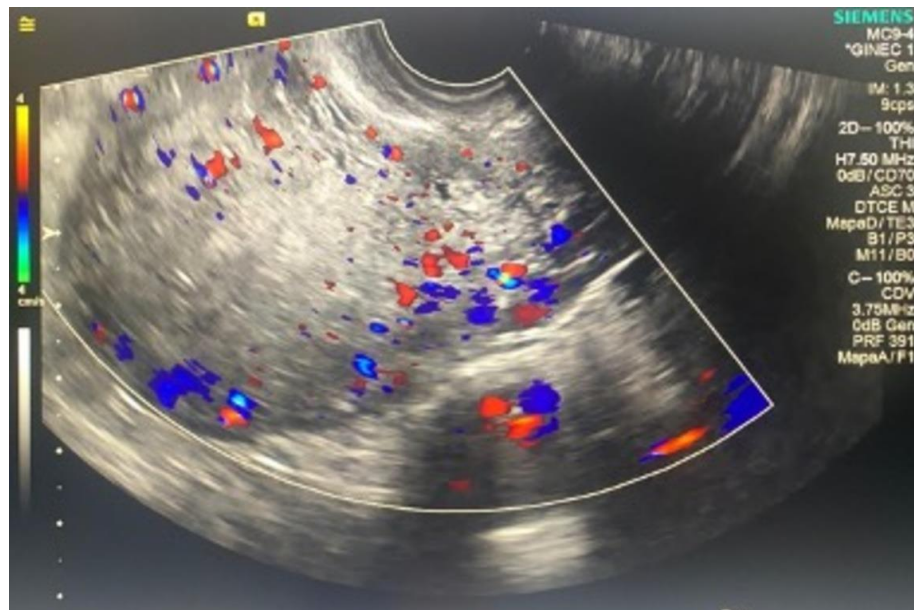
Relevant laboratory findings were normochromic normocytic anemia with hemoglobin of 9.5 g/dL, 14.42 10<sup>3</sup>/μL leucocytes at the expense of neutrophils, coagulation times within normal parameters, D-dimer 5389 ng/mL, N-terminal (NT)-pro hormone natriuretic peptide (NT-proBNP) 4201 pg/mL, normal troponin levels, erythrocyte sedimentation rate 25 mm/hr, C-Reactive Protein 8.3 mg/dL (0-0.5 mg/dL), Procalcitonin 1.62 ng/mL (0-0.5 ng/mL).

Transvaginal ultrasound with endometrial cavity areas with rarefaction phenomenon were observed, the presence of ovum-placental remains was ruled out (Figures 1 and 2).



**Figure 1:** Ultrasound of endometrial cavity

Ultrasound of endometrial cavity with areas with rarefaction phenomenon were observed with endometrial lining of 4.5 mm



**Figure 2:** Doppler ultrasound of endometrial cavity.

Doppler ultrasound of endometrial cavity ruling out the presence of ovum-placental remains.

Bilateral venous and arterial Doppler of the pelvic limbs with thrombosis in the right great saphenous vein towards the confluence with the common femoral vein.

Portable chest x-ray with bilateral decreased lung volume, predominantly parahilar septal thickening, bilateral pleural effusion, bibasal atelectasis concluding data of overload.

Transthoracic echocardiogram can be summarized as normal with left ventricular function 63% with normal wall motion and diastolic function. Mitral valve was redundant, and a jet of insufficiency reached the roof of the atrium in the posterior direction of a severe degree. Mild tricuspid regurgitation. Mild pericardial effusion. Thrombi were not observed.

After the previously described clinical, laboratory and imaging findings she was diagnosed with septic abortion + thrombosis in the right great saphenous vein + severe acute mitral insufficiency + acute heart failure of valvular etiology NYHA III according to AHA guidelines.

Vaginal swabs positive for Ureaplasma Urealyticum pansensitive, blood swabs were negative, and gastrointestinal film-array was positive for Enteroaggregative Escherichia coli.

She was transferred to the intensive care unit and began nitroglycerin to reduce left ventricular afterload. Antibiotic therapy was changed to meropenem, and enoxaparin was increased to 60 milligrams per day. After body swab results, azithromycin 1 gram 1 dose was given, and she began tigecycline 50 mg every 12 hours and metronidazole 500 mg every 8 hours.

The patient was discharged 4 days after admission, hemodynamically stable, antibiotic scheme until completing 14 days and external follow-up by Vascular Surgery, Gynecology and Cardiology.

## **Discussion**

Given the patients' history, the most reliable conclusion is retained products of conception secondary to the initial medical management, and subsequently an intrauterine passage of microorganisms at the time of the in-office surgical procedure. However, there were no vaginal swabs taken by the physician prior to either medical or surgical management which could also propose a previous vaginal infection that entered the uterine cavity upon cervical dilation.

A Cochrane review of 2007 studying antibiotics for incomplete abortion states that there is no evidence to either recommend or to abandon the use of prophylactic antibiotics in women with an incomplete abortion, recommending an urgent need to find out whether antibiotics should be routinely used in these cases. At this time, randomized clinical trials strongly recommended not to use antibiotics [6].

This being said, the Society of Obstetricians and Gynaecologists of Canada (SOGC) guidelines strongly recommends the use of doxycycline, metronidazole or beta-lactams in women undergoing surgical abortion with a high level of evidence based on two systematic reviews and meta-analyses of 19 randomized controlled trials that showed that antibiotic prophylaxis for first trimester spontaneous abortion reduces infection, with relative risks of 0.58 (95% CI 0.47-0.71) and 0.59 (95% CI 0.46-0.75) respectively [7].

In 2012, Cochrane Library published a perioperative review of antibiotics to prevent infection after first trimester abortion. This review argued that cervical instrumentation may introduce bacteria from vagina and cervix into the endometrial cavity and potentially cause post-abortion upper genital tract infection. They concluded that the relative risk of infection in women who received prophylactic antibiotics was 0.59 (CI 95% 0.46 to 0.75) [8].

Nevertheless D. Lissauer et al. concluded after a double-blind, placebo-controlled, randomized trial investigating whether antibiotic prophylaxis before surgery to complete a spontaneous abortion would reduce pelvic infection among women and adolescents in low-resource countries. Where they randomly assigned patients to a single preoperative dose of 400 mg of oral doxycycline and 400 mg of oral metronidazole or identical placebos. And concluded that antibiotic prophylaxis before miscarriage surgery did not result in a significantly lower risk of pelvic infection [9]. A second editorial regarding this controversial issue concluded that given the risks associated with pelvic infection, there exists reasonable support for prescribing prophylactic antibiotics in low- and middle-income countries, adjusting to antibiotic resistance in certain regions [10].

Specifically, regarding medical abortions, the overall frequency of reported infections was <1% (0.92%), most commonly being endometritis and genital tract infection. However, rare cases of *Clostridium sordelli* sepsis have been reported requiring hospitalization and intensive care unit [11].

Abortion and Clostridial Toxic Shock Syndrome cases have been published for many years, and it has recently been called to attention since 2005 when the Centers for Disease Control and Prevention published a series of four deaths due to this entity. The most identified pathogens have been *Clostridium sordelli* and *Clostridium perfringens* following medical abortion with misoprostol and/or mifepristone. Clostridial infection is rare, it can follow a medical abortion involving ascending spread of microorganisms colonizing vagina, endometrium, and posterior proliferation. The toxins derived from these pathogens find their way into the vascular system resulting in fatal toxic shock syndrome [12]. Symptoms associated with toxic shock syndrome include abdominal pain, hypotension, tachycardia, hemoconcentration and acute neutrophilia without fever [13]. Some studies suggest

susceptible treatments with beta-lactams and clindamycin, the latter may even suppress toxin synthesis and diminish its systemic effects [14].

The pathophysiology of a septic abortion begins the invasion of vaginal bacteria towards the uterus, usually preceded by uterine instrumentation or prolonged uterine bleeding. These bacteria penetrate the intervillous spaces of the placenta, which is in direct contact with the decidua, and within 6 to 12 hours may invade myometrium. This infection could cause tissue necrosis which diminishes antibiotic penetrance and effectiveness. In these cases, the source must be removed, either by dilation and curettage or hysterectomy if the infection reaches the uterus. Over 60% of patients with intrauterine infections present bacteremia. The presence of toxins produced by *Clostridium* species and group A streptococci create an autoimmune response leading to systemic disease and multiple organ failure [4].

The World Health Organization (WHO) delineates maternal sepsis as a “life-threatening condition defined as an organ dysfunction caused by an infection during pregnancy, delivery, puerperium, or after an abortion”. Pregnant patients with sepsis have a dysfunction and mortality rate between 8 to 14%. Some symptoms such as tachycardia and peripheral vasodilation due to estrogen levels may be disguised as physiological adaptations to pregnancy, which also characterize sepsis and septic shock due to release of pro-inflammatory mediators [15].

Sepsis, in combination of hypotension and shock is a risk factor for venous thromboembolism VTE. It is thought to be caused by multiple factors, some of them including immobilization, activation of thromboinflammatory pathways, disseminated intravascular coagulation, and venous stasis, all leading to a hypercoagulable state. The incidence of VTE associated with sepsis despite the use of thromboprophylaxis is 37.2%, future research is necessary for prophylactic measures, however it is recommended for patients to begin a combination of heparin and mechanical devices to reduce this risk [16].

Microbes causing septic abortion include bacteria arising from vaginal flora, anaerobic bacteria associated with insecure abortions. Toxin-producing bacteria such as *Clostridium* spp, group A streptococci, *Escherichia coli* and *Staphylococcus aureus*. These bacteria produce toxins that are strong enough to cause endothelial damage and damage the function of distant organs such as lungs, kidneys, heart, and the coagulation system.

*Clostridium perfringens* has been isolated 1% in vagina, 10% in rectum of young women and has been found in 5% of septic abortions [4].

In 2018 Carlsson et al. performed a study that included all women who underwent an induced abortion. Medical abortion for pregnancies <12 weeks' gestation was performed with oral mifepristone 200 mg single dose to stop fetal development. After three days, the patient was given 800 mcg of vaginal misoprostol for the uterus to contract and expel the forming tissue. Pregnancies after 12 weeks require inpatient treatment, protocol considers an initial dose of oral mifepristone 200 mg, followed by 800 mcg of vaginal misoprostol, following with oral misoprostol 400 mcg every 3 hours until expulsion. Often, medical abortions >12 weeks require vacuum curettage as part of the normal course. A vacuum curettage in these cases is not considered a complication nor is it contemplated as treatment failure [17]. Vaginal cultures in search of Chlamydia, Gonorrhea, Mycoplasma, and bacterial vaginosis prior to medical abortions were taken to all patients, and they assessed complications of abortion, such as uterine bleeding, infection, or incomplete abortion, in women who contacted the gynecologic clinic within 30 days of the procedure [17]. The most common procedures were as follows: medical abortions < 12 weeks (74.7%), surgical abortions (17.5%) and medical abortions > 12 weeks (7.8%). Complications were recorded in 333 (6.7%) of the total cases. The most common complication associated to medical abortions were incomplete abortions in patients < 12 weeks' gestation. Women who screened positive for one or more bacteria and received

antibiotics, 1.4% developed a postabortion infection. However, those who tested negative, 1.7% developed infectious complications; concluding that both groups of women who tested positive on bacteria screening and received antibiotics experienced in a similar proportion postabortion infections as women who tested negative [17]. The clinical presentation may vary because, since its location is inside the uterus, its severity can be masked. Most patients have a history of fever and transvaginal bleeding, many present with chills and abdominal pain. The clinician should always suspect in patients with a history of uterine procedures, prolonged vaginal bleeding, and prolonged fever. Findings that suggest sepsis include high fever, prostration, tachycardia with or without respiratory distress, hypotension, and low urine output [4].

Physical exploration also varies among patients, non-acute abdominal tenderness is usually present. Vaginal and cervical exploration may include vaginal or cervical trauma, foul-smelling or purulent cervical discharge, bimanual exploration with cervical and/or uterine tenderness [4].

The following studies are suggested for patients with cervical abortion: blood analysis that includes complete blood count, lactic acid level, coagulation studies, renal function studies, blood type to check for Rh(D)-negative and determination of hemolysis. Leucocyte count above 20 thousand indicates severe infection and could be found above 50 thousand when there is production of toxins. Blood

culture and cervical and/or culture of the products of conception. Transvaginal ultrasound to detect retained products of conception. A complete abortion usually results in a linear endometrium of < 8 mm, and/or abdominal and pelvic radiography or tomography to detect free air in the abdomen and/or gas in myometrium [4].

Initial steps in treating a septic abortion after proper identification of the entity include fluid reposition, empiric antibiotic therapy and consider the need for vasopressors. The fetoplacental barrier makes bacteria stay within the maternal villous space and not in the fetal space, which in turn stimulates a robust maternal response. Patients who present with severe sepsis and shock have a mortality rate of 33 to 50%. Clinical response within 6 hours after intravenous fluid management and antibiotics is needed to perform surgical evacuation of uterine product remains [4].

Empirical antibiotic treatment choices for septic abortion include: first line therapy gentamicin 5 mg/kg/d + clindamycin 900 mg every 8 h +/- ampicillin and second line therapy ampicillin (2 g every 4 h) and gentamicin with metronidazole (500 mg every 8 h). When choosing an antibiotic regimen, consider *Clostridium* and *Streptococcus pyogenes* are usually sensitive to penicillin, always include anaerobic coverage, if there is no abscess, intravenous antibiotics can be discontinued after 48 hours if there is clinical improvement. Adding clindamycin to treatment lowers levels of *S. aureus* and *Streptococcus pyogenes* toxins [3].

The use of prostaglandins is contraindicated in patients with sepsis because it elevates body temperature. Instead, high doses of oxytocin, a Foley catheter or Hegar dilators may be used to open the cervix and proceed to uterine evacuation [18].

Given that septic abortions are usually multimicrobial, the current empiric antibiotic therapy is recommended to target gram-positive, gram-negative, and anaerobic organisms. Early diagnosis as well as cultures of appropriate specimen should be imperative in these cases. Septic abortion requires a multidisciplinary team, prompt fluid resuscitation, hemodynamic stabilization, intensive care, and may even require surgical removal of uterus and/or Fallopian tubes [19]. Signs and symptoms associated with serious infection such as flu-like symptoms, tachycardia, severe abdominal pain, or general malaise with or without fever, which are usually accompanied by hemoconcentration, leukocytosis and could rapidly progress to refractory hypotension and death [1,20] that when not treated promptly such as the case previously presented, could be fatal. The concept of poor clinical condition for surgery does not apply in this entity, because timely hysterectomy could save the patient's life.

Indications include clinical worsening after uterine evacuation, peritonitis, pelvic abscess or sepsis shock, acute respiratory distress, intravascular disseminated coagulation, or the need for mechanical ventilation.

## Conclusions

Septic abortion with life-threatening systemic complications is rarely encountered. Surgical management and the use of broad-spectrum prophylactic antibiotics are indicated to reduce the risk of a systemic complication. However, the use of antibiotics based only on the diagnosis of incomplete early pregnancy loss has not been found to reduce infectious complications if unsafe induced abortion is not suspected. The benefit of antibiotic prophylaxis for the medical management of early pregnancy loss is unknown, however there is an urgent need to clarify whether antibiotics should be routinely used. Therefore, the use of a prophylactic antibiotic for medical abortion is not recommended given its low incidence (0.9%), and for surgical abortion it is currently a Level C recommendation with a single dose of preoperative doxycycline, urging clinicians to be aware of signs and symptoms that could indicate a more serious infection.

## References

1. American College of Obstetricians and Gynecologists. Early pregnancy loss. ACOG Practice Bulletin No. 200 . Obstet Gynecol. 2018, 132:197-207. 10.1097/AOG.0000000000002899
2. Quenby S, Gallos ID, Dhillon-Smith RK, et al.: Miscarriage matters: the epidemiological, physical, psychological, and economic costs of early pregnancy loss. The. Lancet. 2021, 397:1658-1667. 10.1016/S0140-6736(21)00682-6
3. Soon JA, Costescu D, Guilbert E: Medications Used in Evidence-Based Regimens for Medical Abortion: An Overview. Journal of Obstetrics and Gynaecology Canada. 2016, 38:636-645. 10.1016/j.jogc.2016.04.005
4. Eschenbach DA: Treating Spontaneous and Induced Septic Abortions . Obstet Gynecol. 2015, 125:1042-1048. 10.1097/AOG.0000000000000795
5. Kishan R, Wesley S, Barnett G, Kauffman RP: Septic abortion complicated by infective endocarditis, mitral valve vegetation, and septic and reactive arthritis: A case report. Case Rep Womens Health. 2022, 34:00398. 10.1016/j.crwh.2022.e00398

6. May W, Gülmezoglu AM, Ba-Thike K: Antibiotics for incomplete abortion. Cochrane Database of Systematic Reviews. 2007, 17:001779. 10.1002/14651858.CD001779.pub2
7. Costescu D, Guilbert É: No. 360-Induced Abortion: Surgical Abortion and Second Trimester Medical Methods. Journal of Obstetrics and Gynaecology Canada. 2018, 40:750-783. 10.1016/j.jogc.2017.12.010
8. Low N, Mueller M, van Vliet HA, Kapp N: Perioperative antibiotics to prevent infection after first-trimester abortion. Cochrane Database of Systematic Reviews. 2012, 3:005217. 10.1002/14651858.CD005217.pub2
9. Lissauer D, Wilson A, Hewitt CA, et al.: A Randomized Trial of Prophylactic Antibiotics for Miscarriage Surgery. N ENGL J MED. 2019, 380:1012-1021. 10.1056/NEJMoa1808817
10. Serwadda DM: To Give or Not to Give Prophylactic Antibiotics for Miscarriage Surgery? New England Journal of Medicine. 2019, 380:1075-1076. 10.1056/NEJMe1900872
11. Shannon C, Brothers LP, Philip NM, Winikoff B: Infection after medical abortion: A review of the literature. Contraception. 2004, 70:183-190. 10.1016/j.contraception.2004.04.009
12. Soper DE: Abortion and Clostridial Toxic Shock Syndrome. Obstetrics & Gynecology. 2007, 110:970-971. 10.1097/01.AOG.0000288224.47104.7b
13. Meites E, Zane S, Gould C: Fatal Clostridium sordellii Infections after Medical Abortions. New England Journal of Medicine. 2010, 363:1382-1383. 10.1056/NEJMc1001014
14. Lee E, Sheth C, Estrada O, Eshaghian P: A Classic Case of Toxic Shock Syndrome Due to a Not So Classic Organism, Clostridium Sordellii. Chest. 2017, 152:257. 10.1016/j.chest.2017.08.283
15. Escobar MF, Echavarría MP, Zambrano MA, Ramos I, Kusanovic JP: Maternal sepsis. Am J Obstet Gynecol MFM. 2020, 2:100149. 10.1016/j.ajogmf.2020.100149
16. Kaplan D, Casper TC, Elliott CG, et al.: VTE Incidence and Risk Factors in Patients With Severe Sepsis and Septic Shock. Chest. 2015, 148:1224-1230. 10.1378/chest.15-0287
17. Carlsson I, Breeding K, Larsson PG: Complications related to induced abortion: a combined retrospective and longitudinal follow-up study. BMC Womens Health. 2018, 18:158. 10.1186/s12905-018-0645-6
18. Stubblefield PG, Grimes DA: Septic Abortion. New England Journal of Medicine. 1994, 331:310-314. 10.1056/NEJM199408043310507

19. Udoh A, Effa EE, Oduwole O, Okusanya BO, Okafo O: Antibiotics for treating septic abortion. Cochrane Database of Systematic Reviews. 2016;2016, 10.1002/14651858.CD011528.pub2
20. American Journal of Obstetrics and Gynecologists' Committee on Practice Bulletins: Medication Abortion Up to 70 Days of Gestation. *Obstetrics & Gynecology*. 2020, 136:31-47. 10.1097/AOG.0000000000004082