



## **Brain Abscess Complicating Pregnancy with Good Prognosis:**

### **A Case Report**

Sonia Arnowalt MS, DGO, DNB, DMAS, MNAMS, MRCOG <sup>\*1</sup>, Faiz Zaman MD, FRCOG <sup>2</sup>,

Shumaila Khan FRCPS, MRCOG <sup>3</sup>, Satish Krishnan MCH, DNB Neurosurgery <sup>4</sup>

*1. Wrexham Maelor Hospital, Betsi Cadwaladr University Health Board, North Wales, United Kingdom.*

*2,3. Al Qassimi Women's and Children's Hospital, Ministry of Health, United Arab Emirates.*

*4. Al Qassimi Hospital, Ministry of Health, United Arab Emirates.*

**\*Correspondence to:** Sonia Arnowalt, Wrexham Maelor Hospital, Betsi Cadwaladr University Health Board, 43 Huntsman Corner, Wrexham, LL12 7 UE, North Wales, United Kingdom.

### **Copyright**

© 2023 **Sonia Arnowalt**. This is an open access article distributed under the Creative Commons Attribution License, which permits unrestricted use, distribution, and reproduction in any medium, provided the original work is properly cited.

**Received: 24 July 2023**

**Published: 10 August 2023**

**Abstract**

*Brain abscess is an extremely rare but potentially life-threatening condition in pregnancy [1]. Early recognition, proper evaluation, and timely treatment are highly warranted for optimal outcomes. Among reported cases of brain abscess in pregnancy, most patients have shown a good neurological outcome. In this paper, we report a case of brain abscess complicating pregnancy diagnosed at 27 weeks of gestation, presented with weakness of the right side of the body and speaking difficulty. Imaging revealed a deep-seated abscess with extensive edema in the left frontal and parietal lobes. She underwent left frontotemporal parietal craniotomy and drainage of pyogenic abscess along with a broad-spectrum antibiotic. She had a normal vaginal delivery at 40 weeks of gestation. The woman and the baby showed a good prognosis without any neurological complications.*

**Keywords:**

*Brain abscess, pregnancy, prognosis*

**Introduction**

Brain abscess (BA) is defined as a localized area of suppuration with pus collection in the parenchyma of the brain or meninges, caused by bacterial or fungal infection. The common predisposing factors are pre-existing infection, foreign body, trauma, or immunosuppression. The pathogenic organism enters the brain from the local spread of infection in the ear, nasal sinuses, and tooth or through penetrating injuries and hematogenous spread. The most common sites are the frontal and temporal lobes followed by the cerebellum. The clinical presentation can vary depending on the size and location of the abscess. The common symptoms encountered are persistent headaches, seizures, mental status changes, and focal neurological deficits. Cranial imaging modalities like computed tomography (CT) or magnetic resonance imaging (MRI) aid in the diagnosis which can be confirmed by aspiration of purulent material. The principle of management is surgical drainage under broad-spectrum antibiotic cover, treatment of sequelae, and eradication of the primary source of infection.

The incidence of BA varies from 1-2% of all intracranial space-occupying lesions in developed countries to 8% in developing countries. Though very rare, pregnancy being an immunosuppressive state, the women can deteriorate fast with poor prognosis for both mother and baby, if the condition has not been diagnosed and treated promptly [1]. Results are directly related to the sensorium at the time of presentation. Though potentially curable, BA possesses diagnostic and therapeutic challenges. With diagnostical and technical advancement, adequate drainage of brain abscesses, even with minimally invasive surgery, offers good outcomes.

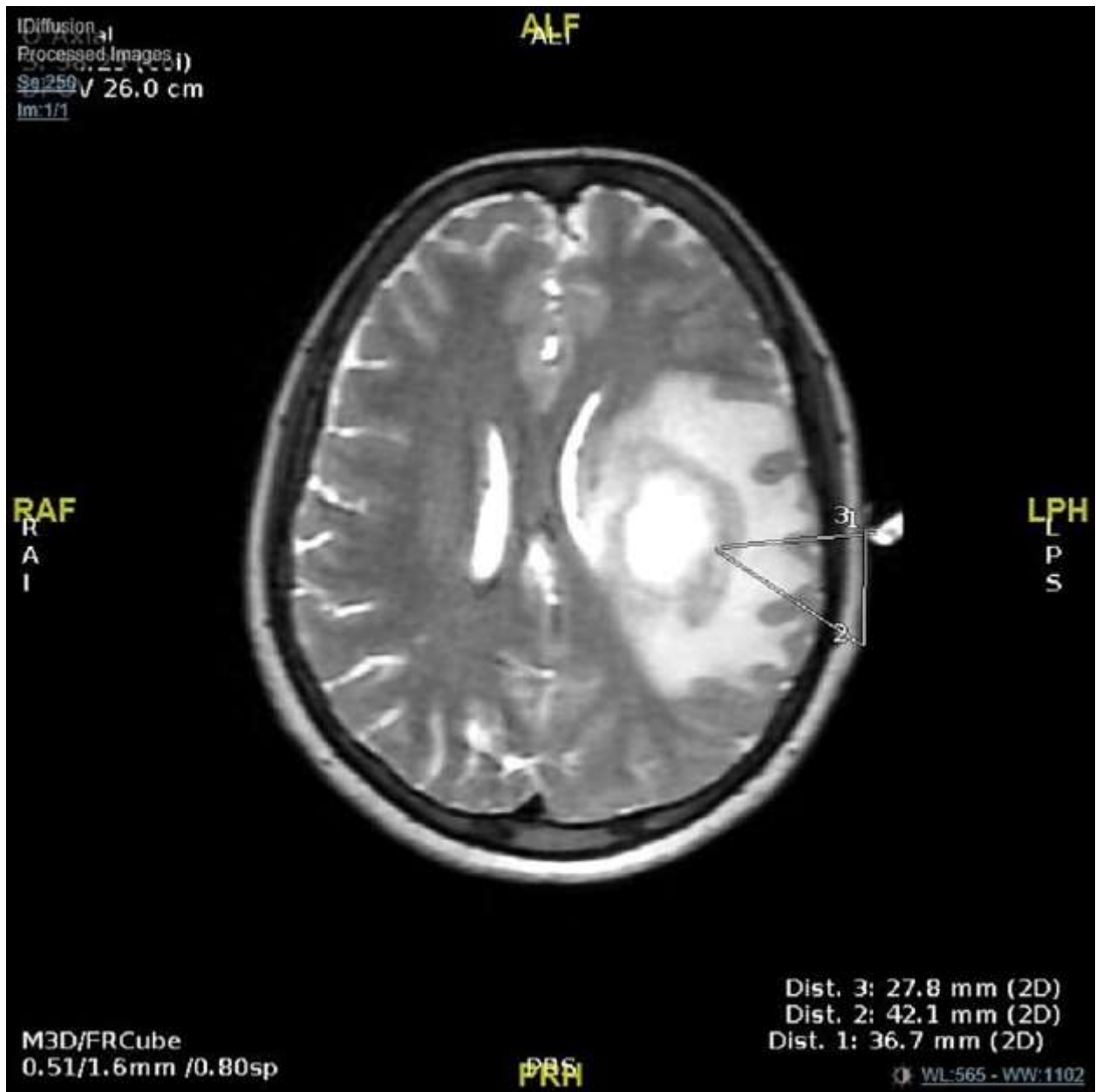
## **Case Presentation**

A 30-year-old receptionist, the mother of a 13-year-old child, was brought to the accident and emergency (A&E) department with weakness of the right side of the body and speaking difficulty at 27 weeks of gestation. She had come to A&E two days before with the same complaints but signed leave against medical advice. Since then, her weakness has been progressive. She had no history of headaches except for the last 2-3 days. There was no history of trauma, fever, recent travel, infections, major illness, or contact with animals. She was allergic to chicken and seafood, however, there was no documented drug allergy. She was not on any chronic medications. She had insignificant medical, surgical, and family histories as well as no history of substance abuse or smoking.

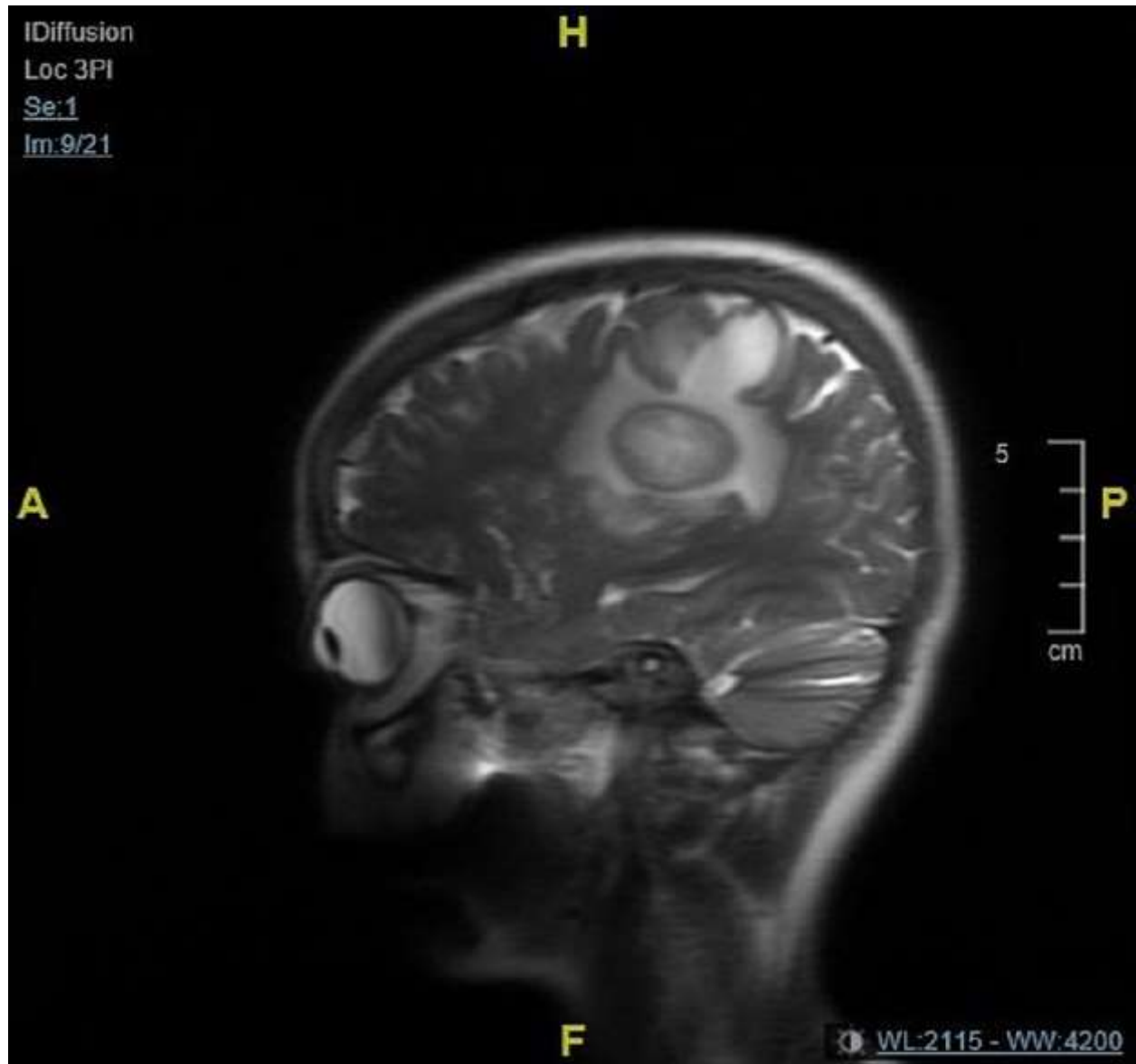
On initial evaluation, she was fully conscious and oriented with a Glasco Coma Scale (GCS) of 15/15. Her pupils were equal and reacting and extraocular muscles showed a full range of motion without nystagmus. She had global dysphasia and right facial weakness. This was accompanied by right hemiparesis with the upper limb and lower limb having grade 1 and grade 3-4 power respectively. Her sensations were diminished on the right upper limb. However, her left upper and lower limbs had normal power and sensations. The examination did not reveal any cerebellar signs. She was afebrile and tachycardic with a blood pressure of 105 and 67 mm of mercury.

She was admitted for evaluation and definite treatment. Since she was pregnant, an MRI study without contrast was done. As shown in Figure 1, it revealed a well-circumscribed intra-axial lesion in the left parietal region with a wall on the motor strip with significant perilesional edema causing mass effect. Figure 2 depicts that edema was extending to the left basal ganglia, thalamus, external capsule, midbrain, and left

cerebral peduncle. The T2W center of the lesion was hyper-intense, DW-restricted, ADC-low. MRI reported the brain abscess to be measuring about 3.8x3.2x3.2 mm at its maximal diameters.



**Figure 1:** Magnetic resonance diffusion-weighted images of the brain abscess. Axial images show a large abscess in the left parietal lobe with extensive edema.



**Figure 2:** Magnetic resonance diffusion-weighted images of the brain abscess. The sagittal view shows a large abscess in the left parietal lobe with extensive edema.

After admission, though she had a mild headache, her clinical features improved. Her speech and right-sided weakness were improved to some extent. She had a generalized seizure while being on phenytoin and the electroencephalogram (EEG) showed no epileptiform discharges. Her Mantoux test was negative. She was evaluated by a cardiologist and was opinioned as having no clinical evidence of infective endocarditis.

No intracardiac infective cause of her brain abscess was found by transthoracic echocardiogram (TTE). Obstetrical evaluation was done by a gynecologist and the baby was found to have corresponding growth on ultrasound without any other concern. Hydroxy progesterone 500mg single dose IM injection was prescribed before the operation.

She underwent Left frontotemporal parietal (FTP) craniotomy and drainage of deep-seated pyogenic abscess under general anesthesia. Left FTP free bone flap was raised using two burr holes. The dura was intact with a bulging brain. Through a small cortical incision, the abscess was tapped using a brain cannula at a depth of 5 cm, and about 15 ml of thick foul-smelling pus was aspirated and sent for culture and sensitivity testing. The brain became lax and depressed. The bone flap was replaced and left floating.

Post-operatively, she became conscious and alert and was able to follow verbal commands. She had expressive dysphasia without any headache or vomiting. Physiotherapy and deep vein thrombosis (DVT) prophylaxis were given. She was reviewed by the gynecologist and found to be without any gynecological concerns either for the mother or baby. Fetal heart rate was regularly monitored. She showed a progressive recovery in terms of her weakness and dysphasia. Her operative wound healed well and sutures were removed. She was gradually mobilized.

Pus gram staining showed no bacteria and three pus cells. Pus culture on the third day did not show any growth. On the 15th day, it showed the growth of fusobacterium nucleatum, an opportunistic pathogen that colonizes the oral cavity and the gastrointestinal tract. The susceptibility test could not have proceeded. Her antibiotics were switched to Amoxycillin / Clavulanate after consultation with an infectious disease specialist. At the time of discharge, which was after a month, she was self-ambulant. She had normal facial movements and regained the normal power of her right-sided limbs. She was advised to continue Phenytoin 100mg BD for 6 months.

She was followed up in the antenatal clinic at 33 weeks and 4 days gestation. She had a previous home delivery 13 years back without any complications. The current pregnancy was booked in a private hospital at 8 weeks. Her dating scan, anomaly scan, and glucose tolerance test (GTT) were normal. She was showing progressive neurological improvement with residual numbness in her right hand. The neurologist recommended vaginal delivery as the mode of delivery unless there was an obstetric indication for cesarean section. She had a spontaneous onset of labor at 40 weeks of gestation. Her labor progressed smoothly and delivered a healthy girl baby weighing 3245 gm.

## Discussion

BA is a rare condition encountered in pregnancy and carries a poor prognosis for mother and baby with a mortality rate of 30%, irrespective of the state of the pregnancy (Yoshida,2013, p.2). From the listed cases in Table 1, it is evident that in 50 % of cases, the primary source of infection was either nasal sinuses, upper respiratory tract, ear, or teeth. According to Wax et al, up to 30% of cases will not have any predisposing factors, which is similar to our case. Pregnancy being an immunosuppressive state with hormonal imbalance, can contribute towards etiological factors by itself.

The most common symptom reported was headache (75%) followed by neurological abnormalities (67%) and altered consciousness (58%)[1]. The clinical presentation is affected by the severity of the mass effect. However, in medical literature, few cases have been documented with uncommon presentations like diabetes insipidus or mimicking stroke[2]. In this case, the woman presented with weakness in the arm and mild headache, and was fully conscious until the operation; this mimicked a stroke. Brouwer and van de Beek opined that staphylococcal and streptococcal species are the most common pathogens identified[3-4]. In our case, the growth of *Fusobacterium nucleatum*, a commensal in the oral cavity, was noted on the 15th day of culture. It is usually associated with periodontal disease, thereby suspecting dental cause as the primary source of infection even though there was no history suggestive of any dental infection.

Diagnostic imaging plays a central role in the diagnosis of BA. MRI is a safe and highly sensitive diagnostic imaging modality for use in pregnancy. The choice of antibiotic depends on factors like species specificity with bactericidal properties and the ability to cross the blood-brain barrier in adequate concentrations. In culture-negative cases (almost 50%), empirical antibiotic therapy can be started to cover both aerobic and anaerobic organisms, based on the primary source and location of BA. Along with this, Dexamethasone is administered to reduce brain edema and the resultant mass effect. Additionally, early administration of antiepileptic is recommended as 70% of patients can develop epilepsy. In our case, she had a seizure while she was on antiepileptic, highlighting the importance of its administration. The medicines administered were listed in Table 2.

As deep-seated white matter abscess is unlikely to respond to medical treatment alone, surgery is recommended in the presence of significant mass effect and neurological deficit, which allows immediate decompression of mass lesion. It allows rapid recovery as exemplified by our patient who had a smooth and

progressive recovery without any permanent neurological deficit. As shown in Table 3, it was observed that almost 50 % of cases, where surgical management was carried out, showed good recovery without any major residual deficit [5,6,7,8]. It highlights the importance of early imaging and prompt surgical management which contributed to low mortality in our case. Like Baxi, Hobson et al reported a case that resulted in a residual deficit [9,10]. Kim et al found no difference in outcome attributable to the surgical procedure involved [11]. One case was reported with a bad outcome where sudden loss of consciousness and acute brain herniation was seen as a unique presentation of sinogenic brain abscess [12].

In summary, it is a good practice to keep BA as one of the differential diagnoses for any patient presenting with usual or unusual clinical features. Evidence from the literature depicts that the prognosis highly relies on early diagnosis with appropriate treatment. Multidisciplinary management is the stepping stone to success which gives the maximum benefit to the patient.

Author	Age	Diagnosis	Site of origin	Presenting symptom
Braun TI et al[5]	25	16 GW	Respiratory infection	Left-sided headache, mild confusion, right-sided neurologic signs
Baxi LV	36	10 GW	Not detected	Right hemiparesis, Aphasia, DIC
Wax-2004		36 GW	Maxillary and ethmoid sinusitis	Headache, confusion, seizure
Chang and Wang-2004	22	Post cesarean day one	Trauma	Polyuria, hypernatremia, drowsiness, LOC, seizure
Kim HC-2007	38	30 GW	Sphenoid sinusitis	Headache, sinus infection, meningeal sign, sudden deterioration of (VA)at 34 weeks
Kiprono et al-2007	36	28 GW	Respiratory infection	Pneumonia, headache, decreased alertness, paresthesia of left side of face comatose
Jacob CE-2009	23	35 GW	Otitis media	Chronic otitis media, fever, headache, gait ataxia
Salvi et al-2010	19	Post cesarean day 1 to 4	Postpartum, immunosuppression	Seizure, persistent headache, fever
Hobson DT-2011	35	21 GW	Odontogenic	Severe headache, facial swelling, mental status changes
M.Yger-2011	27	28 GW	Congenital heart disease	Partial secondarily generalized seizure
Yoshida-2013	24	22 GW	Not detected	Fever from 22nd week, headache, nausea
Fervienza-2016	32	Post-natal	APS on steroid, Immunosuppression	Neurological symptoms, fever
Bahrami and Safari-2017	25	28 GW	Sinusitis	Nausea, vomiting, sudden LOC

**Table 1:** Brain abscess in pregnancy literature review showing the source of infection



Drug	Dose	Frequency	Duration
Meropenem	1 gm	8 <sup>TH</sup> hourly	14 days
Metronidazole	500mg	8 <sup>th</sup> hourly	7 days
Vancomycin	1.5 gm	12 <sup>th</sup> hourly	5 days
Clindamycin	600mg	8 <sup>th</sup> hourly	5 days
Phenytoin	100mg	8 <sup>th</sup> hourly	30 days
Phenytoin Tablet	100mg	12th hourly	6 months

**Table 2:** Medicines administered

Author	Age	Diagnosis	Location of brain abscess	Cell Culture	Internal treatment	Surgical treatment	Neurological prognosis
Braun TI-1991	25	16 GW	Left occipital lobe	Nocardia asteroides	Sulfisoxazole, ampicillin, ceftriaxone	Left occipital craniotomy	No residual neurological deficit
Baxi LV	36	10 GW	Left basal ganglion	Propionibacterium acnes, staphylococcus capitis	Cefotaxime, ceftazidime, vancomycin	None	Residual hemipares, amenorrhea
Wax-2004		36 GW	Left temporal lobe	Not detected	Cefepime, vancomycin, metronidazole, dexamethasone, fosphenytoin	None	No influence
Chang and Wang-2004	22	Post cesarean day one	Left frontal lobe	Beta hemolytic streptococcus	Chloramphenicol, metronidazole, gentamicin, penicillin G sodium, cefotaxime	Surgical evacuation of the abscess	The mild neurological deficit left hemiparesis
Kim HC-2007	38	30 GW	Pituitary	Streptococcus viridians	None	Transsphenoidal microsurgical removal	No influence
Kiprono et al-2007	36	28 GW	Temporal occipital parietal lateral ventricle			Emergent drainage of abscess	Good recovery, residual left-sided motor deficit
Jacob CE-2009	23	35 GW	Left cerebellar hemisphere	Pseudomonas aeruginosa	Penicillin, ciprofloxacin, trimethoprim/sulfamethoxazole	Partial excision of abscess-modified radical mastoidectomy	Dry left ear, with no residual hearing
Salvi et al-2010	19	Post cesarean day 1 to 4	Right frontal		IV antibiotics, oral dexamethasone	Right frontal craniotomy and abscess evacuation	Good recovery
Hobson DT-2011	35	21 GW	Left frontal, temporal, and	Bacteroides fragilis, wolinellaspecies, campylobacter	Ampicillin, cefotaxime, metronidazole, dexamethasone, levetiracetam	Drainage, lobectomy	Neurological deficits which included

			parietal lobe	gracilis, Prevotella buccae			
M.Yger-2011	27	28 GW	Temporal lobe	None Anomalous drainage of SVC into the left atrium			
Yoshida-2013	24	22 GW	Right frontal lobe	Methicillin sensitives staphylococcus aureus (MSSA)	Cefotaxime, meropenem, amoxicillin, glycerin	None	No influence
Fervienza-2016	32	Post-natal	Brain abscess	Listeria monocytogenes	Ampicillin	None	No neurological deficit
Bahrami and Safari-2017	25	28 GW	Right frontal lobe	Culture- negative Smear-gram positive cocci	Oral antibiotics taken 2 weeks before admission	Emergency craniotomy and evacuation of the abscess	Bad prognosis, Mother died less than one day after surgery, Baby was delivered by cesarean and expired on 2nd day

**Table 3:** Previous case reports of pregnancy brain abscess in medical literature showing prognosis

## Conclusion

Early diagnosis and treatment determine the outcome of BA in pregnancy. A high index of suspicion should be carried out while evaluating a woman presenting with neurological symptoms. Early intervention is highly warranted as even infection with less virulent bacteria can lead to life-threatening situations because immunity power diminishes during pregnancy.

## References

1. Yoshida M, Matsuda H, Furuya K. Successful Prognosis of Brain Abscess during Pregnancy. *J Reprod Infertil.* 2013;14(3):152–5.
2. Chang K-C, Wang J-P. Brain Abscess Presenting as Postpartum Diabetes Insipidus. *Taiwanese Journal of Obstetrics & Gynecology - TAIWAN J OBSTET GYNECOL.* 2004 Mar 1; 43:46–9.
3. Brouwer MC, van de Beek D. Epidemiology, diagnosis, and treatment of brain abscesses. *Current Opinion in Infectious Diseases.* 2017 Feb;30(1):129–134.
4. Brouwer MC, Coutinho JM, Beek D van de. Clinical characteristics and outcome of brain abscess: Systematic review and meta-analysis. *Neurology.* 2014 Mar 4;82(9):806–13

5. Braun TI, Kerson LA, Eisenberg FP. Nocardial brain abscesses in a pregnant woman. *Rev Infect Dis.* 1991 Aug;13(4):630–2.
6. Jacob CE, Kurien M, Varghese AM, Aleyamma TK, Jasper P, Prabu K, et al. Treatment of Otogenic Brain Abscess in Pregnancy. *Otology & Neurotology.* 2009 Aug;30(5):602–603.
7. Salvi N, Massiah N, Nuttall ID. Cerebral abscess in pregnancy: a clinical dilemma. *Archives of Disease in Childhood - Fetal and Neonatal Edition.* 2010 Jun 1;95(Suppl 1): Fa109–Fa109.
8. Fervienza A, Bodro M, Castro P, Hernández S, Teixidó I, Espinosa G, et al. Brain abscesses due to *Listeria monocytogenes* after HELLP syndrome in a patient with antiphospholipid syndrome. *Lupus.* 2017 Aug 1;26(9):1002–4.
9. Baxi LV, Mayer SA, Mansukhani M. Cerebral abscess and thrombophilia in pregnancy. A case report. *J Reprod Med.* 2001 Jun;46(6):606–8.
10. Hobson DTG, Imudia AN, Soto E, Awonuga AO. Pregnancy Complicated by Recurrent Brain Abscess After Extraction of an Infected Tooth. *Obstetrics & Gynecology.* 2011 Aug;118(2 Part 2):467–470.
11. Kim H-C, Kang S-G, Huh P-W, Yoo DS, Cho KS, Kim DS. Pituitary abscess in a pregnant woman. *Journal of Clinical Neuroscience.* 2007 Nov 1;14(11):1135–9.
12. Bahrami R, Safari H. A Fatal Sinogenic Brain Abscess in Pregnancy: Case Report and Review of Literature. *IJNS.* 2017 Mar;06(01):047–9.

