



A Rare Case of Primary Ureteric Carcinoma managed with Surgery and Adjuvant Therapy.

Dr. M Venkataramana (M.D.)¹, Dr. Y Sree Sowmya (M.D.)^{1*}

1. MD Radiation oncology, Head of department, GEMS Ragolu, Andhra Pradesh, 532484.

Corresponding Author: Dr. Y Sree Sowmya (M.D.), (M.D. Radiation oncology), Senior Resident, Department of Radiation Oncology, GEMS Hospital, Ragolu, Andhra Pradesh.

Copy Right: © 2022 Dr. Y Sree Sowmya (M.D.), This is an open access article distributed under the Creative Commons Attribution License, which permits unrestricted use, distribution, and reproduction in any medium, provided the original work is properly cited.

Received Date: September 27, 2022

Published Date: October 05, 2022

Abstract

Introduction: Ureteric malignancies are rare entities. They usually occur in the distal third of the ureter and account for about 7% of urothelial malignancies.

Case history: We present a case of a patient with primary high-grade primary ureteric urothelial carcinoma. The patient underwent radical nephroureterectomy, which revealed high-grade urothelial carcinoma of the left ureter. This was followed by adjuvant chemotherapy with gemcitabine and carboplatin for six cycles. He is now on regular follow-up and doing well.

Discussion: Management of high-grade urothelial Ureteric carcinoma includes a multimodality approach with surgery followed by adjuvant treatment. The POUT trial has shown that Adjuvant platinum-based chemotherapy should be considered a new standard of care after nephroureterectomy for such cases.

Keywords: Urothelial carcinoma, radical nephroureterectomy, adjuvant chemotherapy

Introduction

Ureteric neoplasms are rare malignancies. Urothelial carcinoma of the upper urinary tract accounts for 7% of all kidney tumors and 5% of all urothelial malignancies(1). Concomitant bladder and ureter tumours when seen may occur synchronously or metachronously. Ureteral tumors are usually seen in the distal third of the ureter. The median age at diagnosis is 71 years, and higher-grade tumors are most likely to occur in elderly patients(2).

Cigarette smoking is one of the most important factors contributing to the overall incidence of urothelial cancer(3). Patients with renal pelvis or ureter tumours usually present with gross or microscopic hematuria (75 to 90 percent)(4).The other less common symptoms include pain (8% to 40%), bladder irritation (5% to 10%), or other constitutional symptoms (5%). About 10% to 20% of patients may present with a flank mass secondary to tumor or hydronephrosis.

Staging consists of a complete history and physical examination, complete blood count, and liver and kidney function tests. Cystoscopy is important to look for the high incidence of multiple tumors(5).

Here we discuss a case of primary Ureteric carcinoma that was managed by radical excision followed by adjuvant chemotherapy.

Case History

A 57-year-old male presented to our hospital with gross painless hematuria and left flank pain radiating to the groin for two months. There were no medical comorbidities. He had a history of Tobacco smoking for 10 years. Per abdominal examination did not reveal any significant findings other than left flank tenderness. Routine laboratory examination findings were within normal limits. MRI pelvis revealed dilated left ureter with heterogeneous T2 and STIR isointense mass lesion causing severe luminal narrowing in the distal third of the left ureter for a length of 60 mm with homogeneous enhancement post-contrast with no evidence of extraluminal spread. Left VUJ was unremarkable. Periureteic fat planes were normal (Figure 1). The right kidney was normal. Chest imaging did not show any primary or metastatic disease.

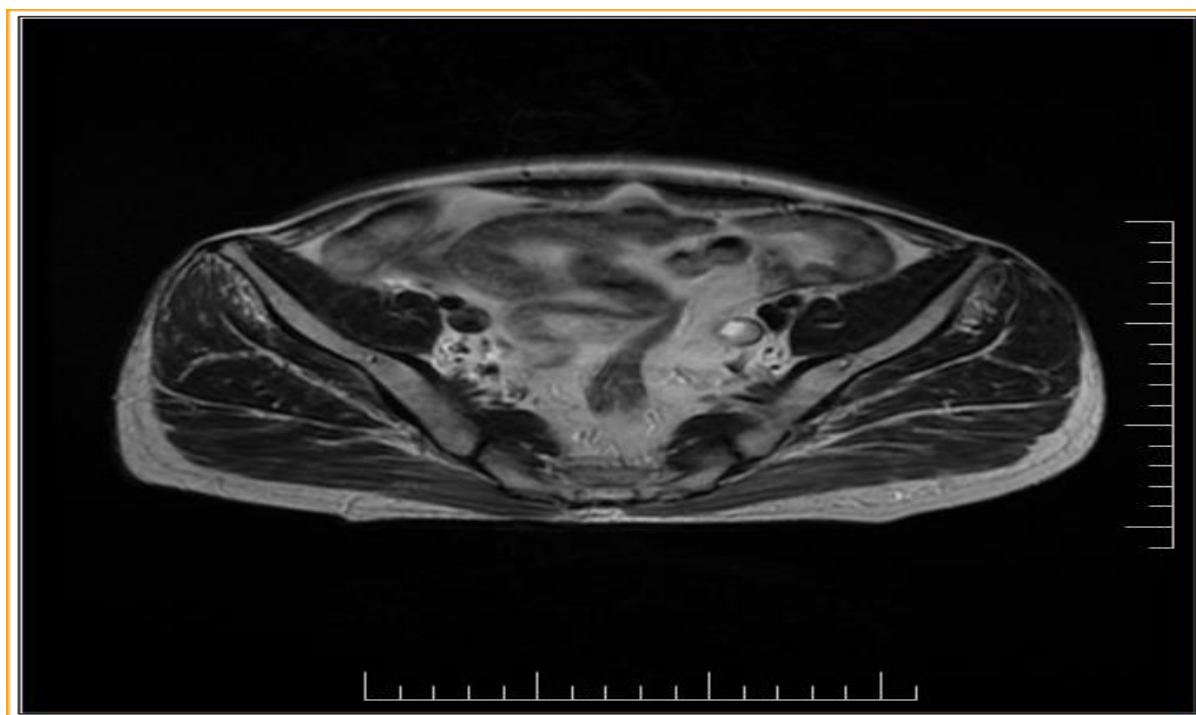


Figure 1: Axial image of MRI pelvis showing tumour

Cystoscopy revealed normal bladder mucosa. He underwent radical nephroureterectomy with bladder cuff excision in April 2022. Gross examination showed an exophytic growth measuring 5.2 x 2.8 x 1 cm originating from ureteral mucosa. (Figures 2 and 3)

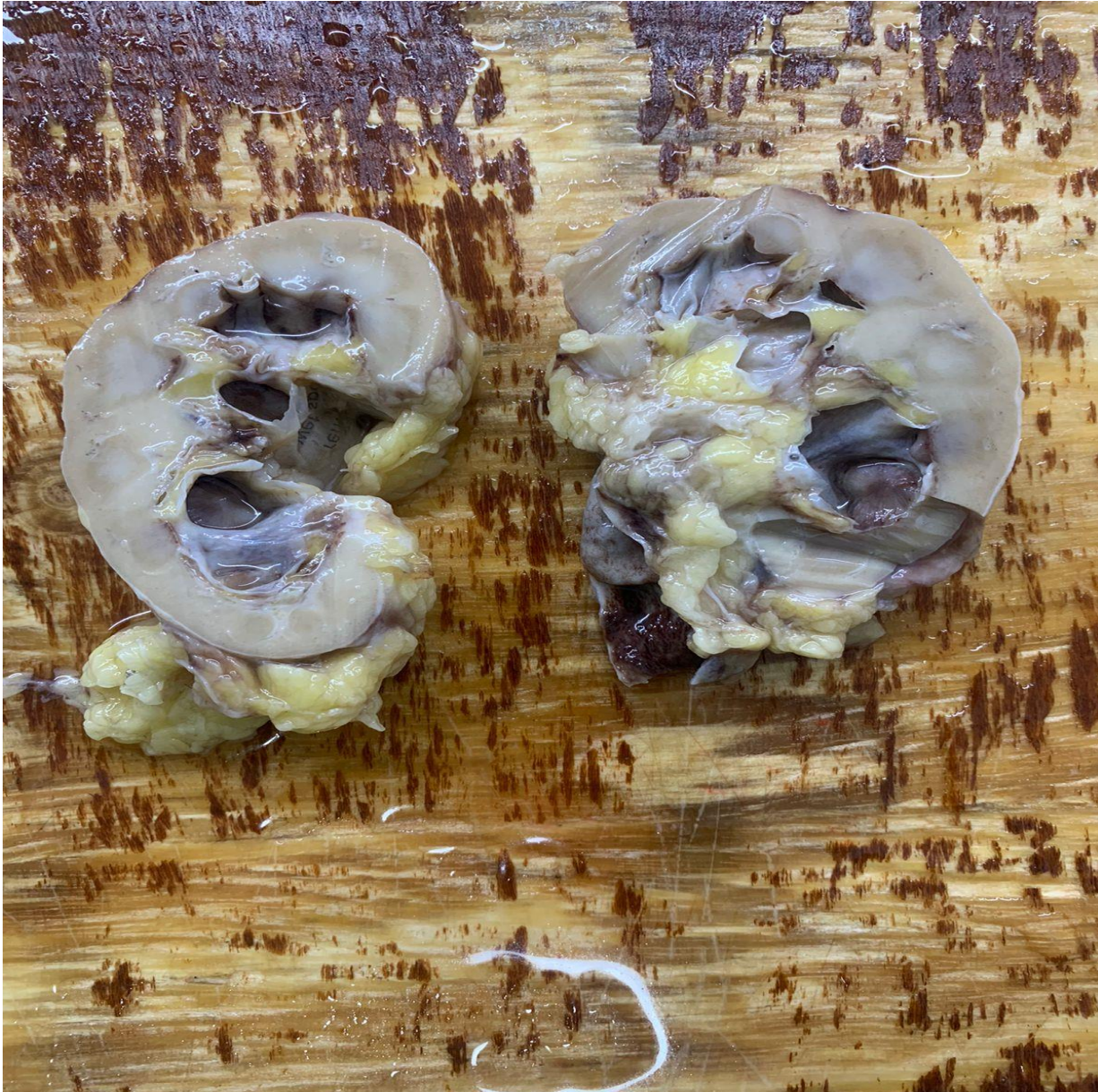

Figure 2: Relation of ulcerated ureteric growth to hilar fat

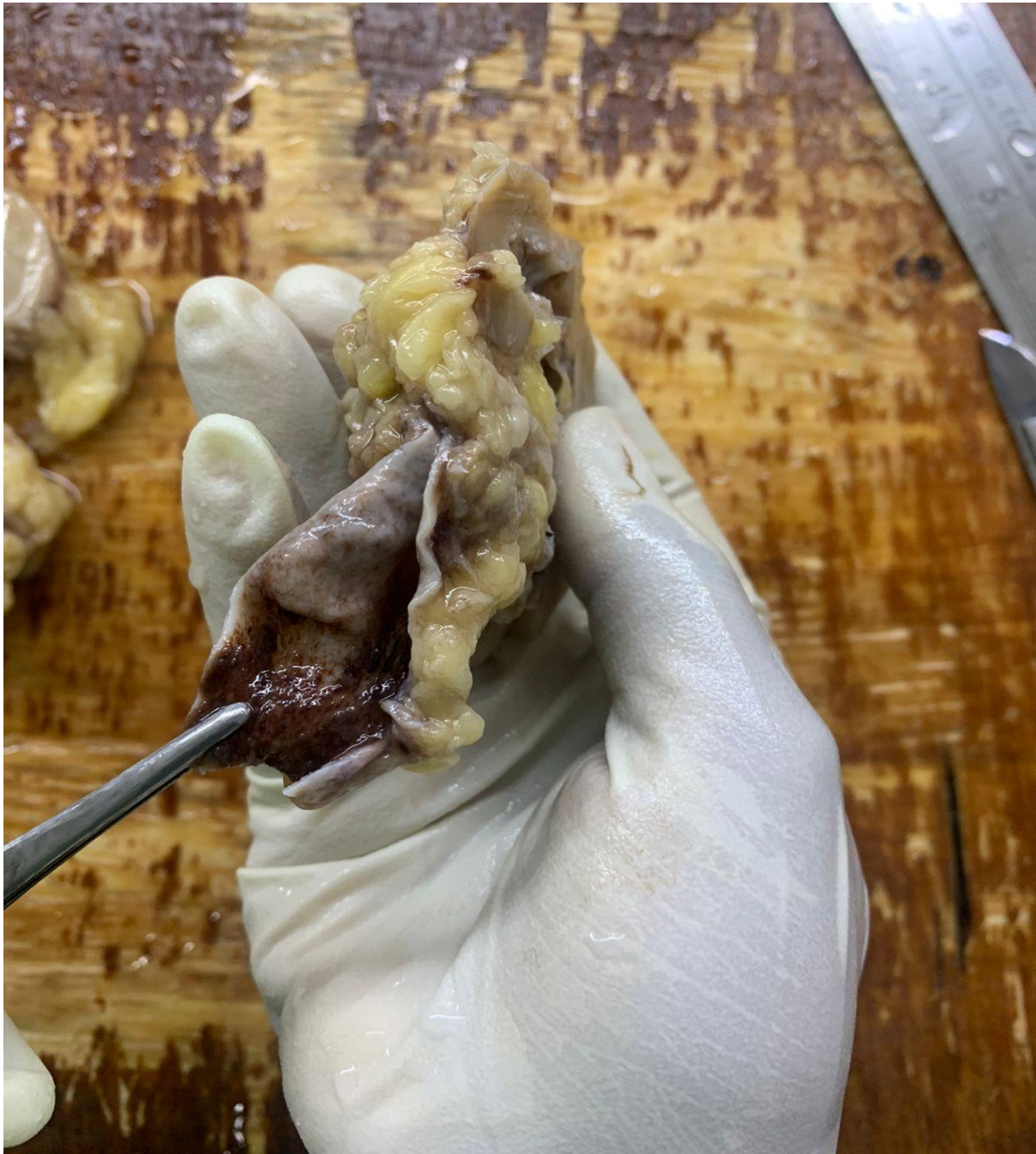

Figure 3: Ulcerated growth inside the ureter

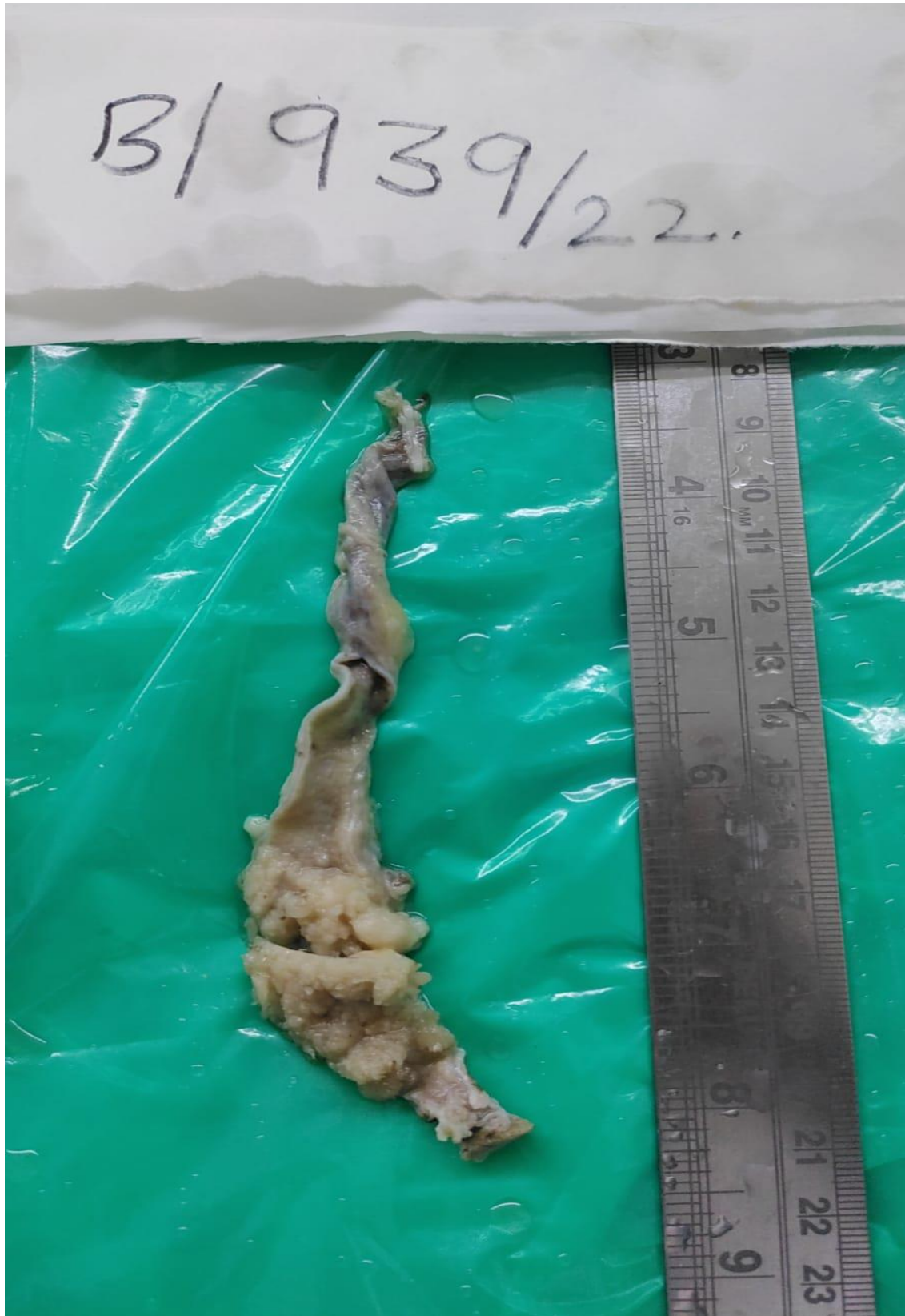

Figure 4: exophytic growth in ureter

Citation: Dr. Y Sree Sowmya "A Rare Case of Primary Ureteric Carcinoma managed with Surgery and Adjuvant therapy."

MAR Oncology, Volume 4 Issue 4

www.medicalandresearch.com (pg. 6)

Microscopic examination high grade invasive papillary urothelial carcinoma invading muscularis (Figures 4, 5 and 6). All margins were negative for invasive carcinoma.

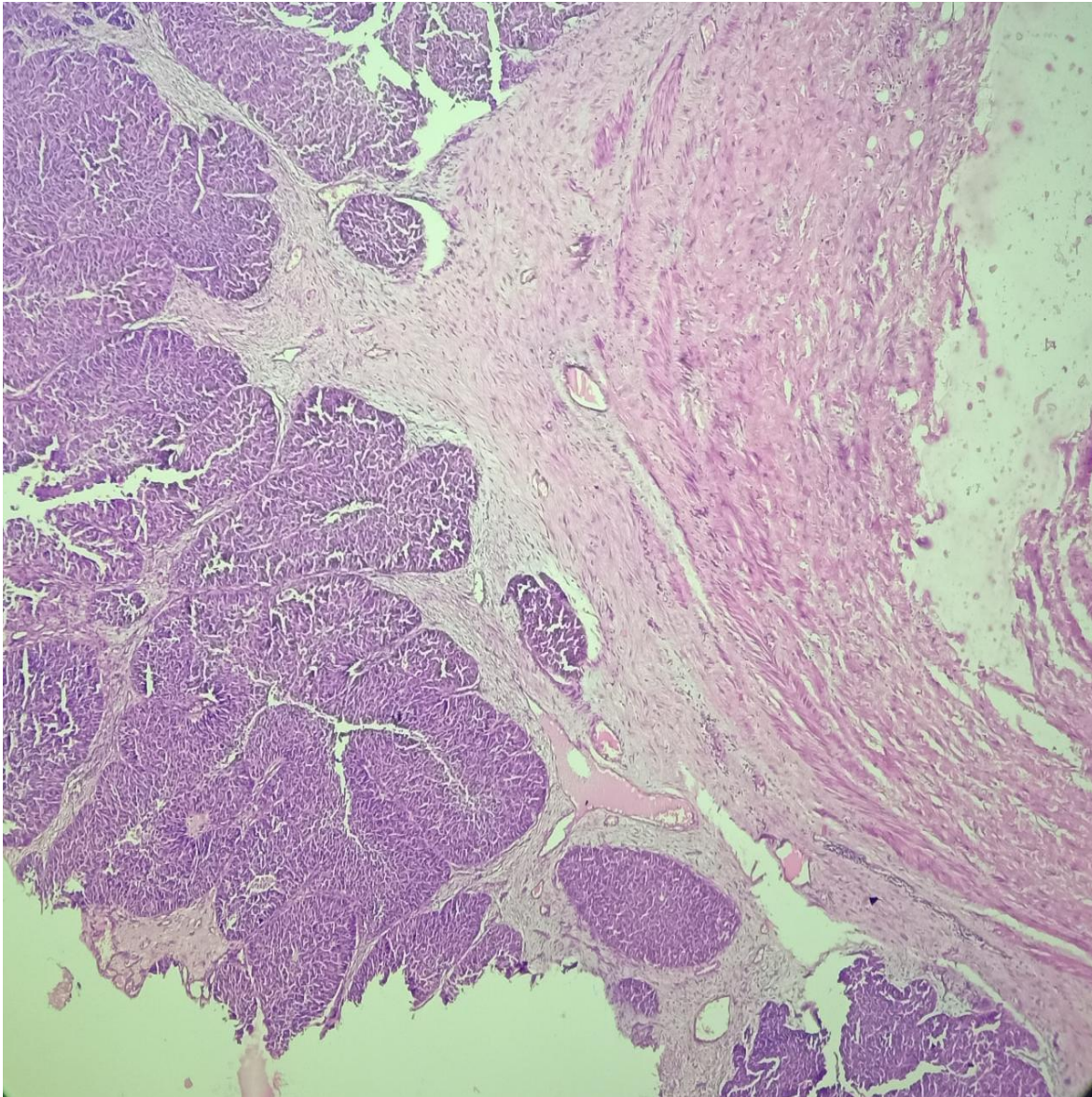


Figure 4 Microscopic image showing neoplastic urothelial cells infiltrating muscularis propria

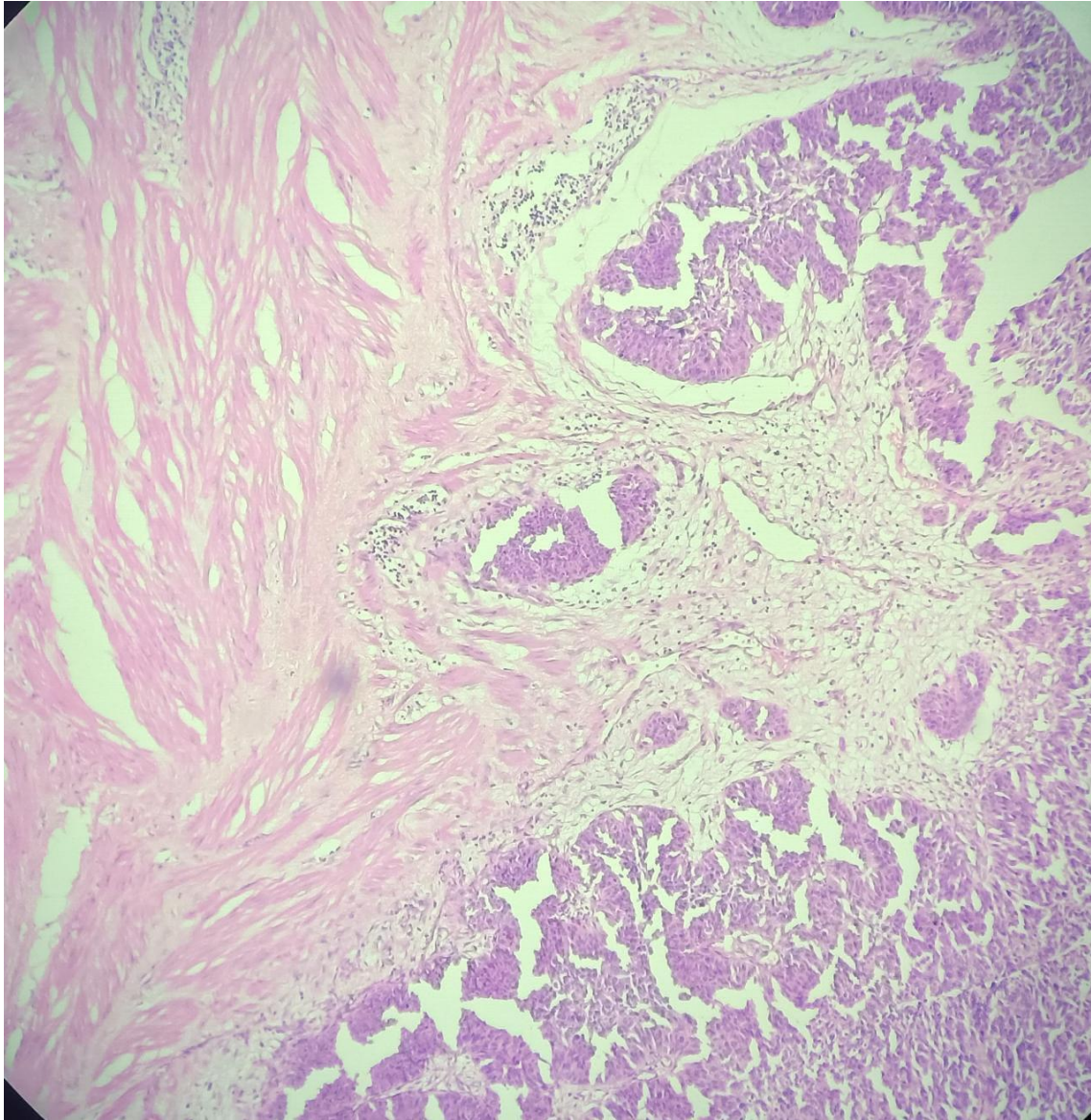


Figure 5: Microscopic image showing neoplastic urothelial cells infiltrating muscularis propria

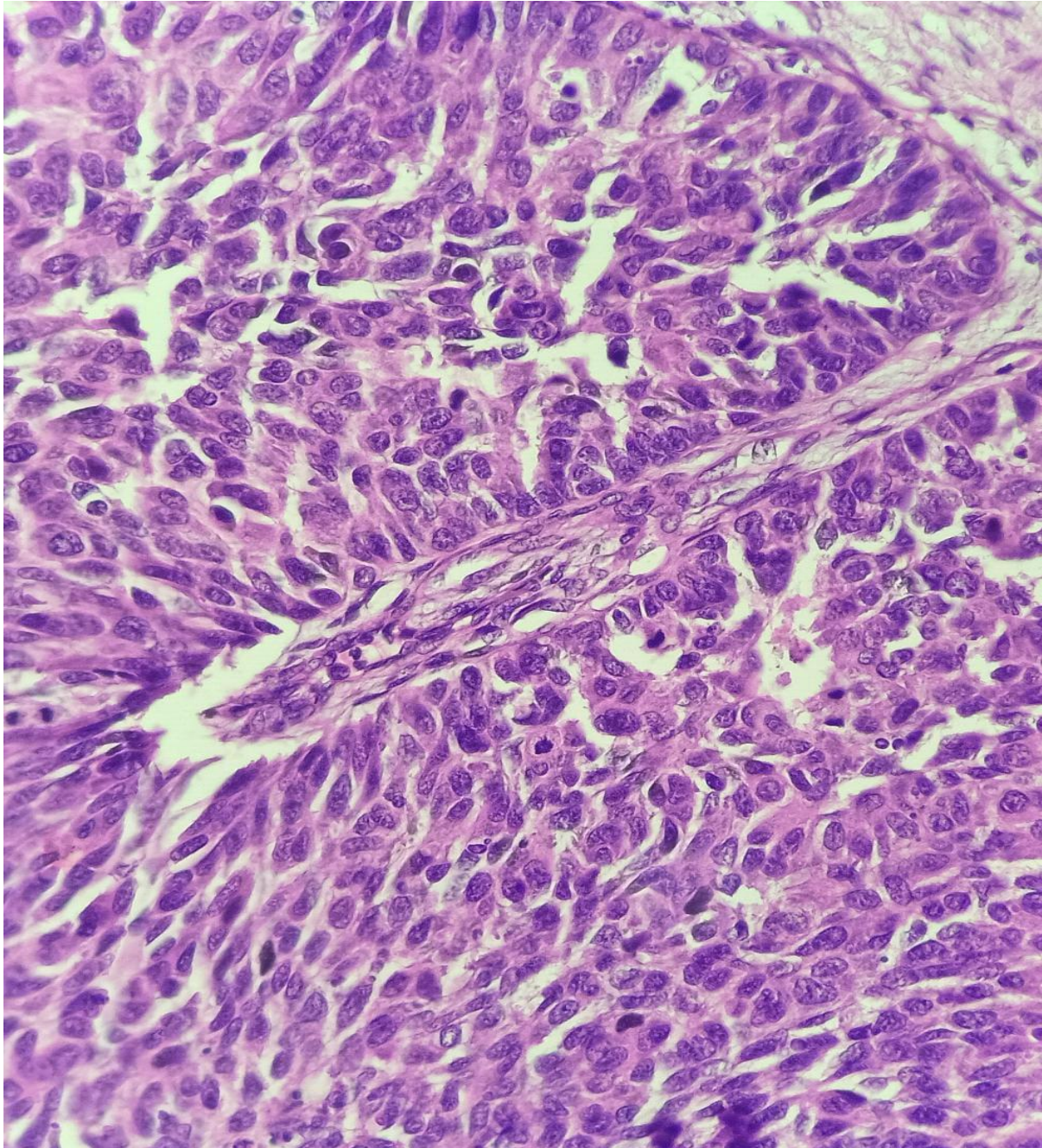


Figure 6: High power view of neoplastic urothelial cells

The postoperative recovery of the patient was uneventful.

Post 6 weeks of surgery, He was started on adjuvant chemotherapy gemcitabine day 1 and day 8 (1000mg) per meter square and carboplatin AUC 5 for 6 cycles. The patient tolerated chemotherapy well and is on regular follow-up.

Citation: Dr. Y Sree Sowmya "A Rare Case of Primary Ureteric Carcinoma managed with Surgery and Adjuvant therapy."

MAR Oncology, Volume 4 Issue 4

www.medicalandresearch.com (pg. 9)

Discussion

Prognoses of ureteric malignancies are dependent on tumor invasiveness and pathologic grade(6). More than 90% of malignant tumors arising from the renal pelvis and ureter are urothelial (also called transitional cell) carcinomas. The major prognostic factors in patients with renal pelvis or ureter carcinoma are initial stage and grade of the tumor. Transitional cell carcinoma of the ureter is seen to be associated with a worse prognosis compared with tumours of the renal pelvis(7). Surgery is the therapeutic foundation for the management of renal pelvis and ureter carcinoma(5).The management of ureter tumors depends on the location of the tumor, upper, mid, or distal location, and on disease extent. Neoadjuvant chemotherapy may be considered in selected patients(8).

There are no randomized trials on the role of postoperative RT in patients who have had a complete resection of an upper urinary tract cancer.The pathologic similarity of urothelial carcinoma of the renal pelvis and ureter to bladder cancer has encouraged medical oncologists to use similar chemotherapeutic regimens in the management of upper tract urothelial carcinomas(8).

Because patients with urothelial carcinoma of the upper urinary tract are at a high risk of urothelial tumors of the bladder, monitoring with cystoscopy at periodic intervals is necessary(9). The NCCN Bladder Cancer Panel recommends a cystoscopy every 3 months for 1 year and then at increasing intervals.

References

1. Reitelman C, Sawczuk IS, Olsson CA, Puchner PJ, Benson MC. Prognostic Variables in Patients with Transitional Cell Carcinoma of the Renal Pelvis and Proximal Ureter. J Urol. 1987 Nov;138(5):1144–5.
2. Geller SA, Campos FPF de. Ureteric carcinoma. Autopsy Case Rep. 2014;4(1):63–4.
3. Miyazaki J, Nishiyama H. Epidemiology of urothelial carcinoma. Int J Urol. 2017 Oct;24(10):730–4.
4. Lehmann J, Suttmann H, Kovač I, Hack M, Kamradt J, Siemer S, et al. Transitional Cell Carcinoma of the Ureter: Prognostic Factors Influencing Progression and Survival. Eur Urol. 2007 May;51(5):1281–8.
5. Kopel J, Sharma P. Narrative review of the surgical management of high-risk upper tract urothelial carcinoma. AME Med J. 2021 Jun;6:17–17.

6. Amin MB. Histological variants of urothelial carcinoma: diagnostic, therapeutic and prognostic implications. *Mod Pathol*. 2009 Jun;22(S2):S96–118.
7. Park S, Hong B, Kim CS, Ahn H. The Impact of Tumor Location on Prognosis of Transitional Cell Carcinoma of the Upper Urinary Tract. *J Urol*. 2004 Feb;171(2):621–5.
8. Birtle A, Johnson M, Chester J, Jones R, Dolling D, Bryan RT, et al. Adjuvant chemotherapy in upper tract urothelial carcinoma (the POUT trial): a phase 3, open-label, randomised controlled trial. *The Lancet*. 2020 Apr;395(10232):1268–77.
9. Petros FG. Epidemiology, clinical presentation, and evaluation of upper-tract urothelial carcinoma. *Transl Androl Urol*. 2020 Aug;9(4):1794–8.