



B Effect of Aloe Vera Gel And 1% Silver Sulphadiazine Cream in the Treatment of Superficial Burn in Children- A Comparative Study

Dr Md Mazharul Alam ¹, Dr Md Alamgir ^{2*}, Dr Mozammel Haque Chowdhury ³,

Dr Md Faridul Islam ⁴

1. Assistant Professor Moinamoti Medical College, Comilla, Bangladesh.
2. Hossan Assistant professor Monno medical College and hospital Manikganj, Bangladesh.
3. Consultant IBN Sina medical College hospital, Bangladesh.
4. Assistant professor Chattogram international medical College hospital, Bangladesh.

Corresponding Author: Dr Md Alamgir, Hossan Assistant professor Monno medical College and hospital Manikganj, Bangladesh.

Copy Right: © 2022, Dr Md Alamgir, This is an open access article distributed under the Creative Commons Attribution License, which permits unrestricted use, distribution, and reproduction in any medium, provided the original work is properly cited.

Received Date: August 18, 2022

Published Date: September 01, 2022

Abstract

Background: Burns are one of the most devastating conditions encountered in medicine. The injury represents an assault on all aspects of the patient, from the physical to the psychological. Scald burns remain the most common cause of burn injury in children younger than 5 years of age.

Objective: To assess the outcome of aloe vera gel and 1% silver sulphadiazine in superficial burn management.

Methodology: Prospective comparative interventional study was carried out in the Division of Paediatric Surgery, Bangladesh Institute of Child Health (BICH), Dhaka Shishu (Children) Hospital. Total 40 patients admitted with superficial burn during the study period were allocated in two groups by simple random sampling. Among them 20 sample were Group A patients dressing was done by Aloe vera gel and 20 sample were Group B patients dressing was done by 1% SSD.

Results: The mean pain relief time was found 2.60 ± 1.27 days in group A and 3.95 ± 0.99 days in group B. The difference was statistically significant ($p < 0.05$) between two groups. The mean wound healing time was found 5.15 ± 1.56 days in group A and 8.25 ± 2.40 days in group B. The difference was statistically significant ($p < 0.05$) between two groups. One (5.0%) patients were found wound infection in group A and 2(10.0%) in group B. The mean treatment cost was found 62.4 ± 26.4 Taka in group A and 516.4 ± 217.7 Taka in group B. Thirteen (65.0%) patients were found hospital stay 1-5 days in group A and 16(80.0%) were hospital stay 6-10 days in group B. The difference were statistically significant ($p < 0.05$) between two groups.

Conclusion: In conclusion aloe vera gel promoted wound healing, early pain relief and cost effective for the management of superficial burn in children. So it can be used as an alternative to 1% silver sulphadiazine in superficial burn management in children for getting better outcome.

Background

Burns are one of the most devastating conditions encountered in medicine. The injury represents an assault on all aspects of the patient, from the physical to the psychological. It affects all ages, from babies to elderly people, and is a problem in both the developed and developing world. All of us have experienced the severe pain that even a small burn can bring. However the pain and distress caused by a large burn are not limited to the immediate event. The visible physical and the invisible psychological scars are long lasting and often lead to chronic disability [5].

According to WHO (World Health Organization) burns cause “an estimated of 265000 deaths every year”. WHO also states the following: “the non-fatal burn injuries are a leading cause of morbidity”, while most of them “occur mainly in the home and workplace. Burns are preventable. Starting from these facts and adding the fact that burns are lesions that affect millions of people yearly worldwide [10].

Scald burns remain the most common cause of burn injury in children younger than 5 years of age. The majority of scald burns in infants and toddlers are from hot foods and liquids. The management of the burn patient depends on the depth of the injury. For superficial or first-degree burns, the treatment is focused on symptomatic relief and consists of a topical ointment containing aloe vera along with a non-steroidal anti-inflammatory agent [3].

Silver is an effective antimicrobial agent, particularly in prevention of gram negative sepsis and silver sulphadiazine remains in use particularly with extensive burns. However, silver sulphadiazine is contraindicated in neonates, may make burn depth assessment difficult. It should only be considered as a treatment option after assessment by experienced medical staff or under guidance from burns specialists [16]. The most common topical antimicrobial agent used is 1% silver sulphadiazine (SSD) cream but its minimum side effects are delayed wound healing, resistance to 1% silver sulphadiazine (SSD) cream, renal toxicity, and leukopenia [15].

Aloe Vera gel (family: Liliaceae), contains nutrients, vitamins, antioxidants and aloe vera gel has wound healing and immunomodulating effects (Shahzad and Ahmed, 2013). The aloe vera gel extract permitted faster healing of burn and reestablished the vascularity of burn tissues. These effects might be due to several mechanisms including an increasing collagen synthesis and rate of epithelialization by the effect of acemanan (mannose-6 phosphate) to stimulate fibroblasts an anti-inflammatory effect, an antimicrobial effect and a moisturizing effect [9].

Aloe Vera contains 75 potentially active constituents: vitamins (vitamins A, C and E, vitamin B12, folic acid, and choline), enzymes (alkaline phosphatase, amylase, bradykinase, carboxypeptidase, catalase, cellulase, lipase, and peroxidase), minerals (calcium, chromium, copper, selenium, magnesium, manganese, potassium, sodium and zinc), sugars (monosaccharides and polysaccharides), lignin, saponins, salicylic acids and amino acids. Salicylic acid in Aloe Vera gel possesses anti-inflammatory properties. Lignin, enhances penetrative effect of the other ingredients into the skin [11].

Causes of burn incidence

According to national burn management guideline, 2010 –

1. Scald - hot water, steam, cooking oil hot, hot curry.
2. Flame burn.
3. Electric burn.
4. Chemical burn.
5. Friction.
6. Blast.
7. Extreme cold (frost bite ,spillage of liquid nitrogen) rare .
8. Ionizing radiation (rare).

Classification (according to depth):

According to the depth of injury, burns are described as superficial, superficial partial-thickness, deep partial-thickness, full-thickness, and subdermal.

Superficial (first-degree) burns:

- Affect only the epidermis and are
- Characterized by erythema, pain, and desquamation
- Resolve without scarring within 7 to 10 days.

Superficial partial-thickness (second-degree) burns:

- Extend through the epidermis into the papillary dermis and are
- Characterized by blisters, erythema, and edema.
- These burns blanch with pressure and have a brisk capillary refill.

Deep partial-thickness (second-degree) burns:

- Involve the reticular dermis and
- Exhibit a more sluggish capillary refill.
- The wound is very moist and edematous with diminished to complete loss of sensation.

The tissue injury of full-thickness (third-degree) burns:

- Extends into the subcutaneous tissue and
- Leathery appearance

Subdermal (fourth degree) burns:

- Extends into the fascia, muscles, and bone [3].

Pathophysiology of burn:

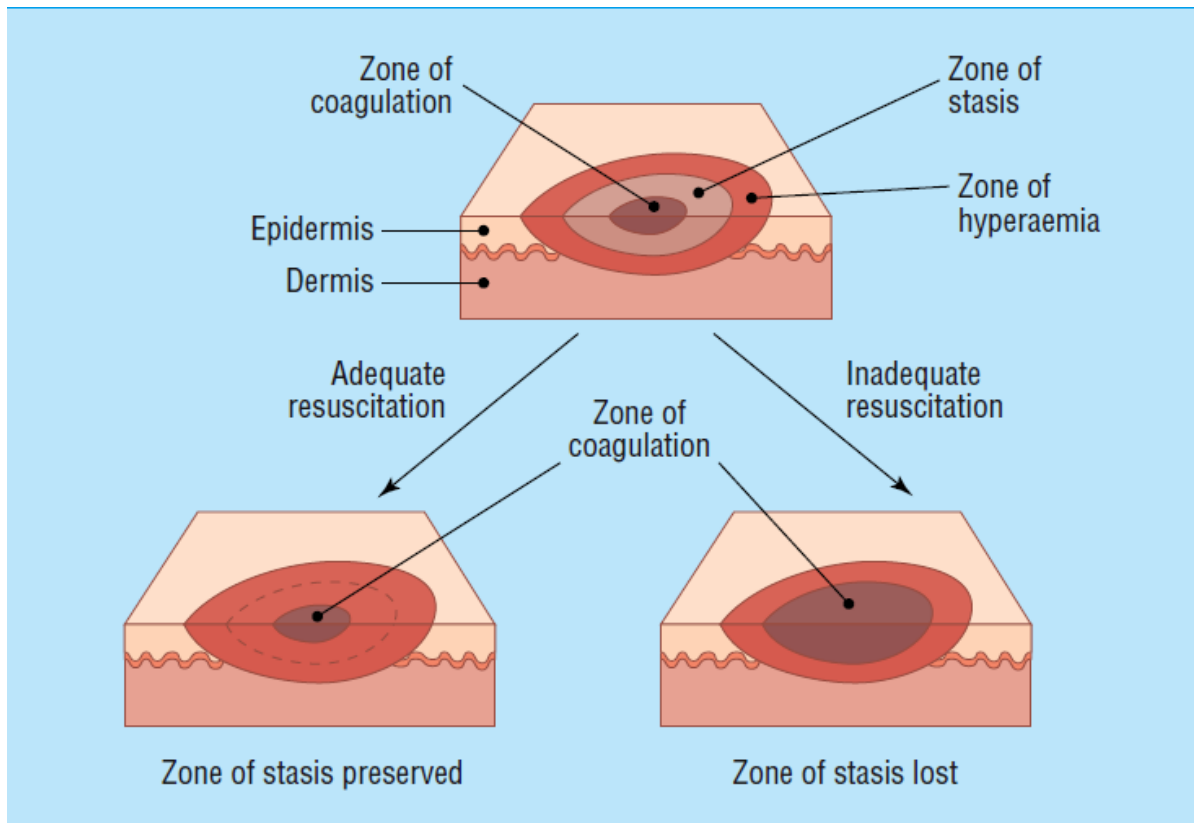
The early response to a burn can be described as local and systemic.

The local phase response: Characterized by three zones: coagulation, stasis, and hyperemia.

Zone of coagulation- identified by surface tissue necrosis as cells are irreversibly damaged secondary to denaturation and coagulation of constituent proteins and loss of plasma membrane integrity.

Zone of stasis- In this zone, most cells are initially viable, but tissue perfusion becomes progressively compromised because of the local release of inflammatory mediators, such as thromboxane A₂, arachidonic acid, histamine, oxidants and cytokines.

Zone of hyperemia- lies peripheral to the zone of stasis and is characterized by vasodilatation with subsequent increased blood flow and edema resulting from the inflammatory response. Tissue within this zone frequently recovers unless affected by severe sepsis or prolonged hypoperfusion [3].



Picture 1: Jackson's burn model (Hettiaratchy and Dziewulski, 2004)

Systemic response:

The release of cytokines and other inflammatory mediators at the site of injury has a systemic effect once the burn reaches 30% of total body surface area.

Cardiovascular changes Capillary permeability is increased, leading to loss of intravascular proteins and fluids into the interstitial compartment. Peripheral and splanchnic vasoconstriction occurs. Myocardial contractility is decreased, possibly due to release of tumour necrosis factor. These changes, coupled with fluid loss from the burn wound, result in systemic hypotension and end organ hypoperfusion.

Respiratory changes Inflammatory mediators cause bronchoconstriction, and in severe burns adult respiratory distress syndrome can occur.

Metabolic changes The basal metabolic rate increases up to three times its original rate. This, coupled with splanchnic hypoperfusion, necessitates early and aggressive enteral feeding to decrease catabolism and maintain gut integrity.

Immunological changes Non-specific down regulation of the immune response occurs, affecting both cell mediated and humoral pathways [4].

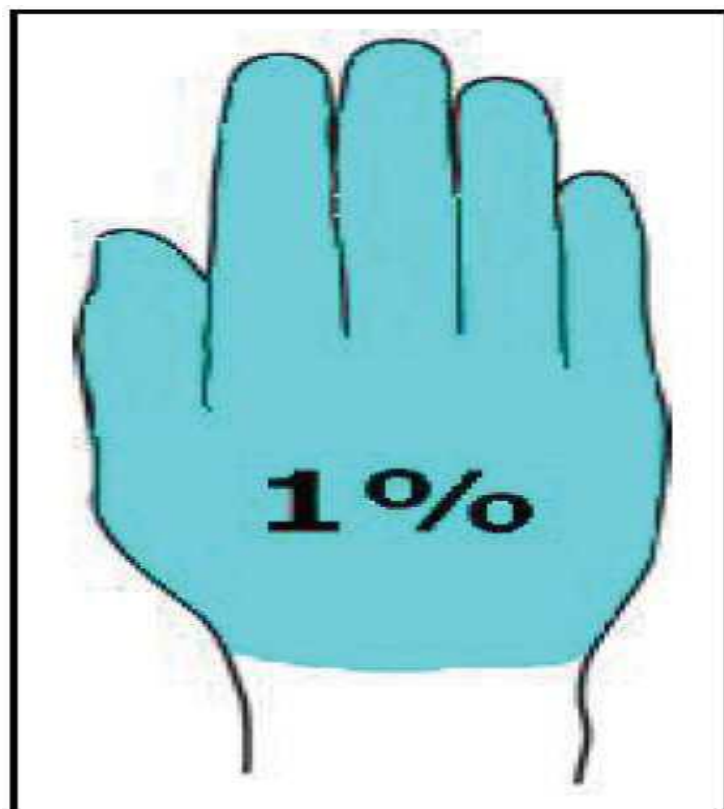
Assessment of burn wound:

Assessing burn size:

Burn size needs to be formally assessed in a controlled environment. This allows the area to be exposed and any soot or debris washed off. Care should be taken not to cause hypothermia during this stage.

Palmar surface:

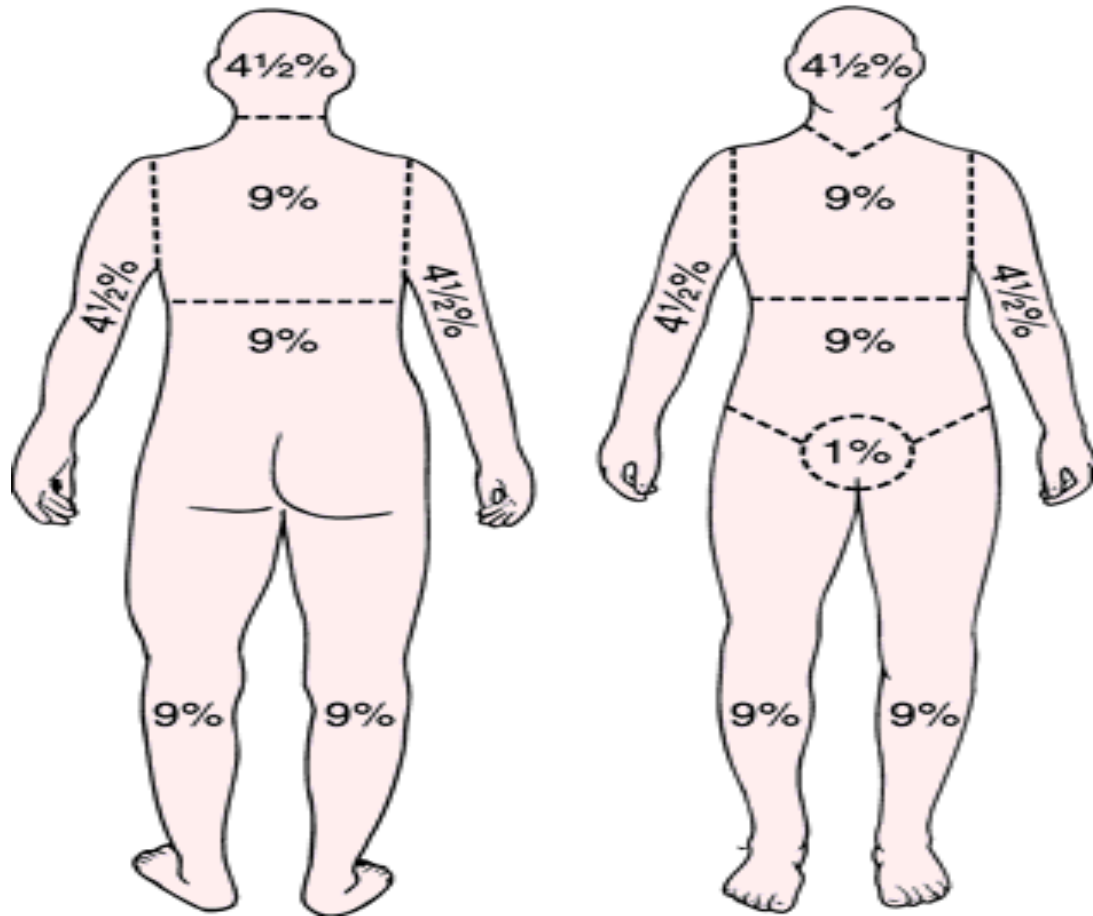
The surface area of a patient's palm (including fingers) is roughly 0.8% of total body surface area. Palmar surface can be used to estimate relatively small burns (<15% of total surface area) or very large burns (>85%, when unburnt skin is counted).



**Palm and fingers
of the patient =
1% TBSA**

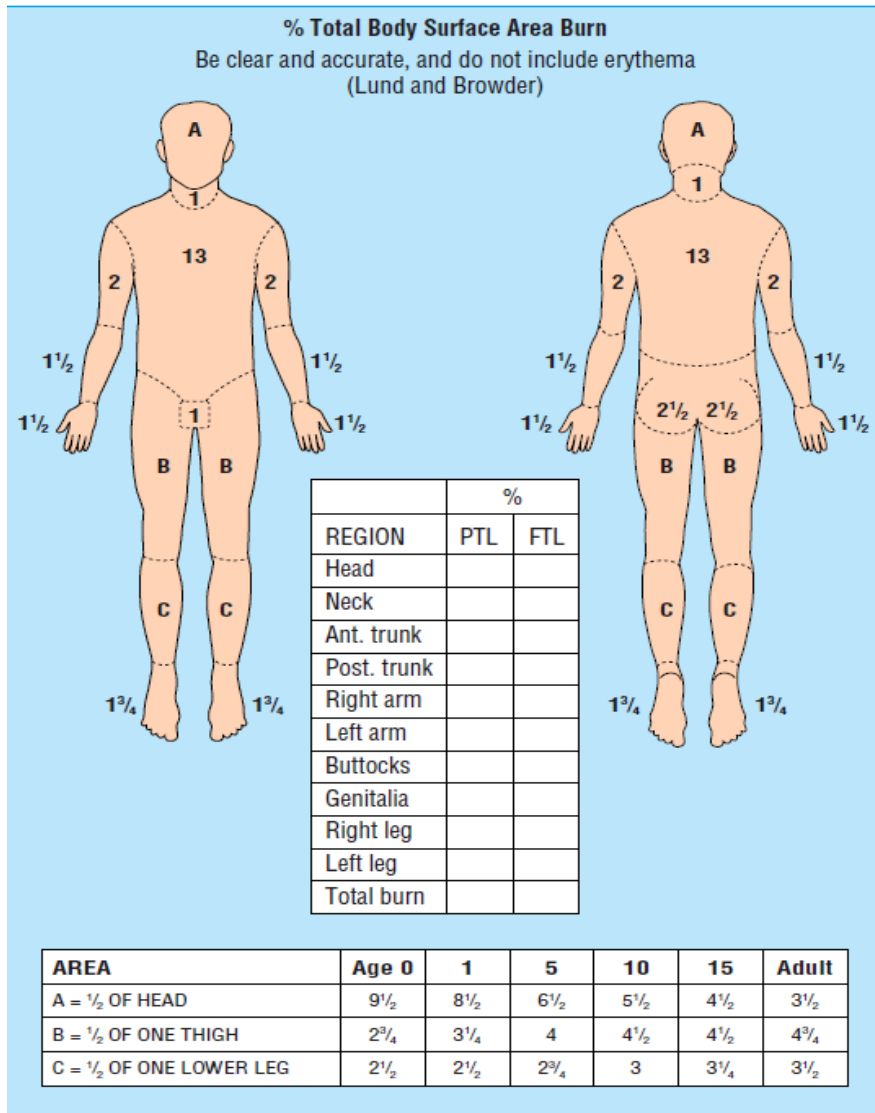
Picture 2: Palm of patient represent 1% of TBSA (After Rezuan, 2015)

Wallace rule of nine: This is a good, quick way of estimating medium to large burns in adults. The body is divided into areas of 9%, and the total burn area can be calculated. It is not accurate in children.



Picture 3: Wallace rule of nine (After Miller-Keane and O'Toole, 2003)

Lund and Browder chart: Another accurate way of measuring the size of burns is to draw the burn on a Lund and Browder chart, which maps out the percentage TBSA of sections of our anatomy. It also considers different proportional body surface area in children according to age [4].



Picture 4: Lund and Browder chart (After Hettiaratchy and Papini, 2004)

Depth of the Burn

Burn depth is classified into one of three types based on how deeply into the epidermis or dermis the injury might extend.

- Superficial burns (First Degree) involve only the epidermis and are warm, painful, red, soft and blanch when touched. Usually, there is no blistering. A typical example is a sunburn.
- Partial thickness burns (Second Degree) extend through the epidermis and into the dermis. The depth into the dermis can vary (superficial or deep dermis). These burns are typically very painful, red, blistered, moist, soft and blanch when touched. Examples include burns from hot surfaces, hot liquids or flame.

- Full-thickness burns (Third Degree) extend through both the epidermis and dermis and into the subcutaneous fat or deeper. These burns have little or no pain, can be white, brown, or charred and feel firm and leathery to palpation with no blanching. These occur from a flame, hot liquids, or superheated gasses and electric burn.

1% Silver Sulphadiazine cream:

Although silver sulphadiazine (AgSD) has received wide-spread acceptance as a topical agent to control bacterial infection, especially in burn wound and is now approved by the Food and Drug Administration, its mechanism of action is uncertain. This compound was prepared to combine the oligodynamic action of silver with the antibacterial effect of sulphadiazine. Subsequent studies showed that the sulfonamide antagonist para-aminobenzoic acid (PAB) did not nullify silver sulphadiazine inhibition, and that the silver moiety combined in vitro with both DNA and bacteria. The sedimentation coefficient of DNA isolated from AgSD-inhibited bacteria was found to be higher than that of normal DNA [2].

Silver, but not sulphadiazine, was bound by bacteria. Sulphadiazine did not act as an antibacterial agent in low concentrations but exhibited specific synergism in combination with subinhibitory levels of silver sulphadiazine. The efficacy of silver sulphadiazine is thought to result from its slow and steady reactions with serum and other sodium chloride-containing body fluids, which permits the slow and sustained delivery of silver ions into the wound environs. In this circumstance, a relatively minute amount of sulphadiazine appears active [2].

Aloe vera gel:

The botanical name of Aloe vera is Aloe barbadensis miller. It belongs to Asphodelaceae (Liliaceae) family, and is a shrubby or arborescent, perennial, xerophytic, succulent, peagreencolor plant. The plant has triangular, fleshy leaves with serrated edges, yellow tubular flowers and fruits that contain numerous seeds. Each leaf is composed of three layers: 1) An inner clear gel that contains 99% water and rest is made of glucomannans, amino acids, lipids, sterols and vitamins. 2) The middle layer of latex which is the bitter yellow sap and contains anthraquinones and glycosides. 3) The outer thick layer of 15–20 cells called as rind which has protective function and synthesizes carbohydrates and proteins. Inside the rind are vascular bundles responsible for transportation of substances such as water (xylem) and starch (phloem). Aloe vera contains 75 potentially active constituents: vitamins, enzymes, minerals, sugars, lignin, saponins, salicylic acids and amino acids[12].

Citation: Dr Md Alamgir "B Effect of Aloe Vera Gel And 1% Silver Sulphadiazine Cream in the Treatment of Superficial Burn in Children- A Comparative Study" MAR Pediatrics, Volume 2 Issue 5
www.medicalandresearch.com (pg. 10)

Mechanism of aloe vera:

Aloe Vera contains 75 potentially active constituents: vitamins (vitamins A, C and E, vitamin B12, folic acid, and choline), enzymes (alkaline phosphatase, amylase, bradykinase, carboxypeptidase, catalase, cellulase, lipase, and peroxidase), minerals (calcium, chromium, copper, selenium, magnesium, manganese, potassium, sodium and zinc), sugars (monosaccharides and polysaccharides), lignin, saponins, salicylic acids and amino acids. Salicylic acid in Aloe Vera gel possesses anti-inflammatory properties. Lignin, enhances penetrative effect of the other ingredients into the skin. Saponins that are the soapy substances form about 3% of the gel and have cleansing and antiseptic properties. Glucomannan, a mannose-rich polysaccharide, and gibberellin, a growth hormone, interacts with growth factor receptors on the fibroblast, thereby stimulating its activity and proliferation, which in turn significantly (Shahzad and Ahmed, 2013).

Dressing pain intensity decreased significantly during a 72-hour period in both areas but Aloe vera gel could reduce pain more and faster than nitrofurazone. Perhaps, the reason may be the presence of carboxy peptidase in Aloe vera which inactivates bradykinin which is the powerful factor of acute inflammatory pain. Magnesium lactate in Aloe vera gel is used as antiitching and analgesic drug by inhibiting histidine decarboxylase which controls conversion of histidine to histamine in mast cells.

Aloe vera gel extract permitted faster healing of burn, and reestablished the vascularity of burn tissues. These effects might be due to several mechanisms including an increasing collagen synthesis and rate of epithelialization by the effect of acemanan (mannose-6 phosphate) to stimulate fibroblasts, an anti-inflammatory effect, an antimicrobial effect and a moisturizing effect (Maenthaisong et al. 2007).

Methodology

Prospective comparative interventional study was carried out in the Division of Paediatric Surgery, Bangladesh Institute of Child Health (BICH), Dhaka Shishu (Children) Hospital. Total 40 patients admitted with superficial burn during the study period were allocated in two groups by simple random sampling. Among them 20 sample were Group A patients dressing was done by Aloe vera gel and 20 sample were Group B patients dressing was done by 1% SSD.

Results

The mean pain relief time was found 2.60 ± 1.27 days in group A and 3.95 ± 0.99 days in group B. The difference was statistically significant ($p < 0.05$) between two groups. The mean wound healing time was found 5.15 ± 1.56 days in group A and 8.25 ± 2.40 days in group B. The difference was statistically significant ($p < 0.05$) between two groups. One (5.0%) patients were found wound infection in group A and 2(10.0%) in group B. The mean treatment cost was found 62.4 ± 26.4 Taka in group A and 516.4 ± 217.7 Taka in group B. Thirteen (65.0%) patients were found hospital stay 1-5 days in group A and 16(80.0%) were hospital stay 6-10 days in group B. The difference were statistically significant ($p < 0.05$) between two groups.

Discussion

In present study showed that mean wound healing time was found 5.15 ± 1.56 days in group A and 8.25 ± 2.40 days in group B. The difference was statistically significant ($p < 0.05$) between two groups. Shahzad and Ahmed (2013) time taken for partial thickness burns to heal was significantly shorter with aloe than in those treated with SSD (11 ± 4.18 days vs. 24.24 ± 11.16 days). Khorasani et al. (2009) study has demonstrated antimicrobial effect of aloe vera, but in our There were no differences in wound infection between both groups. Thamlikitkul et al. (1991) used Aloe fresh mucilage in 38 patients and found accelerated healing. Visuthikosol et al. (1995) reported a study on 27 patients with partial thickness burn wounds treated either with gauze dressings saturated with Aloe vera gel. They observed significantly reduced wound healing time in the aloe-treated patients (11.19 days vs 11.89 days). Akhtar and Hatwar (1996) also observed significantly reduced wound healing time in the aloe-treated patients 18 ± 18.9 days. Khorasani et al. (2009) observed that the mean times for healing were 18.73 ± 2.65 and 15.9 ± 2 days for SSD and aloe creams, respectively, being significantly shorter for aloe cream ($P < 0.0001$).

In current study observed that 1(5.0%) patients was found wound infection in group A and 2(10.0%) in group B. The difference was not statistically significant ($p > 0.05$) between two groups. Shahzad and Ahmed, (2013) reported that the antimicrobial effect of silver sulphadiazine is the only mechanism justifying its continued use in burn injury. However, resistance has been demonstrated. Hepatic or renal toxicity and leukopenia may be caused by the topical application of SSD. In fact, these side effects have been observed in the treatment of large wounds (Visuthikosol et al. 1995; Atiyeh et al. 2007; Klasen, 2000).

In current study showed that mean treatment cost was found 62.4±26.4 Taka in group A and 516.4±217.7 Taka in group B. Thirteen (65.0%) patients were found hospital stay 1-5 days in group A and 16(80.0%) were hospital stay 6-10 days in group B. The difference were statistically significant ($p<0.05$) between two groups.

In this study observed that majority (45.0%) patients were belonged to age ≤ 24 months in group A and 14(70.0%) in group B. The mean age was found 39.40±27.33 months in group A and 29.05±19.76 months in group B. The mean age difference was not statistically significant ($p>0.05$) between two groups. Jozsa et al. (2018) reported most of the studied children were <5 years of age. Sunburns are the most common and preventable type of burns in children, affecting up to 50% of children before 11 years of age (Yin, 2017). Scalds are the most common type of burns in children five years or younger and are often a result of spilling hot liquids during cooking (Herndon, 2017).

In this study observed that almost two third (65.0%) patients were male in group A and 14(70.0%) in group B. The difference was not statistically significant ($p>0.05$) between two groups. Shahzad and Ahmed (2013) 68.0% patients were male in aloe group and 36.0% in SSD group.

Conclusion

In conclusion aloe vera gel promoted wound healing, early pain relief and cost effective for the management of superficial burn in children. So it can be used as an alternative to 1% silver sulphadiazine in superficial burn management in children for getting better outcome.

References

1. Akhtar, M.A. and Hatwar, S.K., 1996. Efficacy of aloe vera extract cream in management of burn wound. *Journal of Clinical Epidemiology*, 49, p.S24.
2. Charles, L., 1974. Mechanism of Silver Sulfadiazine Action on Burn Wound Infection. *Antimicrobial Agent and Chemotherapy*, pp.582-588.
3. Chung, D.H., David, N. and Herndon, D.N., 2005. Burns. In: Ashcraft, K.W., Hilcomb, C.W., Murphy, J.P. (eds.) *Paediatric surgery*. 4th ed. Philadelphia: Elsevier Saunders, pp.156-159.
4. Hettiaratchy, S. and Papini, R., 2004. Initial management of a major burn: II—assessment and resuscitation. *BMJ*, 329(7457), pp.101-103.

5. Hettiaratchy, S. and Dziewulski, P., 2004. ABC of burns: pathophysiology and types of burns. *British Medical Journal*, 328: 1427-9.
6. Jozsa, G., Vajda, P., Garami, A., Csenkey, A. and Juhasz, Z., 2018. Treatment of partial thickness hand burn injuries in children with combination of silver foam dressing and zinc-hyaluronic gel. *Medicine*, 97(13).
7. Khorasani, G., Hosseinimehr, S.J., Azadbakht, M., Zamani, A. and Mahdavi, M.R., 2009. Aloe versus silver sulfadiazine creams for second-degree burns: a randomized controlled study. *Surgery today*, 39(7), pp.587-591.
8. Klasen, H.J., 2000. A historical review of the use of silver in the treatment of burns. II. Renewed interest for silver. *Burns*, 26(2), pp.131-138.
9. Maenthaisong, R., Chaiyakunapruk, N., Niruntraporn, S. and Kongkaew, C., 2007. The efficacy of aloe vera used for burn wound healing: a systematic review. *Burns*, 33(6), pp.713-718.
10. Munteanu, A., Florescu, I.P. and Nitescu, C., 2016. A modern method of treatment: The role of silver dressings in promoting healing and preventing pathological scarring in patients with burn wounds. *Journal of medicine and life*, 9(3), p.306.
11. Shahzad, M.N. and Ahmed, N., 2013. Effectiveness of Aloe vera gel compared with 1% silver sulphadiazine cream as burn wound dressing in second degree burns. *J Pak Med Assoc*, 63(2), pp.225-30.
12. Surjushe, A., Vasani, R. and Saple, D.G., 2008. Aloe vera: a short review. *Indian journal of dermatology*, 53(4), p.163.
13. Thamlikitkul, V., Bunyaphatsara, N., Riewpaiboon, W., Theerapong, S., Chantrakul, C.,
14. Visuthikosol, V., Chowchuen, B., Sukwanarat, Y., Sriurairatana, S. and Boonpucknavig, V., 1995. Effect of aloe vera gel to healing of burn wound a clinical and histologic study. *J Med Assoc Thai*, 78(8), pp.403-9.
15. Vloemans, A.F.P.M., Soesman, A.M., Suijker, M., Kreis, R.W. and Middelkoop, E., 2003. A randomised clinical trial comparing a hydrocolloid-derived dressing and glycerol preserved allograft skin in the management of partial thickness burns. *Burns*, 29(7), pp.702-710.

16. Yarrow, J., Moiemmen, N. and Gulhane, S., 2009. Early management of burns in children. *Paediatrics and Child Health*, 19(11), pp.509-516.
17. Yin, S., 2017. Chemical and commuion burns in children. *Clinical pediatrics*, 56(5 suppl), pp.8S-12S.