



Neonatal Hemochromatosis: A Rare Case Report with Consanguinity

Bhaskar *¹, Bhushan Miraje ², Vijaya Gavade³, Sanjog Loya³, Uday S Patil⁴, Rajendra S Patil ⁵

1. Resident Masai Childrens Hospital, Kolhapur, Maharashtra, India.
2. Teaching faculty, Masai Childrens Hospital, Kolhapur, Maharashtra, India.
3. Consultant Neonatologist, Masai Childrens Hospital, Kolhapur, Maharashtra, India.
4. MD, DCH (Professor and Dean), Masai Childrens Hospital, Kolhapur, Maharashtra, India.
5. MD, Department of Pathology, Ambika Lab, NABL accredited (NBRMC3332), Kolhapur, India.

Corresponding Author: Bhaskar, Resident Masai Childrens Hospital, Kolhapur, Maharashtra, India.

Copy Right: © 2023, Bhaskar, This is an open access article distributed under the Creative Commons Attribution License, which permits unrestricted use, distribution, and reproduction in any medium, provided the original work is properly cited.

Received Date: May 17, 2023

Published Date: June 01, 2023

Abstract

Background: Neonatal hemochromatosis (NH) is a rare and severe liver disease of mainly intra-uterine onset, characterized by neonatal liver failure, hepatic and extrahepatic iron accumulation. This leads to an altered iron metabolism with resulting siderosis, multi-organ failure and infants may be stillborn or present with advance, overwhelming liver disease. The disease represents the most common cause of liver failure in neonates and is also the most common indication for neonatal liver transplantation. We present an neonate who died at 15 days of age, and who was found to have massive iron overload in the liver. Initial treatment consisted of chelation therapy and antioxidants, but lack of laboratory and clinical improvement led to an exchange transfusion followed by the singular substitution of intravenous immunoglobulin (IVIG). Both, exchange transfusion and IVIG were given. Irrespective of all above treatment no improvement of general condition of the patient and recovery of liver synthetic function. The subsequent favorable course of the disease is described in this case report.

Introduction

In 1957 Cottier [1] first described a clinical picture in neonates comparable to hemochromatosis. Since then this rare medical condition is known as neonatal hemochromatosis (NH). Clinical presentation usually starts in utero [2] and recent investigations suggest a gestational alloimmune genesis of liver failure on the basis of an alloantibody-mediated liver injury, leading to an altered iron metabolism with resulting siderosis.[3,4,5]

Treatment options are limited and the prognosis of NH remains generally poor.[6,7] Success rates of 10 to 20% are reported for medical treatment, which consists of antioxidants and an iron chelator. Early treatment may be beneficial in those patients who present with milder phenotypes. Nevertheless, this benefit is discussed controversially in the literature.[7,8]

In cases of more severe acute liver failure and in non-responders, liver transplantation is the state-of-the-art therapy (survival rates of 50%).[6,7]

Since 2009 a new therapy regimen has been introduced in NH patients: in order to eliminate the suspected alloantibodies, which induce NH, an exchange transfusion (ET) is performed followed by a single administration of intravenous immunoglobulin (IVIG).[5,9]

We report a case of NH, which we treated with ET/IVIG early after diagnosis. Before this treatment the patient was already listed for high-urgency liver transplantation.

Case

Newborn is the first child of consanguineous parents. The mother is 24 years of age, and Gravida 1 and Para 1. There are no further chronic or liver diseases and no metabolic disorders in the family history. The female infant was born by caesarean delivery at 38 weeks of gestation. Birth weight was 2600 g (3rd to 50th centile), length 48 cm(3rd to 50th centile), and head circumference 33.5 cm(3rd to 10th centile). Apgar scores were 9 at 5 min and 10 at 10 min.

On the third day of life mother noticed increase work of breathing and abdominal distention gradually and progressed to intermittent grunting in next 72hr. Then infant developed severe jaundice,persistent hypoglycemia, ascites and progressive oxygen requirements, which resulted in admission to our neonatal unit on day ten. For initial values of coagulation and liver function parameters.Thus the combination of being small-for-gestational-age, having very highly elevated ferritin levels, hyperbilirubinemia, thrombocytopenia and liver failure made the diagnosis for NH most likely.

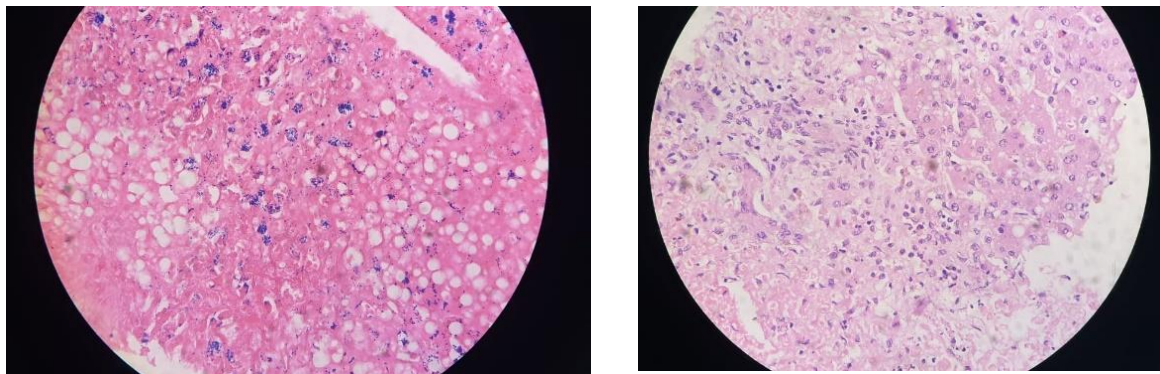
TEST	31/10/19	1/11/19	3/11/19
HB/TLC/PLT	12.6/20,760/1,04000	10.5/15,100/1,06000	11.6/7550/44,000
PT/APTT/INR	>80/120/6.2	>120/>180/1.29	40/46/3.1
SGOT/SGPT		4840/1411	—/402.1
Sr.AMMONIA/ LACTATE		348/120.5	
Sr.NA/K/CL		130/6/99	120.1/—/—
Sr.CREATININE/ B.UREA		1.58/88.5	0.6/—

TORCH	-ve IgM
Sr.KETONE	0.1
Sr.TRIGLY	91.6
Sr.FERRITIN	>100000
URINE R/M	NORMAL
Sr.CREATININE	0.6
BLOOD CULTURE	-ve
Sr.BIL T/D	9/2.9
Sr.ALBUMIN	3.40
FIBRINOGEN LEVEL	<1.0

Other possibilities for differential diagnosis (DIC,galactosemia, neonatal lupus erythematosus or α -1 antitrypsin deficiency) could be excluded clinically or by urine and blood testing.

From the first day of admission, daily administration of fresh frozen plasma was mandatory in order to keep coagulation parameters in measureable ranges and avoid spontaneous bleeding. On day 12 of life the administration of a chelation-antioxidant therapy (deferoxamine (40 mg–1kg–1 per day), vitamin E (30 IU–1kg–1 per day), selenium (3 μ g–1kg–1 per day) and acetylcysteine (150 mg–1kg–1 per day)) was started. Prostaglandin E1 had not been administered due to potential adverse effects. This treatment did not appear to be of any benefit for the patient.

Thus suspecting NH liver biopsy,buccal mucosa was taken,



Which eventually confirmed the diagnosis of NH. Thus, on day 13 full double volume exchange transfusion according to Rand et al.¹⁰ was performed, followed by the administration of IVIG (1 g kg–1). Both, ET and IVIG were tolerated well. In the following days the general condition of the patient not improved and liver synthetic function not stabilized and started to slowly detoreated.Thus diagnosis was conformed as NH with excess accumulation of iron in hepatocytes .Next plan of treatment to refer for higher centers for liver transplantation.Final diagnosis ,treatment and outcome is

explained to family members, Thus they are not willing for further management & treatment. Antioxidant therapy was stopped without any following clinical or laboratory deterioration. Finally despite of all treatment given above patient was decreased on day 15.

Discussion

NH remains a severe, life threatening and often lethal multiorgan disorder of iron metabolism.¹¹ It manifests at birth or during the first week of life with severe hepatic failure and alloimmune genesis on the basis of an alloantibody-mediated process has been suggested.^[3,5,7] Diagnosis is confirmed by the demonstration of extrahepatic siderosis.

This diagnosis remains a challenge in early stages. In the late 1990's in many cases of NH diagnosis was only possible by taking the family history of affected children revealing that a sibling already died of liver disease.^[8] Nowadays, early diagnosis is feasible by exclusion of differential diagnosis and confirmation with a biopsy of oral mucosa.

After the introduction of antioxidant therapy, liver transplantation appeared to be a potential cure. In 2007 Timpani et al.^[5] were the first to report a case of a patient with NH whose positive outcome could have been related to having been given an exchange transfusion, followed by Escolano-Margrit et al.^[9] Rand et al.^[10] compared 13 newborns treated with IVIG/ET to historical controls 2 years later. In this regimen double volume exchange transfusion is intended to remove >90% of alloimmune antibodies and IVIG is given in order to displace specific reactive IgG. Outcome of the IVIG/ET cohort appeared to be significantly improved with 75% who did not need liver transplantation compared with 17% in the historical control group. Similar to our patient, many patients of this study group were treated with both chelation-antioxidant therapy and IVIG/ET. These results suggest, along with our case report, that the chelation-antioxidant combination seems to be of little help in severe cases of NH.
[6,8,10]

In our neonate, the course of disease remains rapid deterioration. ET/IVIG administration, which should eliminate the ongoing loss of hepatocyte function to permit survival, was safe and well tolerated. Initially ET/IVIG showed improved the patient's general condition and liver synthetic function, but due to massive iron deposition in liver, heart, endocrine organs with multiorgan failure was decreased.

Conclusion

Thus NH seems to be a gestation alloimmune disease, and recurrence of severe neonatal hemochromatosis in at-risk pregnancies may be reduced by maternal treatment with weekly (beginning gestational age 18wk) high-dose intravenous immunoglobulin (1gm/kg) during gestation. After birth, affected neonates are treated with exchange transfusion and intravenous immunoglobulin, which improves survival and reduced the need for transplantation, as repeated affected neonates in the same family are common.

Early application of ET/IVIG is a feasible and effective treatment in NH to potentially prevent liver transplantation and allows a positive impact on the course of the disease.

Reference

1. Cottier H, Vogt W . Über ein der Hämochromatose vergleichbares Krankheitsbild bei Neugeborenen. Schweiz Med Wochenschr 1957; 37: 39–43. GoogleScholar
2. Murray KF, Kowdley KV . Neonatal hemochromatosis. Pediatrics 2001; 108 (4): 960–964. CAS Article GoogleScholar
3. Whittington PF . Neonatal hemochromatosis: a congenital alloimmune hepatitis. Semin Liver Dis 2007; 27 (3): 243–250. CAS Article GoogleScholar
4. Whittington PF, Kelly S . Outcome of pregnancies at risk for neonatal hemochromatosis is improved by treatment with high-dose intravenous immunoglobulin. Pediatrics 2008; 121 (6): e1615–e1621. Article GoogleScholar
5. Timpani G, Foti F, Nicolo A, Nicotina PA, Nicastro E, Iorio R . Is exchange transfusion a possible treatment for neonatal hemochromatosis? J Hepatol 2007; 47 (5): 732–735. CAS Article GoogleScholar
6. Flynn DM, Mohan N, McKiernan P, Beath S, Buckels J, Mayer D et al. Progress in treatment and outcome for children with neonatal haemochromatosis. Arch Dis Child Fetal Neonatal Ed 2003; 88 (2): F124–F127. CAS Article GoogleScholar
7. Rodrigues F, Kallas M, Nash R, Cheeseman P, D'Antiga L, Rela M et al. Neonatal hemochromatosis--medical treatment vs transplantation: the king's experience. Liver Transpl 2005; 11 (11): 1417–1424. Article GoogleScholar

8. Sigurdsson L, Reyes J, Kocoshis SA, Hansen TW, Rosh J, Knisely AS . Neonatal hemochromatosis: outcomes of pharmacologic and surgical therapies. *J Pediatr Gastroenterol Nutr* 1998; 26 (1): 85–89.CAS Article GoogleScholar
9. Escolano-Margarit MV, Miras-Baldo MJ, Parrilla-Roure M, Rivera-Cuello M, Narbona-Lopez E . Exchange transfusion as a possible therapy for neonatal hemochromatosis. *J Pediatr Gastroenterol Nutr* 2010; 50 (5): 566–568.PubMed GoogleScholar
10. Rand EB, Karpen SJ, Kelly S, Mack CL, Malatack JJ, Sokol RJ et al. Treatment of neonatal hemochromatosis with exchange transfusion and intravenous immunoglobulin. *J Pediatr* 2009; 155 (4): 566–571.CAS Article GoogleScholar
11. Grabhorn E, Richter A, Burdelski M, Rogiers X, Ganschow R . Neonatal hemochromatosis: long-term experience with favorable outcome. *Pediatrics* 2006; 118 (5): 2060–2065.Article GoogleScholar