



Case Series of Complications After Nuss Bar Removal Procedure for Pectus Excavatum. Analysis of Complications and Proposal of a Safety Protocol

Joaquín Pedro Camacho, MD ^{*1}, Rocio Boudou, MD ¹, Pablo Andrés Lobos, MD ¹,
Juan Manuel Moldes, MD ¹, Gastón Ricardo Elmo, MD ¹

1. Pediatric Surgery & Urology Department, Hospital Italiano de Buenos Aires.

***Correspondence to:** Joaquín Pedro Camacho, Pediatric Surgery & Urology Department, Hospital Italiano de Buenos Aires.

Copyright

© 2023 Joaquín Pedro Camacho. This is an open access article distributed under the Creative Commons Attribution License, which permits unrestricted use, distribution, and reproduction in any medium, provided the original work is properly cited.

Received: 01 June 2023

Published: 15 June 2023

Keywords: *Pectus Excavatum; Hemothorax; Angiography; Bar Removal Complications*

Abstract

Background: The Nuss bar extraction procedure may bring about different complications. Some of them are mild and of easy resolution, while others can be life-threatening. An adequate surgery setup and the fulfillment of some security steps may reduce the incidence of complications.

This study aims to analyze our experience with the complications that occurred during bar removal and our safety protocol for the prevention and management of these complications.

Materials and methods: The following study is a case series of patients treated at a University hospital. An observational cohort study from a retrospective chart review of all patients who underwent Nuss bar removal from November 2013 to March 2022. Variables analyzed include, among others: patients' demographics, the presence of comorbidities, the time elapsed from bar placement to removal, and the occurrence of operative and postoperative complications.

This case series has been reported per the 'PROCESS Guideline'.

Results: There were 40 patients included in the study; 37 were male. One bar was removed in 17 patients and two in 22 patients. The median age at surgery was 17.5 years (Percentile 25-75%: 16.75 - 19.25). The time elapsed from bar placement to removal was 26 months (Percentile 25 - 75%: 23.75 - 30.25). There were ten complications in nine patients (22.5%); two wound dehiscences that were solved with no surgical intervention; two keloid scars one of which required plastic surgery; two surgical site infections, both managed with antibiotics; two grade 1 pneumothoraces and one mild pleural effusion that cured spontaneously and finally one severe hemorrhage from the left internal mammary artery. There were six complications class I (67%), two class II (22%), one class IIIb and one class IV, according to the Clavien- Dindo classification. The severe hemorrhagic complication motivated us to develop a bar-removal safety protocol to reduce the incidence of complications.

Conclusion: Nuss bar removal is a safe procedure with usually scant complications. However, it should not be underestimated since, in some cases, these drawbacks might be serious. Having a safety protocol that allows the surgical team to have a controlled procedure is of utmost importance.

Abbreviations

C-D: Clavien-Dindo.

PICU: Pediatric intensive care unit

Introduction

Removing surgical implants after a successful Nuss procedure for correcting pectus excavatum is usually a safe operation. However, several different complications can occur. According to published reports, about 4% of bar removals result in complications, the most common being seroma, surgical site infection, and wound dehiscence (5). Minor complications are relatively easy to manage with simple maneuvers such as incision and drainage, antibiotics, and pressure dressings. Major complications, including vascular injuries and life-threatening hemorrhage, require much more aggressive interventions, such as reoperation or endovascular procedures (10).

To the best of our knowledge, despite being potentially life-threatening, there is no standardized protocol to reduce the incidence of complications following bar extraction. This report aims to describe the complications related to the removal of the chest bars and their management. Additionally, we propose a protocol to minimize the incidence of these complications.

Materials and Method

The following study is a case series of patients treated at our institution. We conducted a retrospective chart review of all patients who underwent Nuss bar removal from November 2013 to March 2022. Information was collected from the department's surgical records keeping patients' identities confidential.

The analyzed variables included: patients' demographics (sex, age, presence of comorbidities), the time elapsed from bar placement to removal, the number of bars extracted, and the occurrence of operative and postoperative complications (Table 1).

This case series has been reported in line with the PROCESS Guideline (PROCESS Checklist at references)

Results

Forty patients were included in the study, 37 of which were male. One bar was removed in 17 patients, and two bars in the remaining 23 patients. Mean age at removal was

17.5 years (Percentile 25 - 75%: 16.75 - 19.25). After placement, the bars were removed after a median time of 26 months (Percentile 25 - 75%: 23.75 - 30.25).

There were ten complications in nine patients (22.5%) described in Table 1; two wound dehiscences that resolved with no surgical intervention; two keloid scars, one of which required plastic surgery; two surgical site infections, both managed with antibiotics; two grade 1 pneumothoraces and one mild pleural effusion that cured spontaneously and finally one severe hemorrhage coming from three branches of the left internal mammary artery, the pericardiophrenic artery (Figure 1: *a) and two anterior intercostal arteries (Figure 1: *b / *c) which were finally controlled with angiography and endovascular embolization (Figure 2).

Initially, in this last patient, a Video-assisted Thoracoscopy was conducted, without being able to control the bleeding (the patient lost about 1500 ml of blood during the procedure). Therefore, a Thoracotomy was performed.

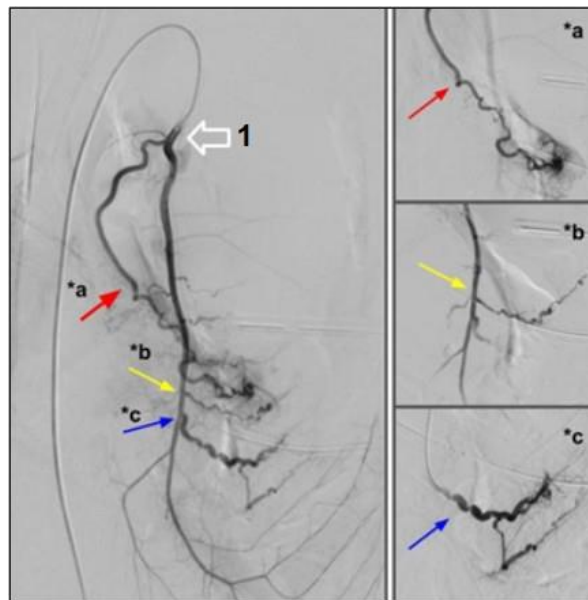


Figure 1 - Pre-embolization: Anomalous left mammary artery angiography (1: big white arrow) showing pericardiophrenic artery (arrow a*) which showed active bleeding and tortuous intercostal branches with marked hyperemia (arrows b*, c*) which were embolized.

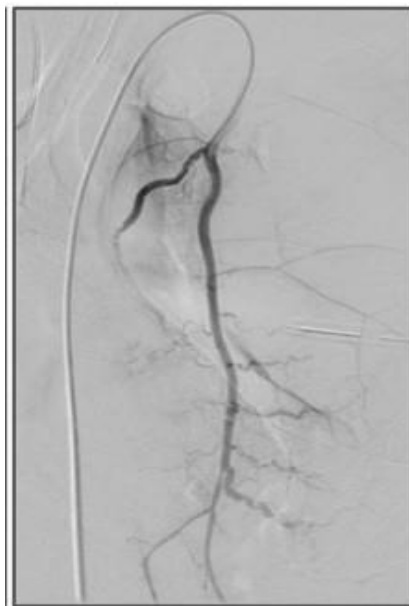

Figure 2 - Post-embolization: Anomalous branches without flow after embolization. Selective catheterization of these branches was done with a 4 Fr vertebral catheter and a 2.8 Fr microcatheter. All vessels were embolized with N-butyl-2-cyanoacrylate mixed with ultra-fluid lipiodol.

PATIENT	AGE (at extraction)	PREVIOUS DISEASE	N° of bars extracted	IMPLANT STAY (months)	Pop Complication	Complication treatment
1	17	NO	2	33	-	-
2	15	NO	1	18	Keloid scar	Plastic surgery
3	17		2	25	Keloid scar	Expectant management
4	19	NO	2	31	-	-
5	20	NO	2	29	-	-
6	16	NO	1	28	-	-
7	17	Moderate ventilatory insufficiency	2	26	Mild pleural effusion	Expectant management
8	16	NO	1	23	-	-
9	18	Renal Poliquistosis	2	30	-	-
10	15	NO	1	21	Pneumothorax I - wound dehiscence	Expectant management

11	20	NO	1	41	-	-
12	17	NO	1	28	Pneumothorax I	Expectant management
13	18	Marfan syndrome	1	36	-	-
14	17	NO	1	24	Severe hemorrhage	<u>VATS -Thoracotomy -Angiography</u>
15	21	NO	2	37	-	-
16	19	NO	2	30	-	-
17	21		1	36	-	-
18	17	NO	2	25	-	-
19	20	NO	1	29	-	-
20	19	NO	1	30	-	-
21	15	NO	2	19	-	-
22	21	NO	1	44	-	-
23	18	NO	1	24	-	-
24	16	NO	2	23	-	-
25	19	NO	1	23	-	-
26	17	NO	2	23	-	-
27	18	Ravitch Surgery, Gilles de la Tourette.	2	26	surgical wound dehiscence	Expectant management
28	20	NO	2	25	wound infection	ATB
29	16	NO	1	23	-	-
30	20	NO	2	31	-	-
31	15	NO	2	23	-	-
32	18	BOR	2	24	-	-
33	17	Niquel allergy	2	29	-	-
34	21	NO	1	44	-	-
35	14	Leukemia	2	22	-	-
36	19	Marfan syndrome, Prune Belly syndrome	2	24	-	-
37	17	NO	2	28	-	-
38	17	NO	2	26	-	-
39	20	Inflammatory bowel disease	1	50	wound infection	ATB
40	16	NO	2	24	-	-

Median age at extraction	17,5		Median implant stay	26		
--------------------------	------	--	---------------------	----	--	--

Table 1 Patients' surgical information (POP: Postoperative)

The bleeding site was identified in the extracted rib tract. The area was cauterized, and hemostatic sutures were placed at the active bleeding sites, followed by the placement of a pleural Drainage. A second tube was inserted due to persistent bleeding and lack of lung expansion and a diagnostic and therapeutic Digital Angiography was scheduled, which revealed and embolized the bleeding vessels. Aspiration drainage was required for 11 days. Due to poor lung expansion, a Thoracotomy was performed, followed by Pleural Toilette, resulting in good lung expansion afterwards. The patient required 10 units of Red Blood Cell transfusion, 4 units of Plasma, 5 units of Platelets, and 1 unit of Cryoprecipitate.

According to the Clavien-Dindo classification, there were six complications class I (67%), two class II (22%), one class IIIb and one class IV.

The severe hemorrhagic complication motivated us to develop a bar-removal safety protocol to reduce the incidence of complications (Table 2). The components of the protocol and their rationale are explained in the Discussion.

SAFETY PROTOCOL CRITICAL ASPECTS		
PRE OPERATIVE WORK-UP	SURGERY	POST OPERATIVE FOLLOW-UP
- Blood type compatibility of the patient. Lab analysis (Coagulation profile)	- Constant monitoring of vital signs.	- Control chest x-ray.
- Control chest x-ray.	- Bilateral rectification of implants for better extraction.	- 24-hour admission in the PICU.
- Implant surgery considerations: . Use Smooth-end-bars. . Use Bilateral stabilizers to avoid dislodgment. . Plan bar removal 24 months after initial surgery.	- Required supplies: Row tape, thoracotomy box, Sengstaken-Blakemore tube, blood supply available.	- Use of a compression dressing for 10 days

Table 2 Safety Protocol Critical Aspects

Discussion

The final stage of the Nuss procedure is removing the bars 2 to 3 years after placement [1,2,5]. Throughout the years, different modifications have been made to the original technique to accomplish the procedure in a safer manner. Some authors report the use of two operating tables placed perpendicularly in a T-shape configuration to remove implants in 1 movement without bending them [8]. Others prefer to straighten the bar on both ends to decrease the risk of a mediastinal injury during the removal [3,5]. The placement of a single bar stabilizer on one side during bar placement has been described, eventually allowing to perform a single incision during removal, reducing potential complications [4].

The "safety string maneuver" is another technique to hold hemostatic control of the bar tract left after removal [6]. Systematic thoracoscopic control during bar extraction has been reported by some authors to detect potential bleeding sites [7], and postoperative control x-rays are usually indicated to identify unsuspected bleeding or air leak [11].

In our series of patients (n=40), the extraction procedure consisted of bilateral incisions and straightening of the bars before removal. During immediate follow-up, serial chest x-rays were performed to detect potential complications following the procedure, together with the control of vital signs.

When complications appear following bar removal, they are usually mild and of easy resolution. Wound seroma, infection, and dehiscence (2.36%) are the most frequently reported in the literature, followed by hematoma (0.22%) [5,8,13]. We detected ten complications in 9 of our patients (22.5%), and most were benign (67%). The Clavien-Dindo (C-D) classification [16] was used to define the severity of the complication and the therapy required to repair it. Two patients seen at the outpatient clinic had a surgical wound dehiscence. Both of them healed with medical treatment (mineral ointments), being a C-D "class I" complication. Two patients developed keloid scars. One of them required plastic surgery (C-D class IIIb), while the other one had medical treatment with good results (C-D class I). Surgical site infections were seen in two patients, which were solved with oral antibiotic therapy (C-D class II). Two patients suffered from grade 1 pneumothorax (one also suffered wound dehiscence), and one had a mild pleural effusion. All three patients resolved spontaneously (C-D class I).

Despite the described above, serious complications following surgery may still occur, and bleeding is probably the most life-threatening [10-11]. As regards the source of bleeding, some authors describe potential cardiac or great vessel injury resulting from dangerous maneuvers during bar removal [14]. Others blame an excessive inflammatory response to the implant material or previous history of cardiac surgery, which may generate surgical adhesions that could trigger bleeding when removed [7,12]. In our series, one patient had a serious bleeding complication coming from the internal mammary artery. This patient required initial re-operation and further angiography (C-D class IV).

When analyzing the potential bleeding causes, we found that this last patient had no history of previous diseases except for a slight alteration in coagulation factor VII. Concerning surgery, the bars had serrated endings. We hypothesize these two factors could have contributed to the unfavourable outcome following bar removal.

To control major postoperative bleeding, emergency surgery through thoracoscopy, thoracotomy or an anterior approach may be required to have rapid exposure and be able to control vascular injuries [10]. When bleeding persists after these first-line therapeutic options, angiography could be another alternative to be considered. Endovascular embolization was useful to finally constrain bleeding in our patient.

This severe complication led to a detailed analysis of what happened and stimulated the proposal of a safety protocol to prevent this and other types of complications in the future.

Our safety protocol includes preoperative, operative, and postoperative measures (Table 2). We believe that dentated bars should be avoided, if possible, during the bar placement. Smooth-ending bars are available nowadays. This would help reduce the risk of vascular lesions during removal.

Regarding the pre-work-up, routine lab analysis should include blood type compatibility of the patient to reduce waiting time if blood is required in an emergency. An initial chest x-ray is useful to depict the correct position of bars without any unnoticed displacement or dislodged screw.

During surgery, we think that it is safe and useful to make bilateral incisions over the bar stabilizers (placed during the initial operation) and ensure proper rectification of implants for smooth extraction. This would prevent vascular tear by unbent ends. We routinely tie row tape to one of the ends of the bar before extraction so as to pass it side to side along the tract and be able to exert pressure up or downwards so as to stop active bleeding if it occurs (“safety string maneuver” [6]). A thoracotomy emergency box and a Sengstaken-Blakemore (SB) tube are always available for use if necessary as we believe that an insufflated SB tube placed along the bleeding tract could help with the hemostasis.

Post-operative follow-up, now adopted as the standard of care, includes post-operative immediate admission to the PICU for the first 24 hours to control the patient's hemodynamics and pain. A chest x-ray is done the same day after surgery, and previous discharge the next day. As it is known, it would help to rule out complications related to bleeding, pneumothorax or pleural effusions. Following discharge, we indicate the use of a compressive dressing for 10 days in order to reduce the risk of seroma and hematoma.

After the severe bleeding complication, some concepts of the security protocol depicted above started to be implemented in our institution. As already described, Table 1 shows patients surgical information in a chronological order. The table clearly shows the decreasing tendency in complications after the hemorrhagic event.

Only 3 complications occurred in the last 26 patients (11.5%) compared to 7 complications in the first 14 patients (50%) before the event. What is the most probable explanation for this to have occurred? Is it that the team gained experience, or did the safety protocol result in the reduction of postoperative adverse events? We believe it would be relevant to evaluate in a prospective manner the outcomes of the patients operated under the application of the safety protocol to assess its effectiveness.

This leads to the main limitations of this article which include the short number of patients addressed and the fact that its design corresponds to a retrospective chart review.

A prospective study comparing patients to whom these safety measures were applied versus those who received standard care should be carried out to evaluate the effectiveness of the safety protocol.

Conclusions

Nuss bar removal is a safe procedure with usually scant and benign complications. However, they should not be underestimated. In some cases, these could be serious and life-threatening. In our experience, we believe it is of utmost importance to have a safety protocol, a prepared surgical team, and adequate supplies to achieve a successful and safe procedure.

References

1. Nuss D, Kelly RE, Croitoru DP, Katz ME. A 10 year review of a minimally invasive technique for the correction of pectus excavatum. *J Pediatr Surg* 1998; 33(04): 545-552
2. Kelly RE, Obermeyer RJ, Goretsky MJ et al. Recent Modifications of the Nuss Procedure. *Annals of Surgery* 2020; 20 (20):1-7.
3. Noguchi M, Fujita K. A new technique for removing the pectus bar used in the Nuss procedure. *J Pediatr Surg* 2005; 40:674-7.
4. Varela P, Romanini MV, Asquasciati C, Torre M. A simple technique for removing the Nuss bar with one stabilizer: the lateral approach. *J Laparoendosc Adv Surg Tech A* 2020; 42: 1789-91.
5. Park HJ, Kim KS. Pectus bar removal: surgical technique and strategy to avoid complications. *J Vis Surg*. 2016; 2: 60.
6. Toselli L, Bellia Munzón G, Martínez J et al. safety string: A handy maneuver to control Pectus bar removal bleeding complications, *Journal of Pediatric Surgery*. 2020
7. Carlucci M, Torre M, Jasonni V. An uncommon complication of Nuss bar removal: Is blind a safe procedure? *J Ped Surg case Reports*. 2013; 1 34-35.

8. Fike FB, Mortellaro VE, Iqbal CW, Sharp SW, Ostlie DJ, Holcomb GW, et al. Experience with a simple technique for pectus bar removal. *J Pediatr Surg* 2012; 47: 490-493
9. Park HJ, Lee SY, Lee CS. Complications associated with the Nuss procedure: analysis of risk factors and suggested measures for prevention of complications. *J Pediatr Surg*. 2004; 39:391-5.
10. Bilgi Z, Ermerak NO, Cetinkaya C et al. Risk of serious perioperative complications with removal of double bars following the Nuss procedure. *Interact Cardiovas Thorac Surg* 2017; 24:257-9.
11. Cohen NS, Goretsky MJ, Obermayer RJ. Bleeding at removal of nuss bar: rare but sometimes significant. *J Laparoendosc Adv Surg Tech* 2018; 28: 1393-6.
12. Haecker FM, Berberch TB, Mayr JM et al. Near- fatal bleeding after transmyocardial ventricle lesion during removal of pectus bar after the Nuss procedure. *The Journal of Thoracic and Cardiovascular Surgery*. 2009; 138, 5 1240-1241.
13. Kelly RE, Goretsky MJ, Obermeyer R et al. Twenty one years of experience with minimally invasive repair of pectus excavatum by de Nuss procedure in 1215 patients. *Ann Surg* 2010;252:1072-81.
14. Bouchard S, Hong AR, Gilchrist BF et al. Catastrophic cardiac injuries encountered during the minimally invasive repair of pectus excavatum. *Semin Pediatr Surg* 2009; 18: 66-72
15. Park JP, Kim KS, Moon YK, Lee S. The bridge technique for pectus bar fixation: a method to make the bar un- rotatable. *J. Pediatr Surg*. 2015. 50(8): 1320-2.
16. Clavien PA, Barkun J, de Oliveira ML, Vauthey JN, Dindo D, Schulick RD, de Santibañes E, Pekolj J, Slankamenac K, Bassi C, Graf R, Vonlanthen R, Padbury R, Cameron JL, Makuuchi M. The Clavien-Dindo classification of surgical complications: five-year experience. *Annals of surgery*. 2009 Aug;250(2):187-96.

