



**Advanced Neuroendocrine Carcinoma of the Ovary- Diagnostic
Challenges and Therapeutic Insights - A Case Report and Literature
Review**

Dr Praneet Singh Bedi¹, Dr Maheboob Hussain Shaik¹, Dr. Asif Baliyan²

1. Department of medical oncology, Max Super speciality hospital, Delhi, India.
2. Department of Pathology, Max Super speciality Hospital

***Correspondence to:** Dr Praneet Singh Bedi, Department of medical oncology, Max Super speciality hospital, Delhi, India.

Copyright.

© 2025 **Dr Praneet Singh Bedi** This is an open access article distributed under the Creative Commons Attribution License, which permits unrestricted use, distribution, and reproduction in any medium, provided the original work is properly cited.

Received: 25 March 2025

Published: 01 April 2025

DOI: <https://doi.org/10.5281/zenodo.15782000>

Abstract:

Background: Advanced neuroendocrine carcinoma (NEC) of the ovary is an exceedingly rare and aggressive malignancy, often presenting diagnostic and therapeutic challenges. Its rarity necessitates a detailed exploration of clinical presentation, diagnostic workup, and therapeutic outcomes.

Case Presentation: We report the case of a 67-year-old female who presented in August 2023 with abdominal pain, distension, and a history of recurrent malignant ascites. She was admitted and underwent diagnostic and therapeutic ascitic tapping, with 4 liters of fluid drained. Further evaluation included PET-CT imaging (August 23), which revealed FDG-avid bilateral adnexal masses, omental caking, peritoneal deposits, and moderate ascites. Histopathological examination of an omental biopsy done in August 2023 showed morphology and an immunoprofile suggestive of neuroendocrine carcinoma, small-cell type (Müllerian origin). Immunohistochemistry (IHC) demonstrated positivity for CK7, PAX8, synaptophysin, and chromogranin, with a high Ki-67 proliferation index (90-95%). Molecular profiling revealed the tumor to be proficient mismatch repair (pMMR) and microsatellite stable (MSS), with BRCA1/2 mutations negative (both germline and somatic).

The patient was initiated on platinum-based chemotherapy (cisplatin and etoposide), completing six cycles with a significant initial therapeutic response noted in an interim PET-CT scan (February 2024). However, disease progression was observed with increased tumor burden on subsequent imaging (March 2024). She was transitioned to second-line therapy with the FOLFIRINOX regimen in March 2024, which showed a significant interim response on follow-up PET-CT scans (June 2024). The patient's condition continues to be monitored, with ongoing chemotherapy providing further disease control. She completed six cycles in October 2024, and a PET-CT scan post-second-line chemotherapy showed further response. This case illustrates the challenges of managing advanced ovarian NEC, emphasizing the need for a multimodal therapeutic approach.

Discussion: *This case emphasizes the diagnostic complexity and therapeutic challenges in managing advanced ovarian NEC. The use of histopathological markers, imaging modalities, and tailored systemic therapies played a critical role in disease management. The patient's partial response to second-line treatment highlights the potential of multimodal approaches for aggressive NEC subtypes.*

Conclusion: *This report underscores the importance of individualized treatment strategies and interdisciplinary collaboration in managing rare and aggressive ovarian NEC. It contributes valuable insights into diagnostic challenges and therapeutic responses, enriching the limited literature on this rare malignancy.*

Keywords: *Neuroendocrine carcinoma, ovarian cancer, small-cell carcinoma, Mullerian origin, metastatic cancer, rare malignancy, chemotherapy, diagnostic challenges.*

Introduction

Neuroendocrine carcinoma (NEC) of the ovary is an uncommon malignancy, often characterized by aggressive behavior and poor prognosis. These tumors are histologically diverse and can present diagnostic challenges due to overlapping features with other ovarian neoplasms. Advanced NEC is typically identified at late stages, given its subtle initial symptoms and rapid progression. This report explores the diagnostic journey, therapeutic interventions, and clinical outcomes of a rare case of metastatic ovarian NEC, aiming to provide valuable insights for clinicians managing such cases.

Background

Neuroendocrine carcinoma (NEC) represents a diverse group of malignancies that arise from neuroendocrine cells dispersed throughout the body. These tumors exhibit variable biological behaviors, ranging from indolent to highly aggressive. Ovarian NECs are particularly rare, comprising a small subset of ovarian cancers, and are often associated with an aggressive clinical course and poor prognosis. The classification of NECs typically includes small-cell and large-cell variants, with small-cell NECs being notably aggressive.

The pathogenesis of ovarian NEC remains poorly understood, but it is hypothesized to arise from neuroendocrine differentiation of the ovarian epithelium or from teratomas. Diagnosing ovarian NEC requires a high index of suspicion, as its clinical presentation and radiologic findings often overlap with other ovarian

malignancies. Immunohistochemical (IHC) staining plays a pivotal role in distinguishing NEC from other ovarian cancers, with markers such as synaptophysin, chromogranin, and CD56 aiding in confirmation. Treatment of ovarian NEC poses significant challenges due to its rarity and aggressive nature. Most therapeutic strategies are extrapolated from the management of other neuroendocrine and small-cell carcinomas. Standard treatment typically involves systemic chemotherapy, often with platinum-based regimens. However, due to the high recurrence rates and poor response to therapy, individualized and multimodal treatment approaches are essential. This case report aims to contribute to the limited literature on ovarian NEC, emphasizing the importance of early diagnosis, molecular profiling, and tailored therapeutic interventions.

Case Presentation

Patient History:

A 67-year-old female presented with abdominal pain, distension, and recurrent malignant ascites over two months. She underwent therapeutic ascitic tapping at another hospital, draining 4 liters of fluid. PET-CT imaging revealed FDG-avid lesions in the bilateral adnexal regions, omental thickening, peritoneal deposits, and moderate ascites.

3. Molecular Studies: The tumor was pMMR with stable microsatellite instability (MSI) and negative for germline and somatic BRCA1/2 mutations.

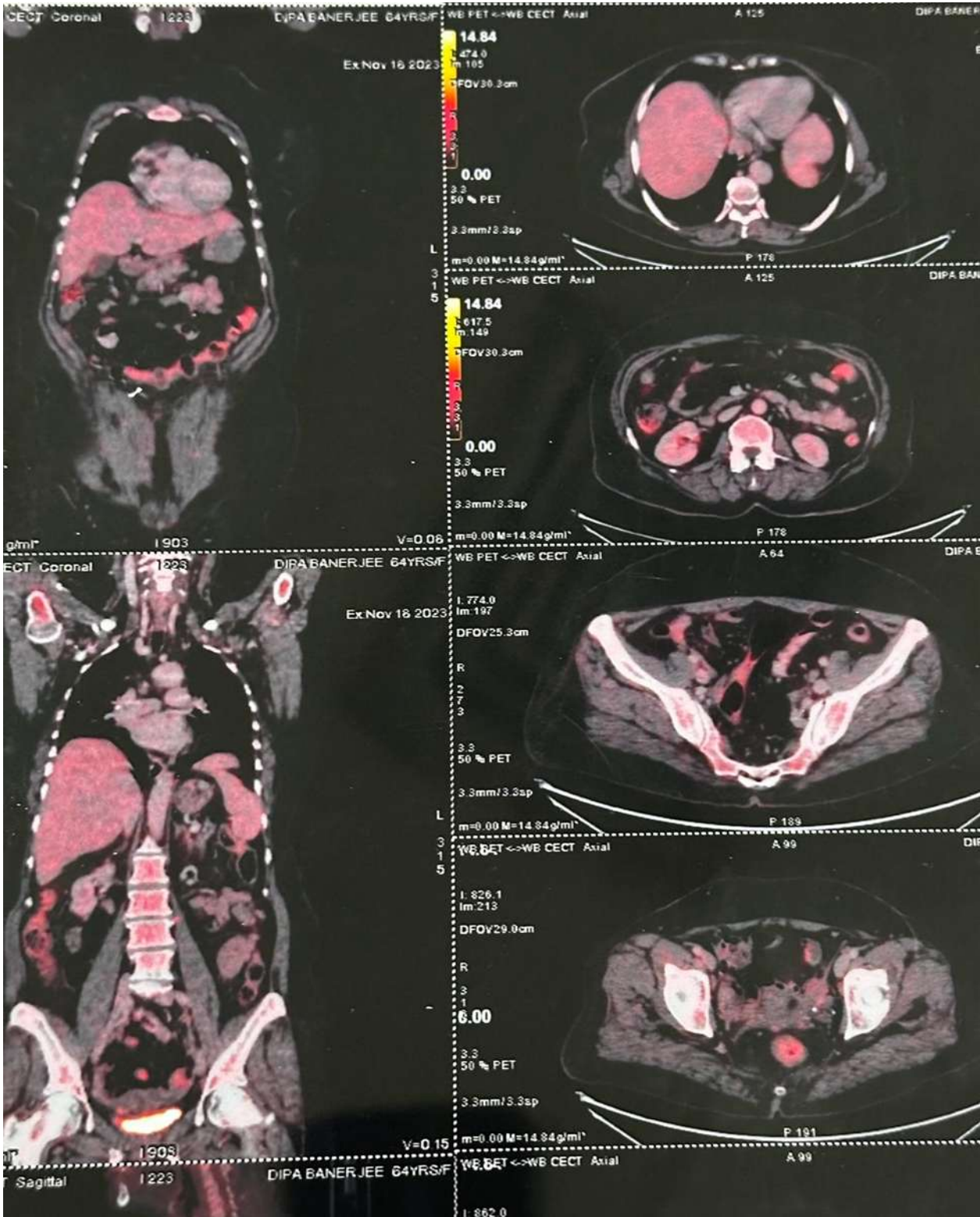


Fig 2

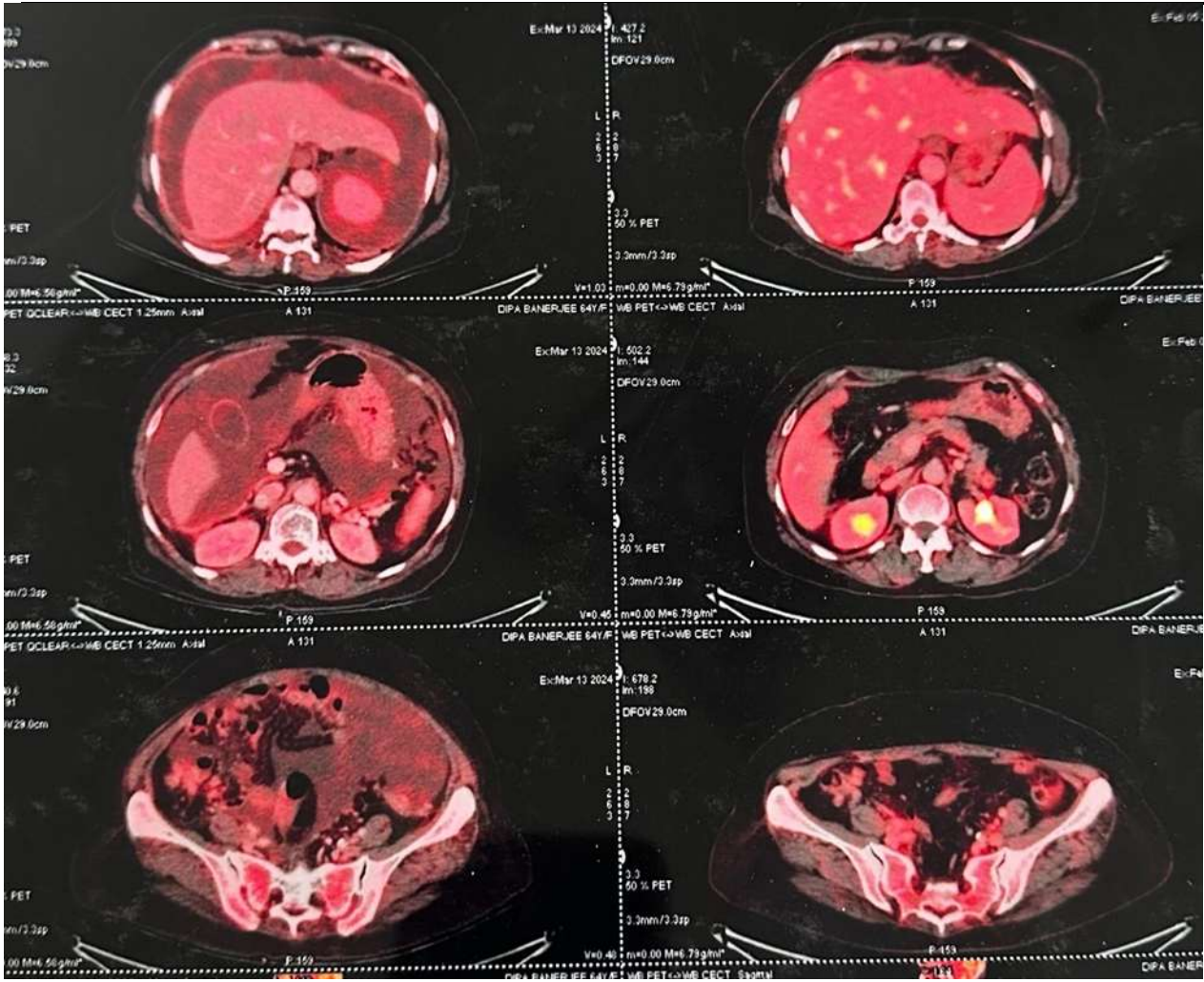


Fig 3

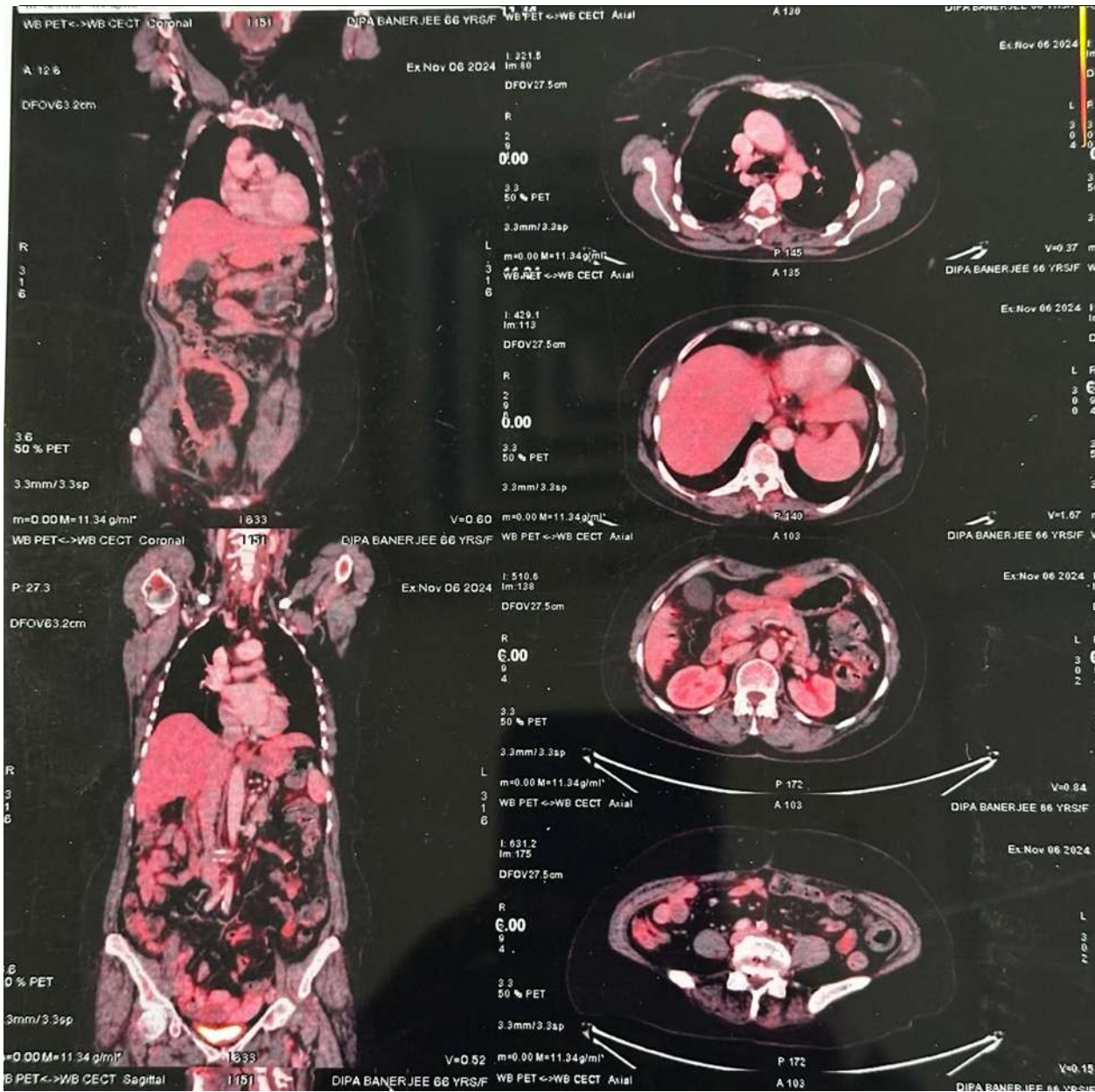


Fig 5

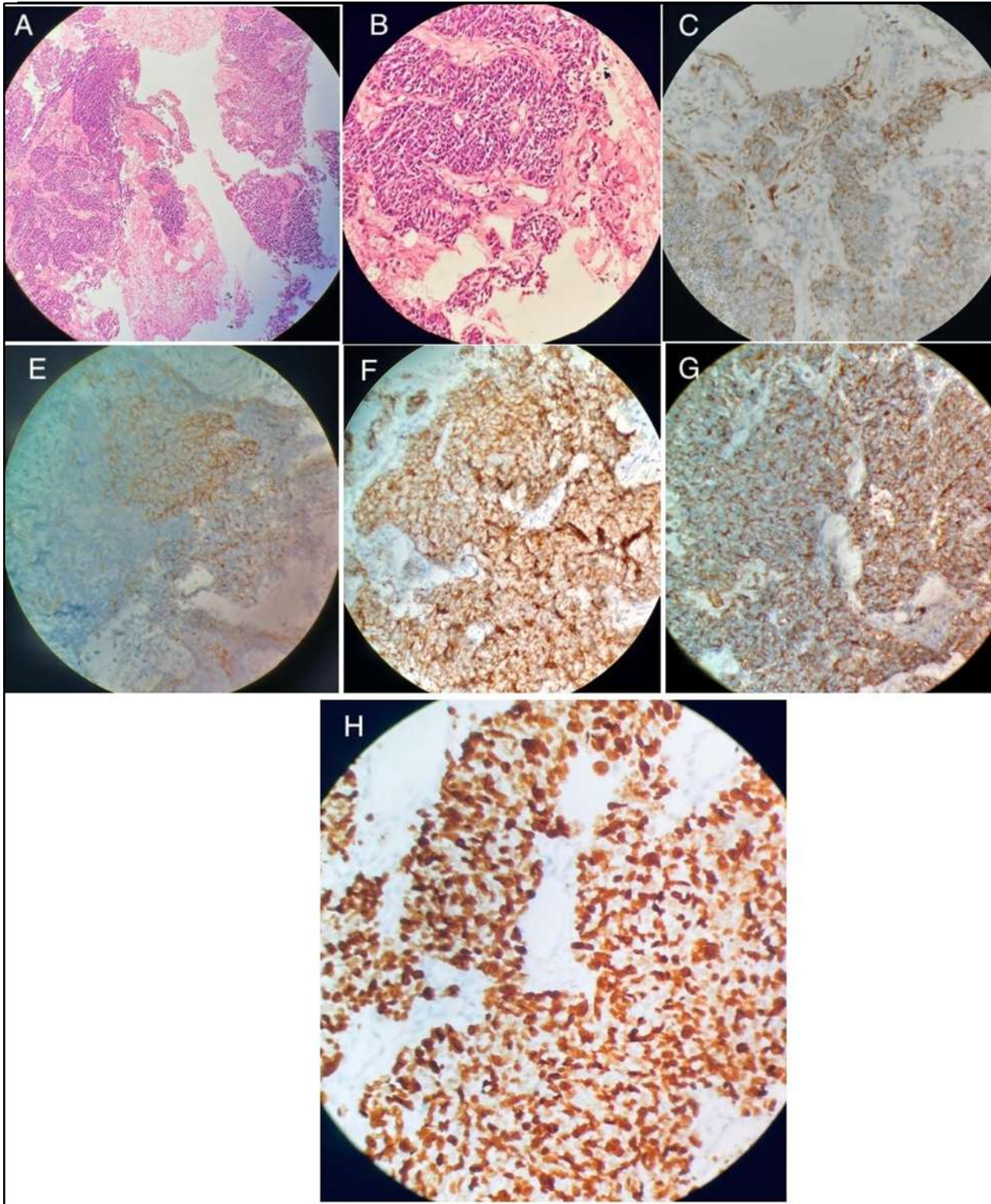


Figure 6 A & B: Histopathology images showed a malignant tumor arranged in sheets and nested patterns. The tumor cells showed hyperchromatic nuclei with stippled chromatin, nuclear molding, inconspicuous to prominent nucleoli, brisk mitosis, apoptosis, and areas of necrosis. (A-H&E 100x, B-H&E 400x); Tumor cells are positive for CK 7 (6C: 400x); CA125 (6D: 400x); Synaptophysin (6F: 400x); Chromogranin (6G: 400x). Ki67 proliferation index was 90-95% at (6H: 400x).

Treatment and Clinical Course:

First-line Therapy: The patient received six cycles of Cisplatin and Etoposide, leading to a significant response as noted on interim PET-CT scans [Fig 2]. However, disease progression was observed post-treatment.

Second-line Therapy: FOLFIRINOX was initiated following disease progression, achieving significant interim response in PET CT scan [Fig.4]. Chemotherapy was continued with a plan to reassess for surgical intervention.

Outcome: The patient's disease remained controlled with ongoing chemotherapy, demonstrating response to the second-line regimen. Monitoring of tumor markers and imaging continues to guide management.

Discussion and Literature Review

Introduction

Neuroendocrine carcinoma (NEC) of the ovary is an uncommon malignancy, often characterized by aggressive behavior and poor prognosis (Eichhorn et al., 1992). These tumors are histologically diverse and can present diagnostic challenges due to overlapping features with other ovarian neoplasms (Vang et al., 2007). Advanced NEC is typically identified at late stages, given its subtle initial symptoms and rapid progression (Park et al., 2016). This report explores the diagnostic journey, therapeutic interventions, and clinical outcomes of a rare case of metastatic ovarian NEC, aiming to provide valuable insights for clinicians managing such cases.

Background

Neuroendocrine carcinoma (NEC) represents a diverse group of malignancies that arise from neuroendocrine cells dispersed throughout the body (Gadducci et al., 2019). These tumors exhibit variable biological behaviors, ranging from indolent to highly aggressive. Ovarian NECs are particularly rare, comprising a small subset of ovarian cancers, and are often associated with an aggressive clinical course and poor prognosis (Gardner et al., 2011). The classification of NECs typically includes small-cell and large-cell variants, with small-cell NECs being notably aggressive.

The pathogenesis of ovarian NEC remains poorly understood, but it is hypothesized to arise from neuroendocrine differentiation of the ovarian epithelium or from teratomas (Yao et al., 2008). Diagnosing ovarian NEC requires a high index of suspicion, as its clinical presentation and radiologic findings often overlap with other ovarian malignancies. Immunohistochemical (IHC) staining plays a pivotal role in

distinguishing NEC from other ovarian cancers, with markers such as synaptophysin, chromogranin, and CD56 aiding in confirmation (Vang et al., 2007).

Diagnosis

The diagnosis of ovarian NEC necessitates a multidisciplinary approach, combining clinical, radiological, and histopathological evaluations. Imaging studies, including ultrasound and CT/MRI, can identify a complex adnexal mass but cannot definitively differentiate NECs from other ovarian tumors. Definitive diagnosis relies on histopathological examination and immunohistochemistry.

Treatment Modalities

The management of ovarian NEC of müllerian type lacks a standardized protocol due to its rarity. Treatment often involves a combination of surgery, chemotherapy, and sometimes radiotherapy:

1. Surgical Management: Optimal cytoreduction is the cornerstone of treatment, aiming to remove as much tumor burden as possible.

2. Chemotherapy: Platinum-based chemotherapy regimens (e.g., carboplatin and etoposide) are commonly used, extrapolated from treatment protocols for small cell lung cancer (SCLC) due to histological similarities. Additionally, regimens tailored for epithelial ovarian cancers may be considered in mixed histologies.

3. Targeted Therapies: Limited evidence exists for targeted therapies. Agents targeting neuroendocrine pathways, such as somatostatin analogs or peptide receptor radionuclide therapy (PRRT), may be of potential benefit in select cases.

4. Immunotherapy: Emerging data suggest a potential role for immune checkpoint inhibitors in high-grade neuroendocrine tumors.¹⁶ However, their efficacy in ovarian NEC remains largely unexplored.

Prognosis Ovarian NECs of müllerian type carry a poor prognosis due to their aggressive nature and high likelihood of metastasis. The 5-year survival rate is significantly lower than other epithelial ovarian cancers, particularly in advanced stages. Early diagnosis and aggressive multimodal treatment are critical for improving outcomes.

Literature Review

• **Case Reports and Series:** The existing literature primarily consists of isolated case reports and small case series. For instance, a study by Eichhorn et al. analyzed 11 cases of ovarian small cell carcinoma of the hypercalcemic type, highlighting the heterogeneity and complexity of neuroendocrine ovarian tumors.

• **Pathological Insights:** Studies emphasize the importance of accurate histological subtyping. Vang et al.

reported on the utility of immunohistochemical panels in distinguishing ovarian NECs from other high-grade ovarian malignancies.

- **Treatment Outcomes:** Retrospective analyses suggest that patients receiving multimodal therapy (surgery and adjuvant chemotherapy) have better outcomes than those managed with surgery alone. However, there is no consensus on the optimal chemotherapeutic regimen.
- **Molecular Studies:** Limited molecular profiling data exist for ovarian NEC. Studies on other neuroendocrine tumors, however, reveal potential actionable mutations, including alterations in TP53, RB1, and the PI3K/AKT/mTOR pathway, which could be extrapolated for targeted therapeutic approaches.

Conclusion

Neuroendocrine carcinoma of the ovary, müllerian type, remains a rare and poorly understood entity. Improved understanding of its molecular underpinnings and collaborative efforts to pool data through multicenter registries are critical. Future research should focus on the development of standardized treatment protocols and the evaluation of novel therapeutic agents to improve patient outcomes.

Acknowledgments

The authors thank the patient and her family for their cooperation and consent to share this case. Gratitude is also extended to the oncology team & Department of Pathology involved in her care.

Conflict of Interest: None declared.

Funding: No funding was received for this study.

References

- Eichhorn JH, Young RH, Scully RE. Primary ovarian small cell carcinoma of the pulmonary type: a clinicopathologic and immunohistochemical analysis of 11 cases. *Mod Pathol*. 1992;5(4):337-343.
- Vang R, Whitaker BP, Farinola M, et al. Immunohistochemical characterization of ovarian small cell carcinoma: a study of 30 cases. *Am J Surg Pathol*. 2007;31(6):904-915. doi:10.1097/PAS.0b013e31802dbd5c
- Gadducci A, Carinelli S, Aletti G. Ovarian neuroendocrine tumors. *Gynecol Oncol*. 2019;150(1):182-188. doi:10.1016/j.ygyno.2018.11.006
- Gardner GJ, Reidy-Lagunes D, Gehrig PA. Neuroendocrine tumors of the gynecologic tract: a Society of Gynecologic Oncology (SGO) clinical document. *Gynecol Oncol*. 2011;122(1):190-198. doi:10.1016/j.ygyno.2011.04.011
- Park JY, Hong DG, Kim HS, Kim JH, Nam JH. Prognosis of ovarian small cell carcinoma compared with

ovarian epithelial carcinoma: a single center experience. *Eur J Obstet Gynecol Reprod Biol.* 2016;203:36-41.
doi:10.1016/j.ejogrb.2016.05.019

Yao JC, Hassan M, Phan A, et al. One hundred years after "carcinoid": epidemiology of and prognostic factors for neuroendocrine tumors in 35,825 cases in the United States. *J Clin Oncol.* 2008;26(18):3063-3072.
doi:10.1200/JCO.2007.15.4377



Medtronic