



Case Report

Journal of MAR Orthopedics (Volume 3 Issue 4)

Excision of Para-Labral Cyst with Removal of Calcific Loose Bodies and Bankart Repair through Arthroscopy

Ravi Sankar Kirubanandan*.

Corresponding Author: Ravi Sankar Kirubanandan,

Copy Right: © 2022 Ravi Sankar Kirubanandan, This is an open access article distributed under the Creative Commons Attribution License, which permits unrestricted use, distribution, and reproduction in any medium, provided the original work is properly cited.

Received Date: May 02, 2022

Published Date: May 15, 2022

Abstract

Suprascapular nerve palsy is a very uncommon condition but occurs only when there is a compression of the suprascapular nerve . Because of the compression the nerve gets blocked and the patient starts to feel pain , movement restricts etc. One of the reason for such compression is para-labral cyst . Para-labral cysts are swellings that arise around the socket of the shoulder joint (glenoid). They are pockets of joint fluid that develop outside of the joint under tears of the labrum. These may occur anywhere around the glenoid. The cysts may become very large and can press on some of the important nerves around the shoulder. The suprascapular nerve can be compressed at the spinoglenoid notch with a posterior labral tear (reverse Bankart tear) or at the suprascapular notch with a SLAP tear. This can lead to a suprascapular nerve palsy.

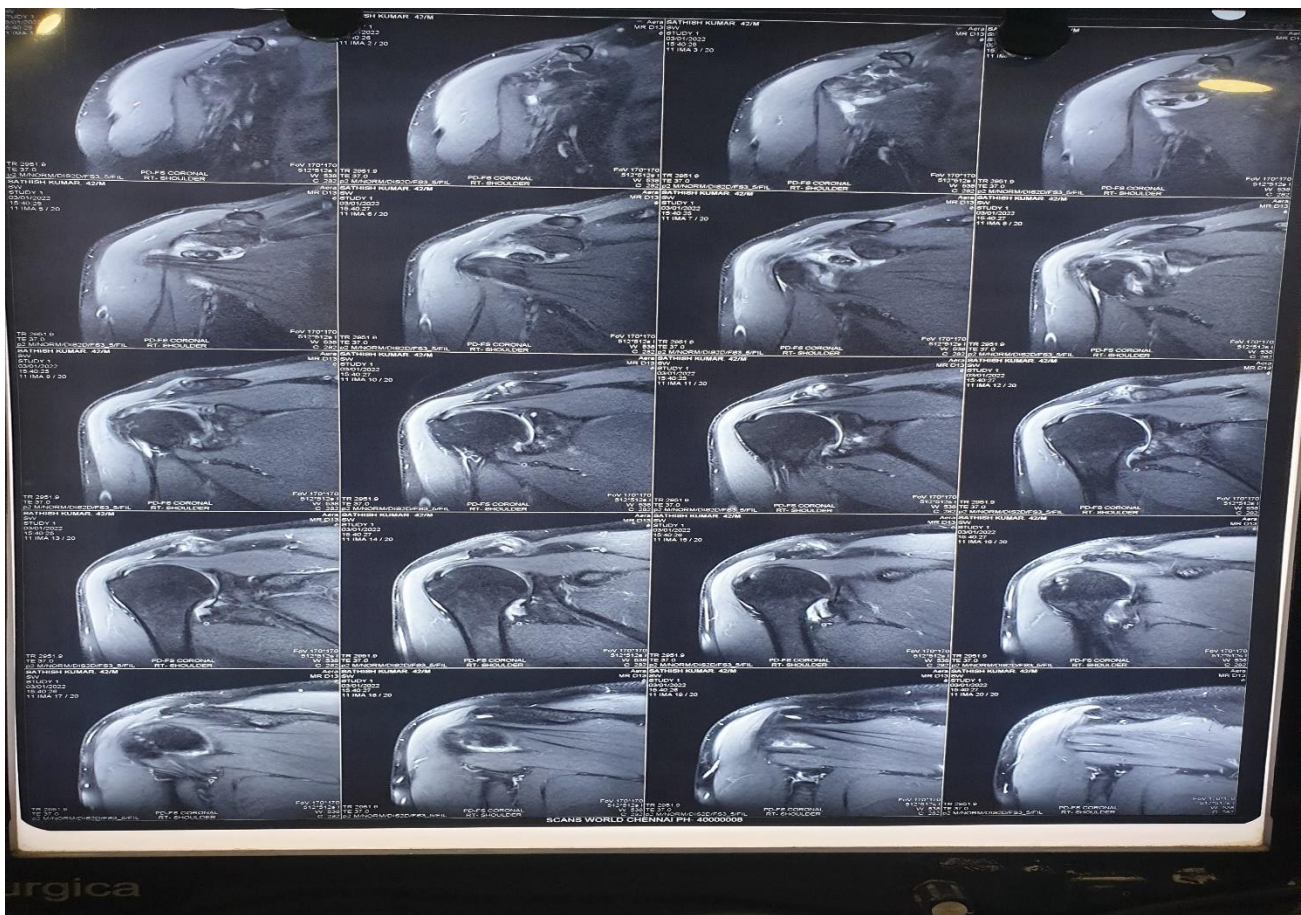
Case History

The patient had reached out the orthopaedic out-patient department with a complaint of right shoulder pain , discomfort in right shoulder region . On examination no palpable mass , no tenderness. The patient was treated with some NSAIDS , supplements and was on observation for few days. Then later he reached out to the OPD with same symptoms. So he was further advised to take MRI- right shoulder. We found the patient had acromioclavicular joint arthrosis, right shoulder antero-lateral labral cyst , anterior labral tear (BANKART LESION) , Multiple Large loose bodies. The patient was then advised for surgical management.

Surgical Management

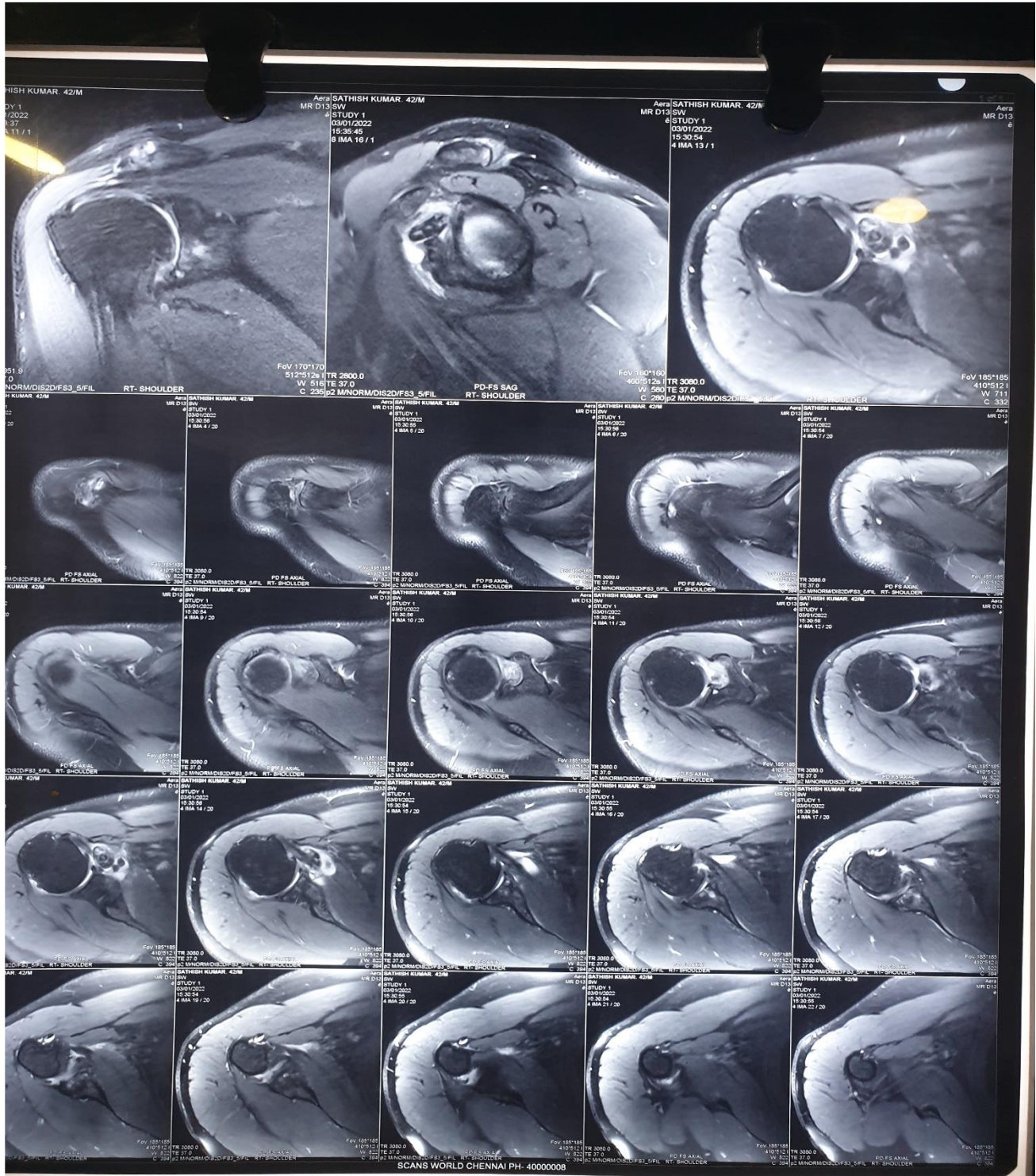
We administrated GA. The patient was then put in supine position- lateral position.

1. Right shoulder arthroscopy
 - a. Standard posterior and lateral portal.



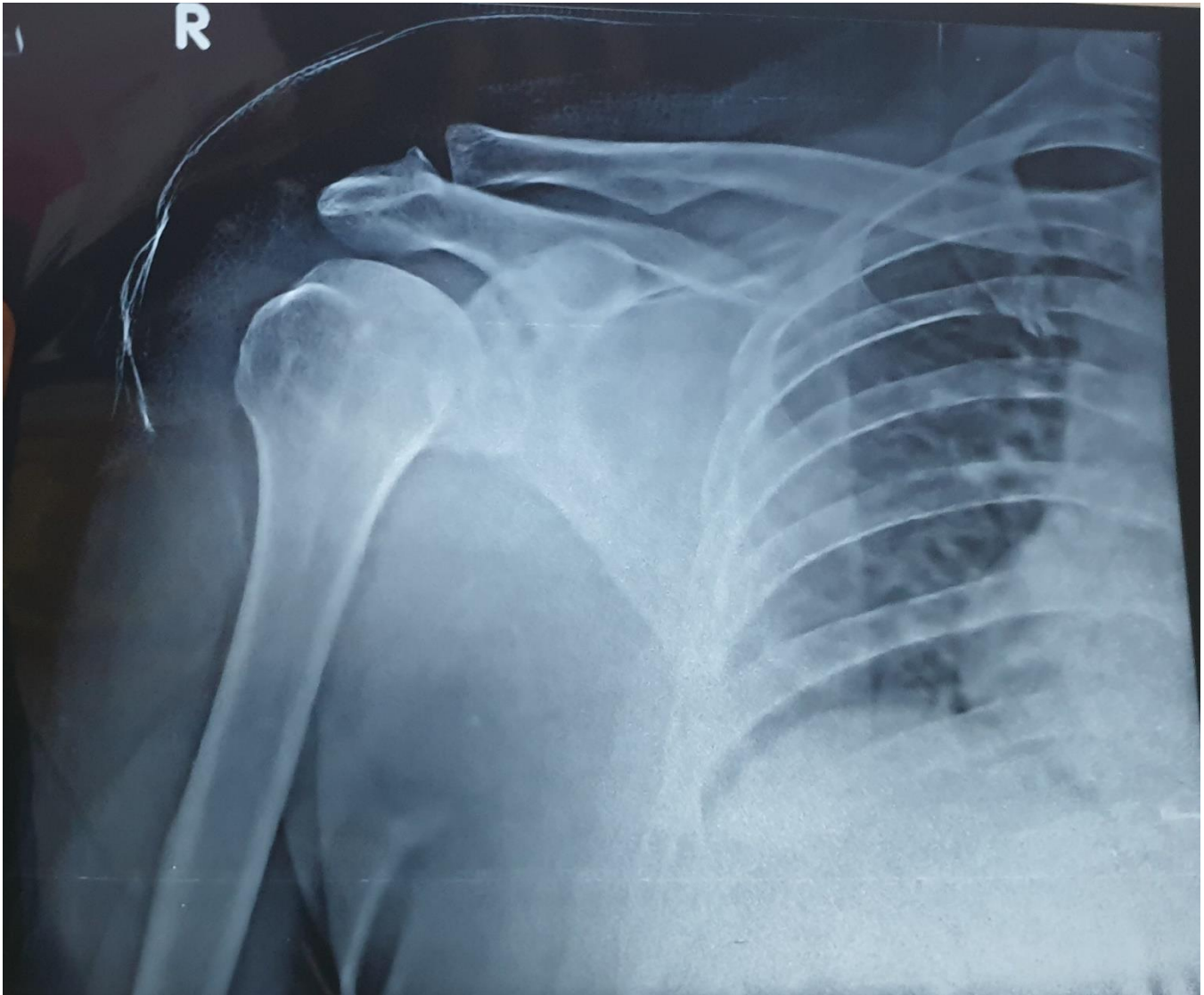
2. Decompression/excision of para-labral cyst

- a. Using arthrocare – radiofrequency probe -cyst excision done along with the anterior capsule .
- b. Thick fibrous tissue removed using shaver blade.



3. Removal of large loose bodies

a. Probed and removed the calcific loose bodies of size 4x4 cm and 3x2 cm. It was very much hard in texture and hard to remove.



4. BANKART repair using Arthrex 2.9mm bio-composite anchors

a. Using spade arthrocare probe the anterior labrum feed was done .

b. Then reattached it using fiber wire and antrex bio-composite anchors size of 2.9mm x 3mm.

WIDE BORE 48 CHANNEL 1.5 T MRI – RIGHT SHOULDER	
Sequences:	
Coronal oblique, sagittal, axial : PD fat sat	Coronal : T1W SE
Observation:	
<p>Moderate osteoarthritic change in the right shoulder with humeral osteophytes and subchondral cyst in the glenoid. Osteophytes also noted in the anteroinferior glenoid. Large loose body in the right subarachnoid bursa measuring 20 x 8 mm and two small loose bodies also noted.</p> <p>Moderate right acromioclavicular joint arthrosis.</p> <p>Tendinosis of the anterior direct tendon of supraspinatus.</p> <p>Underlying bones including the acromion and the lateral end of the clavicle appear normal with no evidence of fractures or marrow signal intensity changes identified.</p> <p>The bicipital tendon appears normal with no evidence of tear/ abnormal fluid collection seen.</p> <p>Underlying soft tissue appears normal. No significant swelling/fluid collection identified.</p>	
Impression:	
<ul style="list-style-type: none">• Moderate osteoarthritic change in the right shoulder with humeral osteophytes and subchondral cyst in the glenoid. Osteophytes in the anteroinferior glenoid. Large loose body in the right subarachnoid bursa and two small loose bodies also noted.• Moderate right acromioclavicular joint arthrosis.• Tendinosis of the anterior direct tendon of supraspinatus.	

Post-OP Management

Post-operatively, the patient was treated with I.V antibiotics, analgesics, I.V fluids, and other supportive medications. The patient had a relief of pain caused due to the compression of suprascapular nerve by the para-labral cysts.