



## **Pediatric Mid-Shaft Humerus Fracture Treated with Nancy Nails Whilst on Growth Hormone- A Case Report**

Hatim Mohammed Alshareef \*<sup>1</sup>, Wafa M. Imran <sup>2</sup>, Salwa M. Imran\*<sup>3</sup>,  
Ahmed A Elbarbary <sup>4</sup>, Dr. Ameer Sayed <sup>5</sup>

1. Orthopedic consultant, Sport medicine and arthroscopy surgery, Arthroplasty and lower limb reconstruction surgery, King Fahad armed forces hospital, Saudi Arabia.
2. Bachelor of Medicine and Bachelor of Surgery, Shandong First Medical University, China.
3. Bachelor of Medicine and Bachelor of Surgery, Xuzhou Medical University, China.
4. Orthopedic registrar, King Fahad armed forces hospital, Saudi Arabia.
5. Senior Orthopedic Registrar at King Fahad Armed Forces Hospital.

**Corresponding Author: Salwa M. Imran**, Bachelor of Medicine and Bachelor of Surgery, Xuzhou Medical University, China.

**Copy Right:** © 2023 Hatim Mohammed Alshareef, This is an open access article distributed under the Creative Commons Attribution License, which permits unrestricted use, distribution, and reproduction in any medium, provided the original work is properly cited.

**Received Date: May 02, 2023**

**Published Date: May 20, 2023**

**Abstract**

*Patients with growth hormone deficiency are more prone to fractures. There is some indication that the majority of patients with growth hormone deficiency (GHD) have decreased bone mass, which could indicate that these people are more likely to experience fractures and clinically severe osteoporosis.*

*Management of bone fractures must achieve both reduction and stability. For the treatment of mid-shaft fractures, numerous techniques have been reported. We devised a new way for treating mid-shaft fractures, we provide a case of successful Nancy nail treatment with a satisfactory functional result. This case report is about mid-shaft humerus fracture in a 12 years old, known case of GHD on a growth hormone. It is proven that GH accelerates bone healing process.*

**Keywords:** *Growth hormone, deficiency, mid-shaft humerus, fracture, Nancy nail.*

**Introduction**

The classical approach to the treatment of fractures in children paid particular attention to orthopedic treatment. Humeral shaft fractures are relatively uncommon in the paediatric population (1-3). A small number of fractures are unable to be reduced adequately or maintained in adequate alignment, and these should be treated surgically (4). Benefits of surgical stabilization include earlier mobilization, often with almost immediate mobilization (5-7). The surgical treatment of humeral shaft fractures in adults involving the use of plate and screw constructs, rigid nails, and flexible nails has been extensively studied both retrospectively and prospectively (8-11). However, the amount of information in this field available on pediatric patients is quite limited.

Operative intervention for humerus fractures has been advised because it offers greater function preservation, pain alleviation, and stability than conservative methods (12). The most effective approach for treating mid-shaft humerus fractures is still up for debate, at our institution, Nancy nails are the preferred implant for stabilizing humeral shaft fractures operatively, there are no dedicated reports in the pediatric literature describing the results of this technique and its complications.

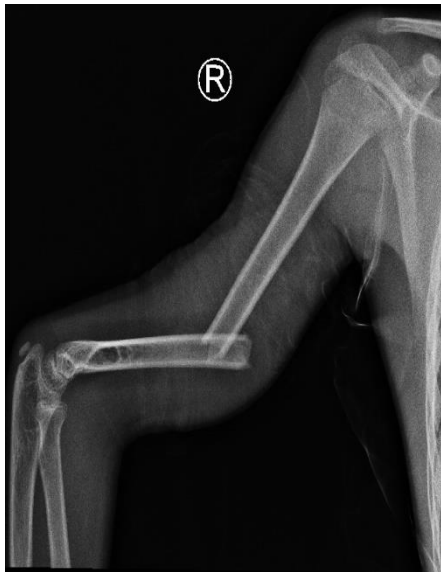Alternative, less difficult fixations may, however, be taken into consideration in settings with limited resources in the case of carefully chosen patients without compromising the functional outcome.

Growth hormones play a significant part in controlling bone remodeling. GH is required to build and sustain bone mass over the course of a lifetime (13). It is proven that growth hormones accelerate bone healing process. Animal models and in vitro research have provided proof that GH accelerates fracture healing (14, 15). Many investigations on patients with unintentional hip fractures have shown promise (16-18). Also, there is proof that GH speeds up fracture repair from research conducted in vitro and on animals (19-23). In addition to increasing bone production and resorption, GH directly increases osteoblast activity and proliferation. Increased bone remodeling occurs as a result, which leads to an overall increase in bone mass (24). Children with short stature may be helped to develop to a normal adult height with recombinant human growth hormone (GH) treatment, which encourages longitudinal growth (25) (26, 27). The use of GH in the treatment of fractures is reported in clinical research. In the majority of investigations, GH treatment dramatically boosted both bone growth and resorption (28, 29). Increased bone repair and quick clinical improvements were seen after GH treatment in patients with hip or tibial fractures (30). The anabolic effects of GH therapy are substantial. Clinical results may be significantly improved by GH administration in the treatment of bone fractures (31, 32).

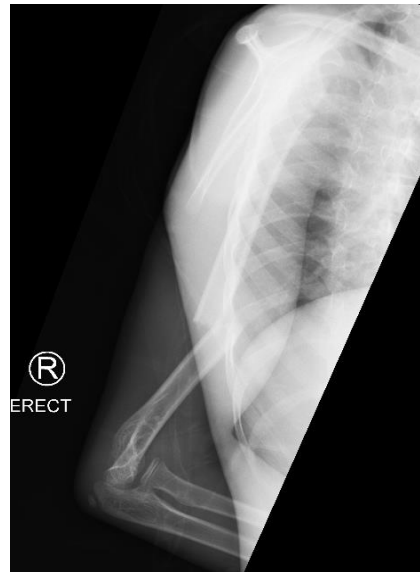### **Case presentation and investigation:**

13 years old male, known case of (GHD) on hormonal replacement, brought to emergency department in our institute (King Fahad health Armed Forces hospital) by his family after falling trauma on right shoulder while he was playing football. On examination, patient was conscious, alert and oriented to time person and place with no history of vomiting or loss of consciousness.

There was tenderness on palpation, with minimal swelling and obvious valgus deformity of the right arm. He had painful limitation of right shoulder and elbow movements with intact distal neurovascular status. Analgesics were given and arm sling was applied by ER doctors. An emergency radiograph was requested and showed displaced fracture mid-shaft right humerus.

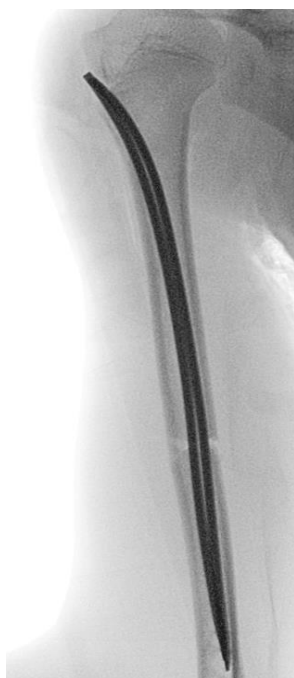

A

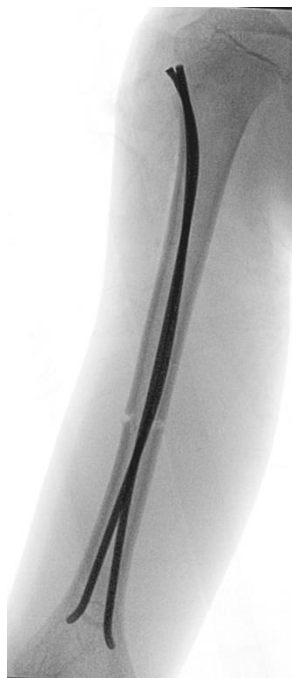

B

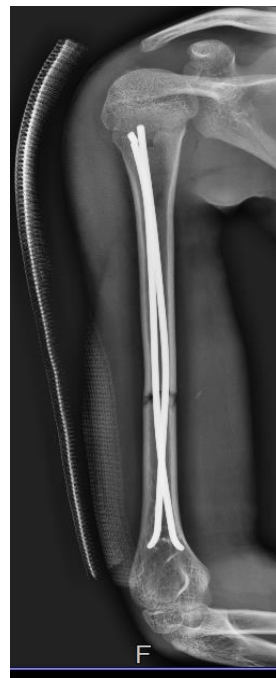**Finger 1-** A and B showed displaced fracture midshaft right humerus



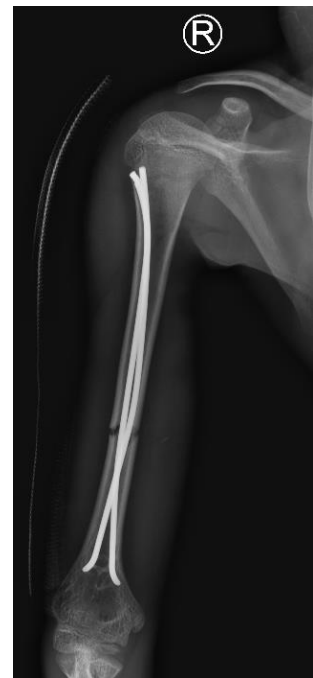A



B

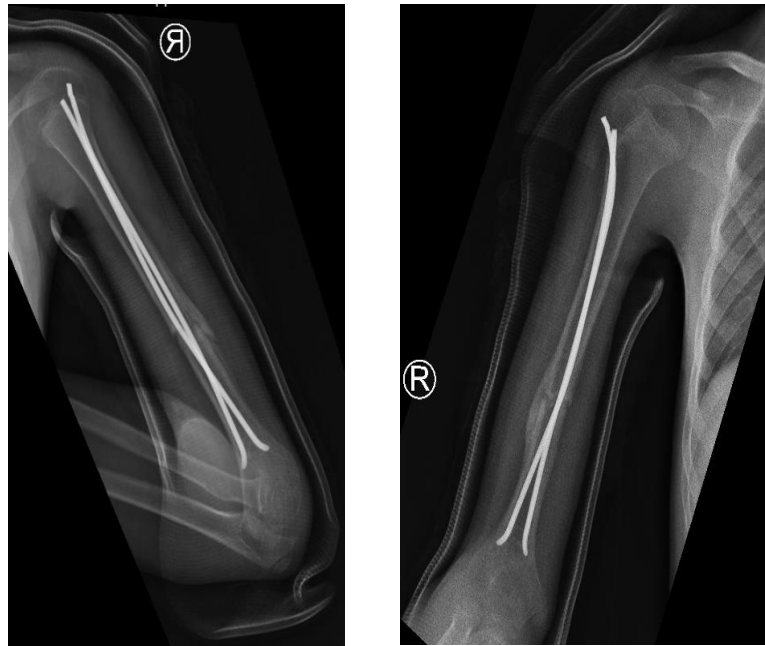


C



D

**Finger 2-** A, B, C and D showed first day post-operative close reduction and internal fixation of right humerus fracture fixated with elastic nails with accepted alignment.



A

B

**Figures 3** - A and B showed 10 weeks postoperative closed reduction and internal fixation of right humerus fractures with elastic nails healed with good callus formation.

### Discussion

Low bone density, fractures, and osteoporosis are generally thought to be caused by childhood-onset growth hormone deficiency (GHD) (33). Hence, bone health in prepubertal children with GH deficiency should be routinely evaluated (34).

The role of growth hormone (GH) in augmenting fracture healing has been postulated for over half a century. It has been demonstrated that GH influences bone metabolism, either directly or through IGF-I. A literature review on GH and its impact on bone fracture healing was conducted. The most recent research points to a beneficial effect of GH on osteoblasts, osteoclasts, and the interaction between the two during fracture repair. Prior to establishing GH's widespread usage as a fracture-healing agent, the ideal dose and mode of administration must still be discovered, and the safety profile of this unique use of GH must be examined (34).

The optimum course of treatment for mid-shaft humerus fractures should be decided on an individual basis, according to the ideal surgical management. In the past, reduction and splinting have been the standard treatments for midshaft humerus fractures (35-37).

Flexible intramedullary nailing has been linked in studies to a quicker healing process and shorter intraoperative time. Presenting this nail just needs a few little incisions. Moreover, the postoperative period of immobilization related to the use of this nail is shorter (38). This key point is a considerable benefit in facing postoperative challenges. One study have reported that flexible intramedullary nailing reduces infection risk and promotes bone healing while being inserted in a closed technique (39).

Our technique is antegrade insertion of elastic nail, a longitudinal incision is made over the proximal humerus at the level of the greater tuberosity, and dissection is taken down sharply to the humeral metaphysis distal to the physis. The rotator cuff is incised in line with the fibers. Image intensification is used to confirm the starting point. The cortex is entered using a 3.2- or 4.5-mm drill bit and the opening subsequently enlarged using a clamp. A single flexible nail is inserted into the bone and passed into the distal fracture fragment as far as possible into the supracondylar area. The procedure is repeated to add a second implant. A small portion of the nail is left out of the cortex proximally to facilitate removal. Closure is routine with the rotator cuff closed using absorbable suture.

## **Conclusions**

Fractures are more likely to occur in patients who have GHD. Although this successful case of Nancy nail fixation is not sufficient to challenge the option of conservative methods, this low cost, readily, available simple strategy may be useful in highly selective instances. Nancy nail was effectively used in this case, and the overall management led to good outcomes. It is proven that GH accelerates bone healing process.

## **Management**

Patient admitted and underwent closed reduction and internal fixation with elastic nail. Postoperatively, patient was doing fine, his pain level was controlled with intact neurovascular status and the patient was discharged to home with oral analgesics. In our orthopedic clinic patient was following every 2 weeks and his surgical wound was healed completely with no sign of infection or discharge. 10 weeks later fracture healed completely with good callus formation and good range of right shoulder and elbow movement. Patient was referred to physical therapy to start range of motion exercises and strengthening exercises for periscapular muscle.

## References

1. Rennie L, Court-Brown CM, Mok JY, Beattie TF. The epidemiology of fractures in children. *Injury*. 2007;38(8):913-22.
2. Caviglia H, Garrido CP, Palazzi FF, Meana NV. Pediatric fractures of the humerus. *Clin Orthop Relat Res*. 2005(432):49-56.
3. Cheng JC, Shen WY. Limb fracture pattern in different pediatric age groups: a study of 3,350 children. *J Orthop Trauma*. 1993;7(1):15-22.
4. Chapman JR, Henley MB, Agel J, Benca PJ. Randomized prospective study of humeral shaft fracture fixation: intramedullary nails versus plates. *J Orthop Trauma*. 2000;14(3):162-6.
5. Sénès FM, Catena N. Intramedullary osteosynthesis for metaphyseal and diaphyseal humeral fractures in developmental age. *J Pediatr Orthop B*. 2012;21(4):300-4.
6. Chitgopkar SD. Flexible nailing of fractures in children using stainless steel Kirschner wires. *J Pediatr Orthop B*. 2008;17(5):251-5.
7. Garg S, Dobbs MB, Schoenecker PL, Luhmann SJ, Gordon JE. Surgical treatment of traumatic pediatric humeral diaphyseal fractures with titanium elastic nails. *J Child Orthop*. 2009;3(2):121-7.
8. Webb L, Green N, Swiontkowski M. *Skeletal trauma in children*. Philadelphia WB Saunders; 1993.
9. Brumback RJ, Bosse MJ, Poka A, Burgess AR. Intramedullary stabilization of humeral shaft fractures in patients with multiple trauma. *J Bone Joint Surg Am*. 1986;68(7):960-70.
10. Stannard JP, Harris HW, McGwin G, Jr., Volgas DA, Alonso JE. Intramedullary nailing of humeral shaft fractures with a locking flexible nail. *J Bone Joint Surg Am*. 2003;85(11):2103-10.
11. Zatti G, Teli M, Ferrario A, Cherubino P. Treatment of closed humeral shaft fractures with intramedullary elastic nails. *J Trauma*. 1998;45(6):1046-50.
12. Hohloch L, Eberbach H, Wagner FC, Strohm PC, Reising K, Südkamp NP, et al. Age- and severity-adjusted treatment of proximal humerus fractures in children and adolescents-A systematical review and meta-analysis. *PLoS One*. 2017;12(8):e0183157.
13. Ohlsson C, Bengtsson BA, Isaksson OG, Andreassen TT, Słotweg MC. Growth hormone and bone. *Endocr Rev*. 1998;19(1):55-79.

14. Raschke M, Rasmussen MH, Govender S, Segal D, Suntum M, Christiansen JS. Effects of growth hormone in patients with tibial fracture: a randomised, double-blind, placebo-controlled clinical trial. *Eur J Endocrinol.* 2007;156(3):341-51.
15. Santos F, Fuente R, Mejia N, Mantecon L, Gil-Peña H, Ordoñez FA. Hypophosphatemia and growth. *Pediatr Nephrol.* 2013;28(4):595-603.
16. *European Journal of Endocrinology.* 2000. p. 585.
17. *Clinical Endocrinology.* 2003. p. 99.
18. *Growth Hormone and IGF Research.* 2003. p. 361.
19. *Bone.* 2001. p. 368.
20. *Bone.* 2002. p. 117.
21. *Calcified Tissue International.* 2003. p. 258.
22. Chaves LH, Giovanini AF, Zielak JC, Scariot R, Gonzaga CC, Storrer CLM, et al. Growth hormone effects on healing efficacy, bone resorption and renal morphology of rats: histological and histometric study in rat calvaria. *Heliyon.* 2020;6(10):e05226.
23. Mann FA, Payne JT. Bone healing. *Semin Vet Med Surg Small Anim.* 1989;4(4):312-21.
24. Olney RC. Regulation of bone mass by growth hormone. *Med Pediatr Oncol.* 2003;41(3):228-34.
25. Drube J, Wan M, Bonthuis M, Wühl E, Bacchetta J, Santos F, et al. Clinical practice recommendations for growth hormone treatment in children with chronic kidney disease. *Nat Rev Nephrol.* 2019;15(9):577-89.
26. Al Shaikh A, Daftardar H, Alghamdi AA, Jamjoom M, Awidah S, Ahmed ME, et al. Effect of growth hormone treatment on children with idiopathic short stature (ISS), idiopathic growth hormone deficiency (IGHD), small for gestational age (SGA) and Turner syndrome (TS) in a tertiary care center. *Acta Biomed.* 2020;91(1):29-40.
27. Tritos NA, Klibanski A. Effects of Growth Hormone on Bone. *Prog Mol Biol Transl Sci.* 2016;138:193-211.
28. Ahmed SF, Farquharson C. The effect of GH and IGF1 on linear growth and skeletal development and their modulation by SOCS proteins. *J Endocrinol.* 2010;206(3):249-59.

29. Dioufa N, Schally AV, Chatzistamou I, Moustou E, Block NL, Owens GK, et al. Acceleration of wound healing by growth hormone-releasing hormone and its agonists. *Proc Natl Acad Sci U S A*. 2010;107(43):18611-5.
30. Bancos I, Algeciras-Schimmich A, Woodmansee WW, Cullinane AK, Donato LJ, Nippoldt TB, et al. Determination of nadir growth hormone concentration cutoff in patients with acromegaly. *Endocr Pract*. 2013;19(6):937-45.
31. Locatelli V, Bianchi VE. Effect of GH/IGF-1 on Bone Metabolism and Osteoporosis. *Int J Endocrinol*. 2014;2014:235060.
32. Åberg D. Role of the growth hormone/insulin-like growth factor 1 axis in neurogenesis. *Endocr Dev*. 2010;17:63-76.
33. Högler W, Shaw N. Childhood growth hormone deficiency, bone density, structures and fractures: scrutinizing the evidence. *Clin Endocrinol (Oxf)*. 2010;72(3):281-9.
34. Baer TG, Agarwal S, Chen S, Chiuзан C, Sopher AB, Tao R, et al. Deficits in Bone Geometry in Growth Hormone-Deficient Prepubertal Boys Revealed by High-Resolution Peripheral Quantitative Computed Tomography. *Horm Res Paediatr*. 2019;92(5):293-301.
35. Nowak LL, Dehghan N, McKee MD, Schemitsch EH. Plate fixation for management of humerus fractures. *Injury*. 2018;49 Suppl 1:S33-s8.
36. Grechenig S, Hohenberger G, Bakota B, Staresinic M, Grechenig P, Ernstberger A. Humeral shaft cerclage wiring: a safe technique to prevent radial nerve injury. *Injury*. 2017;48 Suppl 5:S12-s4.
37. Rocchi M, Tarallo L, Mugnai R, Adani R. Humerus shaft fracture complicated by radial nerve palsy: Is surgical exploration necessary? *Musculoskelet Surg*. 2016;100(Suppl 1):53-60.
38. Samara E, Tschopp B, Kwiatkowski B, Vardar E, Lutz N, Zambelli PY. A Single Retrograde Intramedullary Nail Technique for Treatment of Displaced Proximal Humeral Fractures in Children: Case Series and Review of the Literature. *JB JS Open Access*. 2021;6(1).
39. Lascombes P, Haumont T, Journeau P. Use and abuse of flexible intramedullary nailing in children and adolescents. *J Pediatr Orthop*. 2006;26(6):827-34.