

Research Article

Metaplastic Carcinoma of the Breast: A Rare Neoplasm with Prominent Osseous Differentiation

Parul Sobti*, Rajinder Kaur Saggu

1. Rajinder Kaur Saggu, Department of Surgical Oncology, Consultant Indraprastha Apollo Hospitals, Sarita Vihar, New Delhi, India.

***Corresponding Author: Parul Sobti**, Department of Pathology, Consultant Indraprastha Apollo Hospitals, Sarita Vihar, New Delhi, India.

Received Date: March 20, 2021

Publication Date: April 01, 2021

Introduction

Metaplastic breast cancer (MBC) is a rare malignancy characterized by the histologic presence of two or more cellular types, commonly a mixture of epithelial and mesenchymal components (1, 6). MBC represents 0.25–1% of breast cancers diagnosed annually (1, 7, 8). Due to its relative rarity and heterogeneous histologic presentation, the pathologic diagnosis of MBC is difficult. The World Health Organization (WHO) recognized MBC as a unique pathologic entity in 2000. Since then, the incidence of MBC has risen, likely representing an increased recognition by pathologists (8, 9). Overall, greater than 70% of patients with MBC present with the American Joint Committee on Cancer (AJCC) stage II or greater disease as compared to approximately 50% of patients with IDC (8).

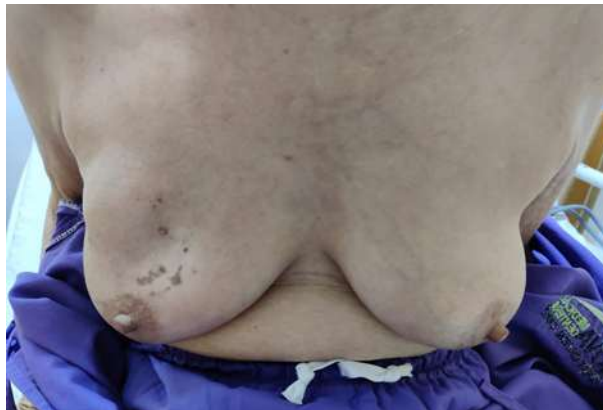Compared to patients with IDC, those with MBC have worse outcomes with 5-year survival rates ranging from 49% to 68% (1, 10, 11). The optimal treatment strategies for MBC are unknown. Management of MBC has largely paralleled that of IDC, despite growing evidence that MBC is a distinct entity that lies along the spectrum of basal-like breast cancers. This case report is presented for its diverse morphological features including different patterns of differentiation such as prominent osseous, squamous cell, spindle cell, myxoid, and invasive duct carcinoma.

Case Report

An elderly lady aged 72 years old recently noticed a lump in her right breast. No significant past medical history. She had no history of breast cancer in her first-degree relative.

The initial physical examination revealed a hard lump measuring 6 x 5 cm in the upper outer quadrant of the right breast, with tethering to overlying skin, the mass was well defined and not fixed to the skin and chest wall, there was no nipple retraction & a small mobile right axillary lymph node was palpable.

(Fig. 1). The left breast and axilla were normal.



General and systemic examination of the patient including Metastatic work up with Whole-body PET CT scan were normal. Core Biopsy was done and reported as a High-Grade Mesenchymal tumor, Triple negative. A clinical and pathological diagnosis of a High-grade Mesenchymal tumor was made following which the patient underwent Modified Radical Mastectomy, Level I and II axillary clearance done, tumor was infiltrating underlying muscle, so Pectoralis muscle was excised and the specimen was subjected for histopathological examination. The procedure was performed by the author and his team. The post-operative period was uneventful. Final HPE revealed the same. The patient was later sent for adjuvant chemotherapy and radiotherapy.

Gross and Microscopic Findings

Gross Description: A Right modified radical mastectomy specimen was received. The tumor was seen in the upper outer and is nodular, grey-white, and measures 5.8 cm superoinferiorly, 3.6 cm is anteroposteriorly and 5.5 cm mediolaterally. Cut surface of the tumor is grey-white, firm with infiltrating margins. Separately lying axillary fat measures 8x6.5x5 cm.



Microscopic Examination

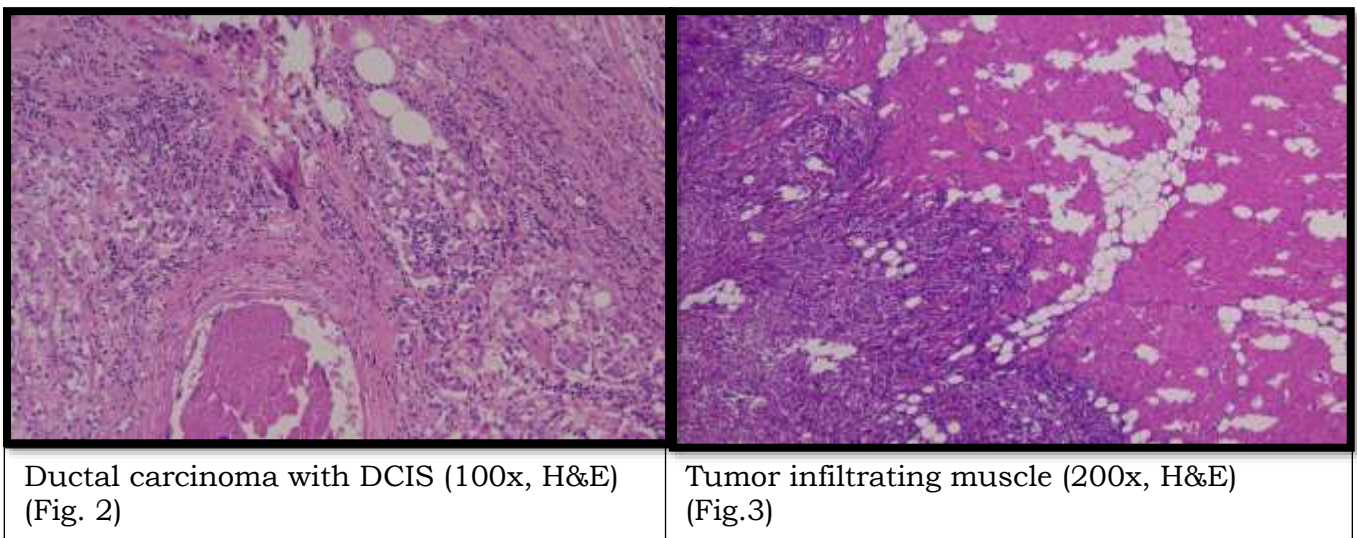
Sections of breast tissue show tumor infiltration. The tumor is consisting primarily of Mesenchymal areas in 90 to 95% area and these are composed of cells that are spindle-shaped to polygonal and show a moderate amount of eosinophilic cytoplasm, round hyperchromatic nuclei with moderate to marked nuclear pleomorphism, and frequent mitosis (up to 2 to 3 per high power field). Intermingled within the tumor cells are areas of osteoid consisting of ropy hyaline eosinophilic appearing material.

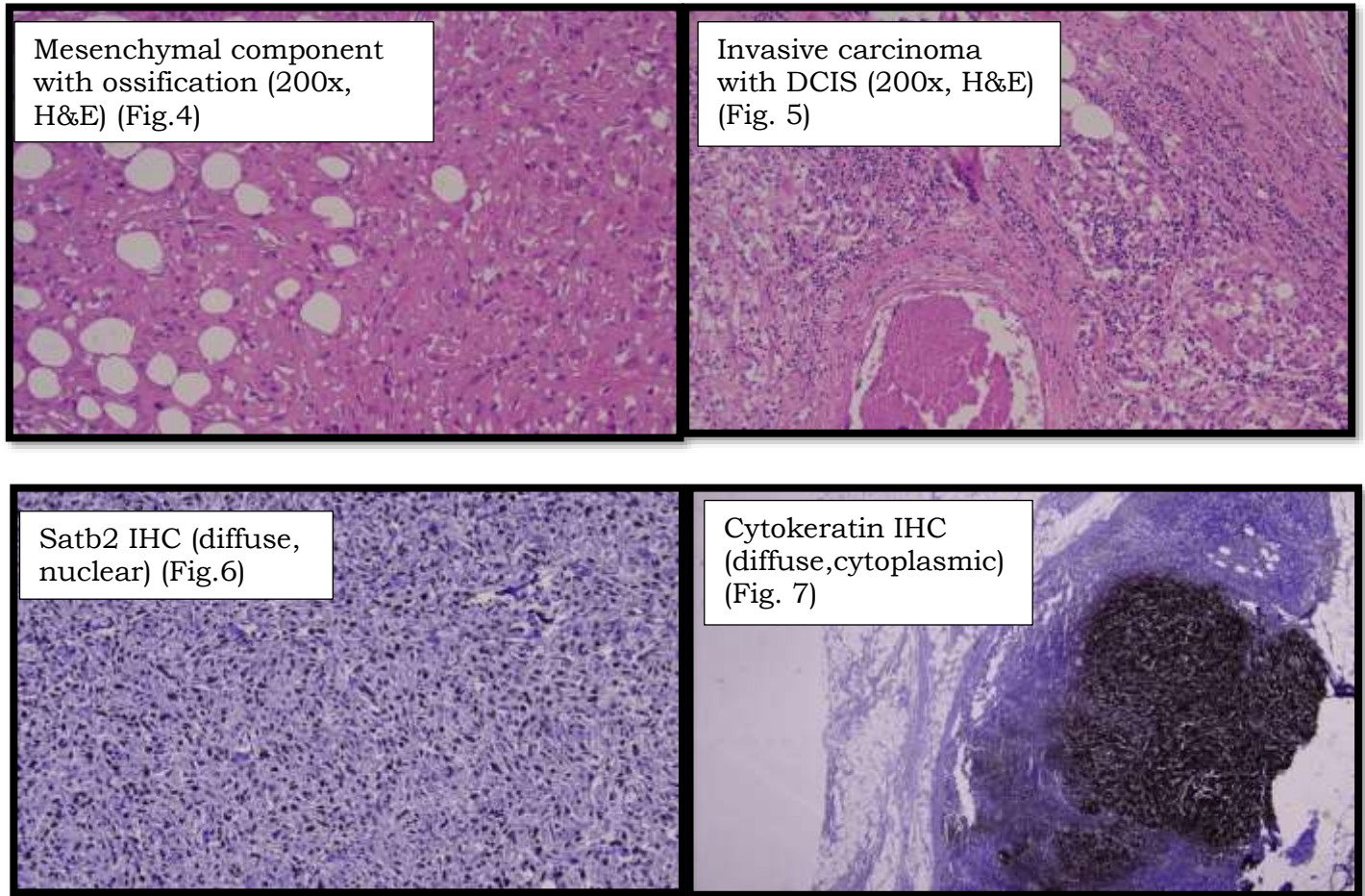
Areas of necrosis are seen in approximately 5 to 10% area. Also noted in 5 to 10% area, there are closely intermingled areas of Invasive ductal carcinoma, grade 2, composed of cells arranged in nests, islands, and forming tubules at places. The tumor cells are polygonal with a moderate amount of eosinophilic cytoplasm, round nuclei, regular nuclear outlines, and frequent mitosis (up to 8 to 10 per high power fields). Intermingled areas of DCIS are seen of the solid, comedo, and cribriform type of intermediate nuclear grade. The tumor was infiltrating the muscle, extra muscle margin sent was free from the tumor. Eighteen lymph nodes are identified one of which shows evidence of nodal metastasis. The size of largest involved lymph node is 12 mm.

Immunohistochemistry

On immunohistochemistry, the mesenchymal areas show expression of Vimentin and SatB2. Myogenin was negative. Ki67 is up to 60 to 65% in hot spots.

On immunohistochemistry in carcinoma areas: CKAE1/3-Positive (diffuse, cytoplasmic). Ki67 is up to 10 to 15% in hot spots.





Discussion

Metaplastic breast carcinoma (MBC) is a heterogeneous group of neoplasm which is characterized by a closely related mixture of ductal carcinoma with areas of squamous, spindle, osseous and chondroid differentiation (12). Osseous differentiation is a very rare subtype of MBC (14). Because of the rarity of the condition, clinical and pathological characteristics are not fully understood (13). Osseous and chondroid differentiation may occur focally in 0.2% of carcinoma of the breast, while osseous metaplasia is the rarest subtype (14). Still, there is controversy regarding the classification of MBC (13) Some authors divide the disease is into two main subgroups: (1) heterogeneous carcinosarcoma associated with sarcomatous differentiation (chondroid, osseous, and rhabdoid) (15). (2) Primary osteosarcoma.

Primary osteosarcoma should be diagnosed only after metaplastic mammary carcinoma is ruled out. However, metaplastic carcinoma shows an epithelial differentiation. Therefore, it is essential to examine



a large number of tumor tissue blocks and if need be completely sample the entire tumor, also using immunohistochemistry to exclude an associated ductal carcinoma. This has an important impact on treatment and further prognosis. SATB2 is a nuclear protein that plays a critical role in osteoblast lineage commitment. It is involved in vertebrate skeletogenesis via repression of the HOXA2 gene (inhibitor of bone formation and regulator of branchial arch patterning). In this case a novel immunohistochemistry marker, SATB2 was used for diagnosis.

MBC is different from typical adenocarcinomas in several aspects. It less commonly affects lymph nodes with an incidence ranging from 6 to 26% while more commonly develops metastatic disease (13). The rate of recurrence for node-negative invasive ductal carcinoma has ranged from 17% to 20% within 2–5 years of diagnosis. This compares with a recurrence rate of 35–62% for MBC within the same period (18). Bellino and associates advised surgery and adjuvant chemotherapy to be performed according to the recommendations for most other breast carcinoma (18).

References

- 1.H. A. Oberman, “Metaplastic carcinoma of the breast. A clinicopathologic study of 29 patients,” *American Journal of Surgical Pathology*, vol. 11, no. 12, pp. 918–929, 1987.
- 2.E. S. Wargotz and H. J. Norris, “Metaplastic carcinomas of the breast. I. Matrix-producing carcinoma,” *Human Pathology*, vol. 20, no. 7, pp. 628–635, 1989.
- 3.E. S. Wargotz, P. H. Deos, and H. J. Norris, “Metaplastic carcinomas of the breast. II. Spindle cell carcinoma,” *Human Pathology*, vol. 20, no. 8, pp. 732–740, 1989.
- 4.E. S. Wargotz and H. J. Norris, “Metaplastic carcinomas of the breast. III. Carcinosarcoma,” *Cancer*, vol. 64, no. 7, pp. 1490–1499, 1989.
View at: [Google Scholar](#)
- 5.E. S. Wargotz and H. J. Norris, “Metaplastic carcinomas of the breast. IV. Squamous cell carcinoma of ductal origin,” *Cancer*, vol. 65, no. 2, pp. 272–276, 1990.
View at: [Publisher Site](#) | [Google Scholar](#).
- 6.E. S. Wargotz and H. J. Norris, “Metaplastic carcinomas of the breast: V. Metaplastic carcinoma with osteoclastic giant cells,” *Human Pathology*, vol. 21, no. 11, pp. 1142–1150, 1990.



- 7.F. A. Tavassoli, "Classification of metaplastic carcinomas of the breast," *Pathology Annual*, vol. 27, part 2, pp. 89–119, 1992.
View at: [Google Scholar](#)
8. C. M. Pezzi, L. Patel-Parekh, K. Cole, J. Franko, V. S. Klimberg, and K. Bland, "Characteristics and treatment of metaplastic breast cancer: analysis of 892 cases from the national cancer data base," *Annals of Surgical Oncology*, vol. 14, no. 1, pp. 166–173, 2007.
View at: [Publisher Site](#) | [Google Scholar](#)
- 9.P. J. Barnes, R. Boutilier, D. Chiasson, and D. Rayson, "Metaplastic breast carcinoma: clinical-pathologic characteristics and HER2/neu expression," *Breast Cancer Research and Treatment*, vol. 91, no. 2, pp. 173–178, 2005.
View at: [Publisher Site](#) | [Google Scholar](#)
- 10.A. Luini, M. Aguilar, G. Gatti et al., "Metaplastic carcinoma of the breast, an unusual disease with worse prognosis: the experience of the European Institute of Oncology and review of the literature," *Breast Cancer Research and Treatment*, vol. 101, no. 3, pp. 349–353, 2007.
View at: [Publisher Site](#) | [Google Scholar](#)
- 11.D. Rayson, A. A. Adjei, V. J. Suman, L. E. Wold, and J. N. Ingle, "Metaplastic breast cancer: prognosis and response to systemic therapy," *Annals of Oncology*, vol. 10, no. 4, pp. 413–419, 1999.
12. Lang Ronggang, Fan Yu, Fu Xilin, Fu Li. "Metaplastic breast carcinoma with extensive osseous differentiation: a report of two cases and review of the literature". *Tumori*. 2011;97(1):1
13. Barnes P.J., Boutilier R., Chiasson D., Rayson D." Metaplastic breast carcinoma: clinical-pathologic characteristics and HER2/neu expression". *Breast Cancer Res. Treat.* 2005;91:173–178.
14. Pollock J.M., Green A., Donnell C., Dyess D.L., Tucker J.A. "Metaplastic breast carcinoma with osseous differentiation: a case report. South". *Med. J.* 2006;99:168–170.
15. Tavassoli F.A. "Classification of metaplastic carcinomas of the breast". *Pathol. Annu.* 1992;27(1):89–119.Pt. 2.



16. Erguvan-Dogan B., Yazgan C., Atasoy C., Sak S.D., Tukul S., Ceyhan K. “Radiologic-pathologic (conference) of the University of Ankara Medical School”. Metaplastic breast carcinoma with osteochondrosarcomatous differentiation. Am. J. Roentgenol. 2005;185(1):1593–1594.
17. Kijima Y., Umekita Y., Yoshinaka H., Owaki T., Sakamoto A., Yoshida H. “A case of breast carcinoma with cartilaginous and osseous metaplasia”. Breast Cancer. 2006;13:214–219.
18. Carter C.L., Allen C., Henson D.E. “Relation of tumor size, lymph node status and survival in 24,740 breast cancer cases”. Cancer. 1989;63(1):181–187.

Volume 1 Issue 3 April 2021

©All rights reserved by Parul Sobti