

Case Report

Spinal Cord Compression in Breast Cancer with Occult Bone Metastasis

Dr. Mohammed Abdul Naseer

***Corresponding Author: Dr. Mohammed Abdul Naseer.** Department of Oncology, Salmaniya Medical Complex, Bahrain.

Received Date: March 27, 2021

Publication Date: April 06, 2021

Abstract

Epidural spinal cord compression occurs in solid tumors due to preexisting bone metastasis. The most common tumors are from breast, lung, and prostate in origin which are more prone to the development of bone metastasis. Spinal cord compression occurs in these patients as a result of the progression of bone metastasis. We present a rare case of locally advanced breast cancer in a young Bahraini female who had recently married and had completed her primary treatment including surgery, chemotherapy, and radiotherapy. She did not continue on adjuvant hormonal treatment although indicated, for want of pregnancy. During follow up she had developed persistent back pain of 3 months duration which was controlled with analgesics.

She was not investigated further as her plain X-ray lumbosacral spine, and alkaline phosphatase were within normal limits. She was admitted with features of acute spinal cord compression and an urgent MRI spine confirmed the presence of epidural spinal cord compression. She had decompression surgery followed by postoperative radiotherapy and on adjuvant hormonal treatment with ovarian function suppression. She had recovered all her neurological deficits and was fully ambulatory with the intensive physiotherapy which she had during and following her treatment for 2-3 months.

Following treatment, scans showed neither the evidence of local recurrence nor the distant metastasis including the bone. She remained disease-free for 9 months and her occult bone disease was evident in follow-up investigations including bone scan & CT scan. We attribute her failure to treatment due to non-compliance with the planned treatment. Currently, she is symptomatic and on an II-line of hormonal treatment plus CD 4/6 inhibitors along with ovarian suppression and Denosumab. In this case report, we stress an early MRI spine irrespective of neurological status if there is a history of back pain persisting for >3weeks to detect an early cord compression.

Keywords: Breast cancer, Spinal cord compression, Decompression surgery, External radiotherapy, Hormonal treatment, Physiotherapy.



Introduction

Spinal cord compression is an oncologic emergency wherein the clinician has to act rapidly in establishing the diagnosis and treatment in cooperation with other team members to achieve a good outcome & best quality of life (1). Most commonly spinal cord compression occurs in solid tumors (> 90%) due to bone metastasis (1,9,10). The earliest symptom of spinal cord compression is back pain which usually precedes around 2 months before the actual presentation of cord compression (1,9,10). Hence the physician concerned and patient in particular with bone metastasis should be educated well in advance to report as early as possible with clinical symptoms of spinal cord compression such as band-like or radiating back pain, numbness, or motor weakness. Bladder & bowel involvement in the form of urinary retention or constipation is the late manifestation due to involvement of the autonomic nervous system (11). Once the spinal cord compression is suspected clinically, MRI of the whole spine or at least an MRI of the dorsal-lumbosacral spine has to be arranged within 24 hours of the presentation as the majority of compression > 90% occurs in this area (1,10).

The cervical spine is the source only in <10 percent of patients. If an MRI facility is not available, then contrast-enhanced CT myelography should be arranged. Steroids have to be started as bridge therapy once the spinal cord is suspected in a known tumor. Primary treatment of spinal cord compression depends on the patient's performance status, neurological status & its duration, histological type, spinal instability, and a number of levels of cord compression (8). Decompression surgery followed by postoperative external beam radiotherapy gives the best result (1,10). Systemic treatment is indicated in chemo-sensitive & hormonal sensitive tumors after the local treatment.

Case Report

Mrs. X was 30 years old premenopausal in March 2015 at the time of diagnosis with locally advanced right breast cancer. She had recently married with a family history of many cancers. She felt a self-detected painless breast lump in her right breast in July 2014 and neglected it. She sought medical advice in March 2015 when her lump increased in size with associated pain. Staging workup showed T2N2M0 cancer of the right breast. True cut biopsy from the right breast lesion showed features of grade II infiltrating ductal carcinoma with both ER & PR positive & Her2 negative by FISH technique with Ki 67 around 40%. She had 4 cycles of neoadjuvant chemotherapy (EC regimen) followed by 3 cycles of Docetaxel chemotherapy with good partial response. She underwent right mastectomy plus axillary lymph node dissection on 7th March 2016. Pathology showed (ypT1ypN1M0) grade II ductal cancer in the lower inner quadrant measuring 5 mm in size with all surgical margins clear of malignancy in excess of >1 cm. Lymph vascular invasion was present. There were multiple foci of residual disease. One out of

thirteen axillary lymph nodes were involved. Both ER & PR were positive & Her 2 receptors were negative. This was followed by postoperative external beam radiotherapy to the right chest wall plus ipsilateral clavicular area using gated VMAT technique to a total dose of 50 Gy in 25 fractions between 25th April 2016 to 29th May 2016. She discontinued adjuvant Tamoxifen after 3 months of administration as she was keen to get pregnant.

She was under regular follow-up with no evidence of disease. She started to complain of backache in March 2019 and a neurological examination showed no abnormality. Her alkaline phosphatase and tumor marker Ca 15.3 were within normal limits. She used to get analgesics for relief of back pain at her local health center. X-ray lumbosacral -lumbar spine showed no abnormality. She was admitted to SMC on 20th May 2019 with features of acute cord compression with a one-day history of inability to walk. She had girdle pain radiating to the front of the abdomen. She had weakness of both the lower limbs associated with numbness. She had urinary incontinence & constipation as well. Clinical examination showed local tenderness over the dorsal spine around D10 with the sensory deficit at the D7 level. She had normal power in both the upper limbs (5/5) but the power in the right lower limbs was grade 2/5 & grade 2/5 in the left lower limb.

The knee jerk was exaggerated with a positive Babinski's sign. Power in both lower limbs improved to grade 3/5 after steroids. Urgent MRI spine was done on May 21, 2019, showed evidence of metastatic disease involving D7 & D8 with the epidural spread between D5-D10 with significant spinal cord compression at the corresponding levels “(shown in Fig. 1,2)”.

Fig (1): MRI Axial Image of Patient Showing Epidural Cord Compression

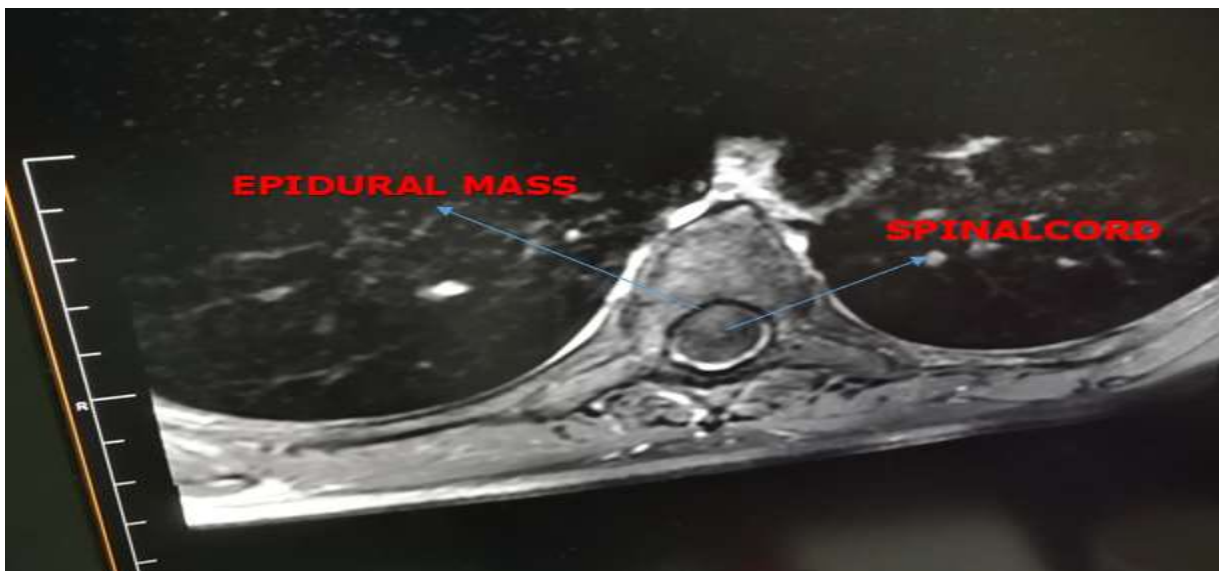
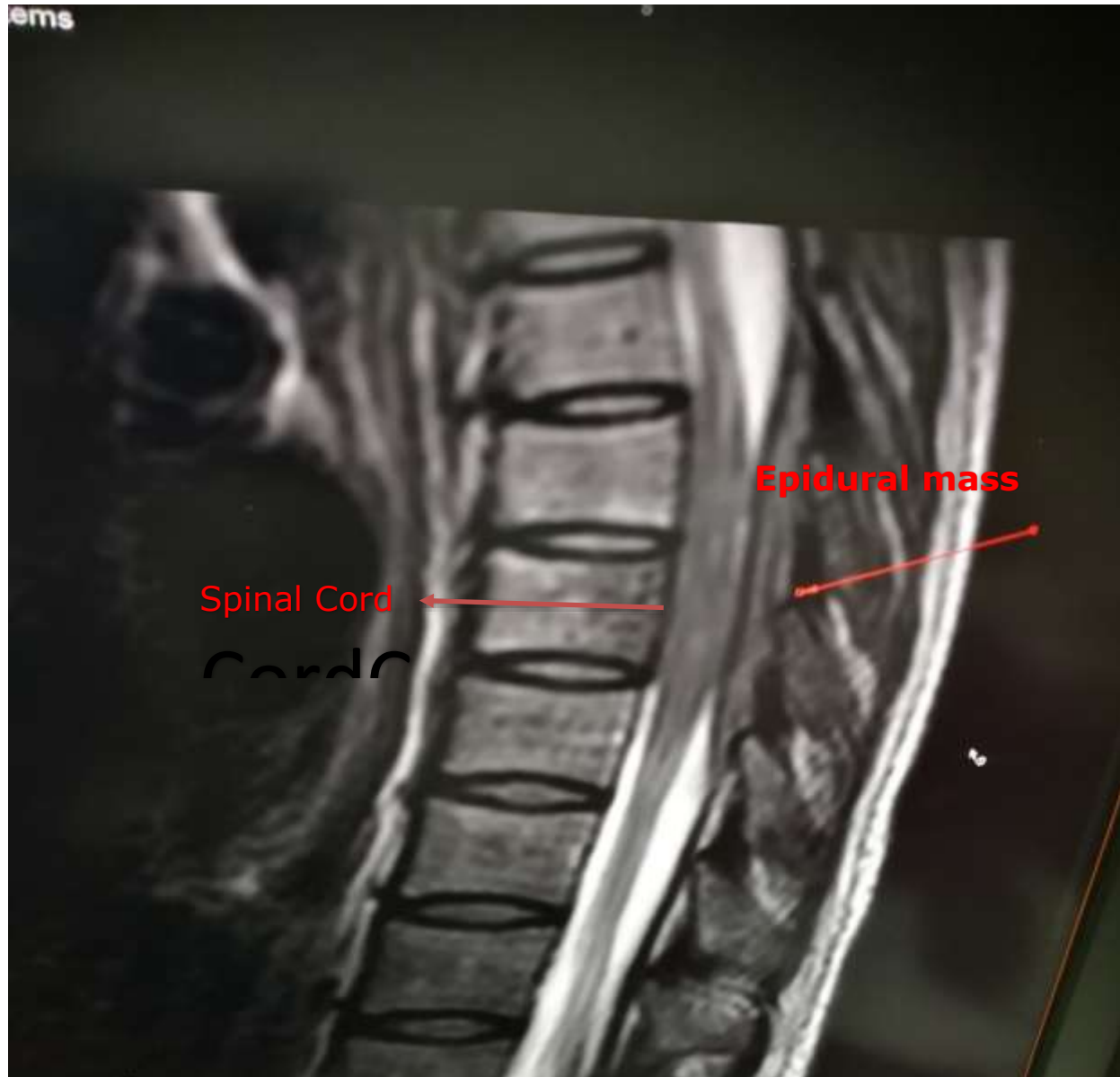


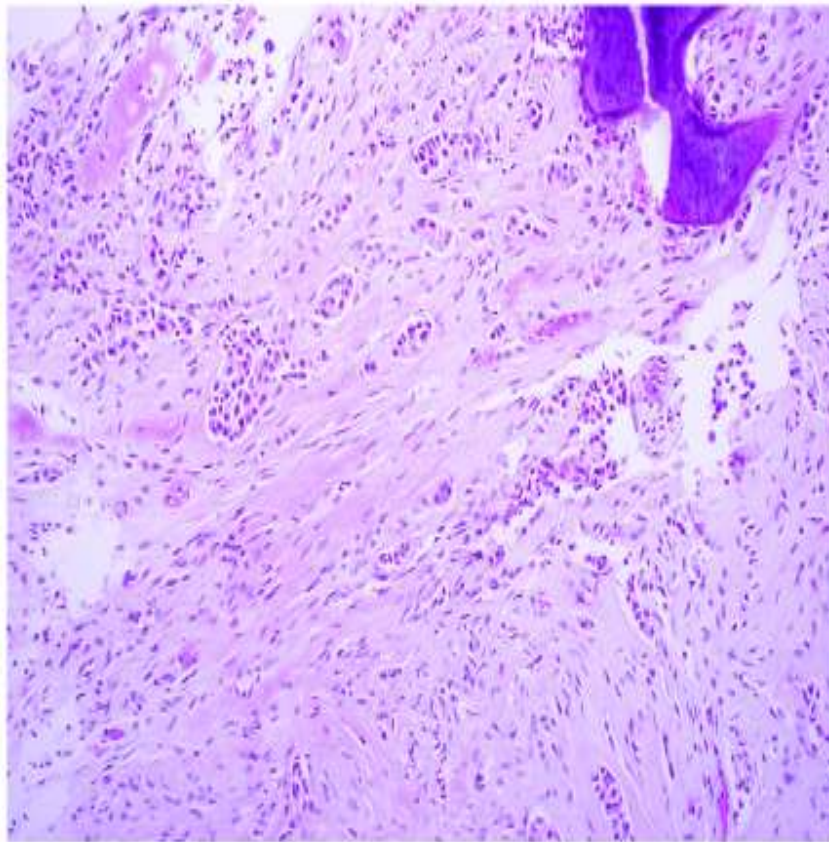
Fig (2): MRI scan of patient showing epidural Cord Compression (Sagittal View)



Pre & Paraspinal soft tissue & intervertebral disc spaces were normal. She underwent surgery by a joint neurosurgeon & spine surgeon on May 27, 2019. She underwent excision of the epidural space-occupying lesion (D7-D8) and internal fixation between D5-D10. The pathology report was consistent with metastatic disease from the breast “(shown in Fig. 3-6)” with ER&PR positive & Her-2 negative by FISH. Ki 67 was 40%. BRCA tests 1 & 2 were negative. Power in both lower limbs after surgery improved to grade 4/5. She was discussed in the tumor board meeting on June 13th, 2019, and accordingly

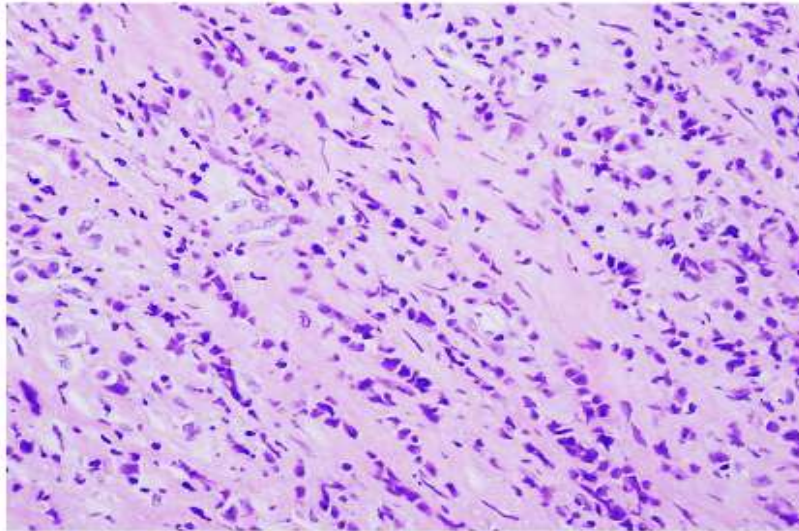
received postoperative 3D external beam radiotherapy using 6MV Linear Accelerator to the site of compression from D4 - D11 spine to a total dose of 30Gy in 10 fractions between July 01, 2019 to 14th July 2019 at Bahrain Oncology Center. Her power in both the lower limb remained at 4/5 after radiation treatment. She was on extensive physiotherapy and recovered her full ambulatory status with normal power in both lower limbs in the mid of August 2019.

She had been restarted on hormonal therapy (Tamoxifen 20 mg daily) with ovarian suppression by GnRHa since August 08, 2019. Restaging CT scan of chest, abdomen & pelvis done on August 01, 2019, showed multiple left breast masses which were stable and benign appearance as per the previous mammogram done in April 2019. Postoperative changes were seen in the right chest wall and right axilla. There was no evidence of lung, liver & bone metastasis. Multiple rods and screws of the D5-D10 spine were seen on the bone window as post spinal intervention.



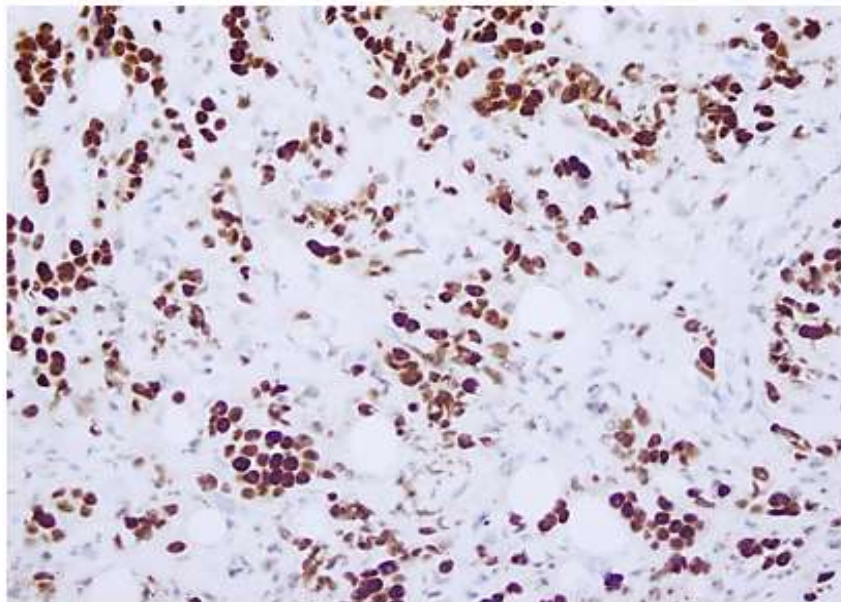
The sections show fibroadipose tissue and specks of bone. The tissue sampled is infiltrated by cords, single cells and vague glandular forms lined by pleomorphic enlarged cells with prominent nucleoli. (H&E x10)

Figure 3



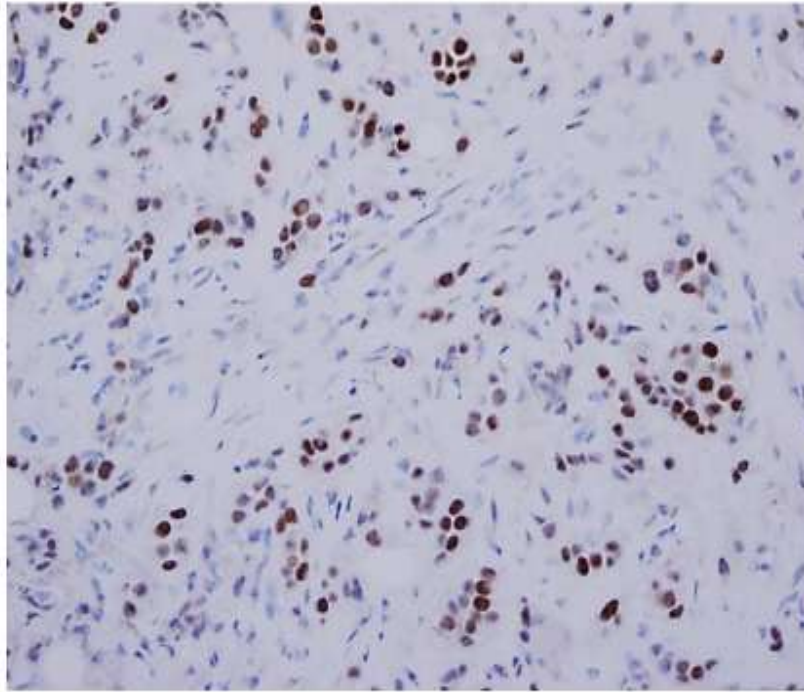
Infiltrative tumor cells (H&E x20)

Figure 4



The tumor cells are strongly and diffusely positive for Gata 3 supporting a breast origin

Figure 5



Estrogen Receptor (ER) positivity is seen in 70% of the cells. Histo score: 210/300

Figure 6

On February 26, 2020, a whole-body bone scan showed multiple areas of trace uptake involving the skull, dorsal, lumbar spines, sternum, left 11th rib, left shoulder, pelvic bones, and proximal region of both right and left femur consistent with bone metastasis so Denosumab was added to her treatment. Restaging CT scan chest, abdomen & pelvis (June 08, 2020) showed evidence of multiple bone metastasis however no other sites of distant or locoregional disease were evident. The case was discussed in the MDT meeting of Bahrain Oncology Center on July 13th, 2020, and advice to start II-line hormonal treatment (Fulvestrant) plus CD 4/6 inhibitors along with ovarian suppression, Denosumab & calcium & vitamin D supplements. She had single fraction palliative XRT to the right hip region including proximal femur as she was symptomatic one month back at Bahrain Oncology center. Currently, she is continuing on same the treatment, fully ambulatory, and occasionally requires NSAID for pain control.

Discussion

The definition of epidural spinal cord compression by Bilsky (2) is “any radiological evidence of indentation of the thecal sac with or without spinal cord involvement whether or not there are any associated neurological signs and symptoms due to compression”.



Epidural Spinal Cord Compression (ESCC) is the initial manifestation of malignancy in approximately 20% of patients (4,9,10) whereas it is seen in roughly 5% of all cancer patients as the complication of bone metastasis (9,10). The epidural cord compression is most commonly seen in the solid tumors in the cancer of prostate, lung, and breast, which have increased propensity to develop bone metastasis (3,9,10). ESCC most commonly arises in the thoracic spine in 60 to 70 %, 20 to 30 % in the lumbosacral spine, and 10 % in the cervical spine (5). Approximately 85 to 90 % of ESCC occurs due to metastatic tumor in the vertebral bones whereas in 10 % as paraspinal mass mostly in lymphoma & rarely tumor appears to originate from the epidural space without a bony or paraspinal component.

Usually, back pain is the first symptom of ESCC seen in 80 to 95% of patients at the time of diagnosis which usually precedes other neurologic symptoms of ESCC by seven weeks (6,9,10). The back pain in spinal cord compression is located at the level of compression (8), with or without a radicular component. Pain present only on movement suggests mechanical spinal instability, a finding that may demand a surgical approach for optimal relief of pain irrespective of the pathology of tumor (7).

Motor findings represent advanced stages of ESCC (6). Motor weakness is the second most common symptom seen in 80% of patients with spinal cord compression which can lead to difficulty in walking, weakness & gait disturbances (1). Sensory findings are less common than motor findings but are still present in a majority of patients at diagnosis in roughly 50% (6). Sympathetic involvement with loss of bowel & bladder function (incontinence, impotence, constipation) is the late manifestation of cord compression and is associated with poor prognosis (1,11).

Magnetic resonance imaging (MRI) of the entire spine (cervical, thoracic, and lumbar) without and with contrast is recommended in patients with suspected ESCC (9). Imaging should be obtained as soon as possible and within 24 hours in patients suspected of having ESCC (10). MRI-based radiographic assessment is also done to characterize patients into high- or low-grade ESCC. Computed tomography (CT) myelography is the alternative imaging option in patients with suspected ESCC who cannot undergo MRI (e.g., some electromagnetic cardiac devices, metallic foreign body in the orbit). The procedure involves the direct injection of iodinated contrast into the thecal sac by either lumbar or, if necessary, cervical puncture, followed by CT imaging of the cervical, thoracic, and lumbar spine. CT myelography is only performed where neurosurgical expertise is readily available as patients can, rarely, deteriorate following the procedure and require urgent spinal decompression.

Despite advances in the treatment of cancer, the current treatment of spinal cord compression is still palliative. Treatment aims to control pain, improvement or preservation of neurological function, and local tumor control (1). Once the diagnosis of the spinal cord is suspected then it is important to



administer a bolus dose of intravenous dexamethasone 8-10 mg IV followed by 16mg daily (1,9,11) with gastric protection by proton pump inhibitors. The efficacy of steroids in the management of cord compression in cancer patients has been demonstrated in terms of pain relief and improvement of motor function (8,9). Higher doses of steroids lead to more side effects & complications. Steroids reduce the edema by their anti-inflammatory property and serve as a bridge between definitive treatment (1,8). Steroids to be tapered once the goal is met. Undesirable toxicity from steroids has been seen between 21-40 days following initiation (9). Pre-treatment neurologic status and duration of ambulatory status are the most important prognostic factors (9).

Surgery is the treatment of choice in spinal instability or radioresistant or unknown primary tumors (9). Usually, decompression surgery followed by postoperative radiotherapy gives the best local control followed by systemic treatment in the chemosensitive or hormone-sensitive tumors (10). In radiosensitive or in multiple levels of compression radiotherapy alone gives the best palliation. Systemic treatment is indicated in chemo-sensitive & hormonal sensitive tumors after local treatment. Physiotherapy has to be an integral part of management & its role cannot be underestimated. Our patient's ambulation was restored after completion of planned treatment with several weeks of regular physiotherapy.

According to SOFT & TEXT phase III trials (12) adjuvant hormonal treatment has a definite role in both premenopausal as well as post-menopausal women in terms of disease-free survival advantage as well as freedom from distant metastasis. As per the SOFT trial freedom from distant relapse was noted in 80 % of patients who had chemotherapy and in 89% of patients who had adjuvant Tamoxifen following chemotherapy.

Conclusion

- Back pain with a history of malignancy should be viewed with caution.
- MRI scan of the whole spine is an investigation of choice.
- Educate patients & their family with metastatic cancer to seek early advice with back pain.
- Create awareness among hospital staff who are involved with this condition to act fast.
- Recommend to have an "Oncologic Emergency Code" in the hospital with a time limit.



Acknowledgement

I am indebted to my patient, colleagues and Dr. Tejal Sharma, consultant radiologist in SMC hospital for their cooperation and support in preparing this case report.

Statement of Ethics

This paper is written according to our hospital policy. The patient had given verbal consent but not willing to sign written consent form. Nowhere patient's identity is revealed.

Conflict of Interest Statement

"The author has no conflicts of interest to declare."

References

1. Mirjana Rajer & Vilijem Kovac. "Malignant spinal cord compression". Radio Oncol 2008;42(1)23-31
2. Bilsky MH, Laufer I, Fourney DR, et al. "Reliability analysis of the epidural spinal cord compression scale". J Neurosurg Spine 2010; 13:324
3. Mak KS, Lee LK, Mak RH, et al. "Incidence and treatment patterns in hospitalizations for malignant spinal cord compression in the United States, 1998-2006". Int J Radiat Oncol Biol Phys 2011; 80:824
4. Savage P, Sharkey R, Kua T, et al. "Malignant spinal cord compression: NICE guidance, improvements and challenges". QJM 2014; 107:277
5. Cole JS, Patchell RA. "Metastatic epidural spinal cord compression". Lancet Neurol 2008; 7:459.
6. Helweg-Larsen S, Sorensen PS. "Symptoms and signs in metastatic spinal cord compression: a study of progression from first symptom until diagnosis in 153 patients". Eur J Cancer 1994; 30A:396.
7. Hussain I, Barzilai O, Reiner AS, et al. "Patient-reported outcomes after surgical stabilization of spinal tumors: symptom-based validation of the Spinal Instability Neoplastic Score (SINS) and surgery". Spine J 2018; 18:261.
8. Malik Tariq Rasool, Kaneez Fatima, Najmi Arshad Mustafa, et al. "Profile of malignant spinal cord compression: One-year study at regional cancer center". Indian Journal of Palliative Care.2016;22(2)125-129.



9. Stergios Boussios, Deirdre Cooke, Catherine Hayward, et al. “Metastatic spinal cord compression: Unraveling the diagnostic & therapeutic challenges”. *Anticancer research* 2018; 38:4987 – 4997
10. Chitra Nair, Shrijit Panikaar & Arupratan Ray. “How not to miss metastatic spinal cord compression”. *British Journal of General Practice*, September 2014;596-598
11. Hill M.E, Richards M.A, Gregory W.M, et al. “Spinal cord compression in breast cancer: A review of 70 cases”. *Br.J. Cancer* 1993; 68,969-973
12. Francis PA, Pagani O, Fleming GF et al “Tailoring Adjuvant Endocrine Therapy for Premenopausal Breast Cancer. SOFT and TEXT Investigators and the International Breast Cancer Study Group N Eng” *J Med*. 2018;379(2):122

Volume 1 Issue 3 April 2021

©All rights reserved by Dr. Mohammed Abdul Naseer