



The Journey of Management of An Unusual Case of Ectopic Pregnancy in A Non-Communicating Horn.

Dr. Rahul Manchanda ^{1*}, Dr. Apoorva Dave ², Dr. Rekha Khurana ³, Dr. Rachna Goyal ⁴,
Dr. Jiten Kumar ⁵, Dr. Varun Dugal ⁵

1. Consultant and Head, Department of Gynae Endoscopy, PSRI, New Delhi.
2. Senior resident, Department of Gynae Endoscopy, PSRI, New Delhi.
3. Head of the department, Department of Pathology, PSRI, New Delhi.
4. Consultant, Department of Pathology, PSRI, New Delhi.
5. Consultant Radiology, New Delhi.

Corresponding Author: Dr. Rahul Manchanda, Consultant and Head, Department of Gynae Endoscopy, PSRI, New Delhi.

Copy Right: © 2022 Dr. Rahul Manchanda, This is an open access article distributed under the Creative Commons Attribution License, which permits unrestricted use, distribution, and reproduction in any medium, provided the original work is properly cited.

Received Date: July 11, 2022

Published Date: August 01, 2022

Abstract

Introduction: Ectopic pregnancy in a non-communicating rudimentary uterine horn is a rare gynecological condition associated with a high risk of uterine rupture and maternal mortality and morbidity. A surgical excision of the rudimentary horn is the standard treatment, usually performed by laparotomy.

Methods: We present a rare case of 34-year-old Para1 Live 1 presented with history of amenorrhea of one and half month with no associated pain abdomen. On ultrasound initially no gestational sac was identified and she was considered as a case of Pregnancy of unknown location. The patient was followed up with serial B-hCG measurements and ultrasound scans, and we decided for laparoscopic resection once gestational sac was detected in the left non communicating rudimentary horn. We present a review of various case reports on management of ectopic pregnancy in rudimentary horn and discuss them alongside.

Results: We report a total laparoscopic removal of a pre-ruptured rudimentary uterine horn containing a first trimester ectopic pregnancy along with ipsilateral salpingectomy, using electrosurgical devices. To the best of our knowledge, very few cases of successful management of ectopic pregnancy in rudimentary horn have been reported in the literature.

Conclusion: For treating rudimentary horn pregnancy in patients with hemodynamic stability laparoscopy is an efficient and safe surgical option.

Key words: ectopic pregnancy, rudimentary horn, laparoscopy.

Introduction

In about 0.5% of the women¹ during their embryonic stage when development of one of the mullerian ducts gets arrested gives rise to unicornuate uterus with a horn. The incidence of pregnancy in rudimentary uterine horn is very rare, it varies from 1: 76,000 to 1: 140,000.^{2,3} Transperitoneal migration of a sperm or a fertilized ovum may very rarely lead to pregnancy in a noncommunicating rudimentary horn⁴.

Approximately 85% of these pregnancies land up in rupture, typically between the 10th and 20th weeks of gestation hence it is very important to manage such cases with excision of the pregnant horn.^{2,5} We present a successful laparoscopic management of rudimentary horn pregnancy that occurred spontaneously in a para1 live 1 female, and we review similar cases reported in literature.

Case History

A 34-year-old Para1 Live 1 presented with history of amenorrhea of one and half month (Her last menstrual period was 01/02/2022) with no associated pain abdomen.

Regarding her obstetric history, she had a previous vaginal delivery three and a half years back, which was uneventful.

With respect to her gynaecological history, she was previously operated for twisted ovarian dermoid cyst 10 years back which came out to be struma ovarii on histopathology report and also underwent metroplasty to normalize her uterine cavity 5 years back.

On ultrasound initially no gestational sac was identified and she was considered as a case of Pregnancy of unknown location (PUL). The patient was explained the need for follow up and was kept on a close follow up with serial B-hCG measurements (Table-1) and periodic ultrasound scans. Surgical resection was carried out once gestational sac was detected in the left non-communicating rudimentary horn as the patient was not willing for medical management.

Clinical findings, prognosis and therapeutic options were explained to the patient and laparoscopic resection of rudimentary horn with left salpingectomy was decided and carried out.

Date	B-hCG
1 st visit	53
2 nd visit (after 48 hours)	85 (Increased by 60%)
3 rd visit	120 (Increased by 40%)
4 th Visit	181 (Increased by 50%)
5 th visit	298 (Increased by 65%)
6 th visit	487 (Increased by 63%)
7 th Visit	776 (Increased by 60%)
8 th Visit	1367 (Increased by 76%)
9 th Visit	2123 (Increased by 55%)
10 th Visit	2357 (Increased by 11%)

Table 1: Serial beta- hCG measurements on various visits at 48-hour interval.

Patient was hemodynamically stable and didn't complaint of any pain in the abdomen and on 10th visit Ultrasound Imaging picked up pregnancy in the left uterine horn. The report is as follows:

Unicornuate right uterine horn (67mmX 35mmX 28mm) with rudimentary left uterine horn. The cavity appears to abutt the cavity of main right horn at the level of isthmus (37mmX 20mmX 17mm). An anechoic G-sac like area with echogenic margins in left uterine horn (1.9mmX 1.8mmX 1.7mm) Mean sac diameter 1.8mm corresponding to 4weeks+4days POG. No fetal ole or yolk sac seen. Background polycystic morphology with corpus luteum visualized in left ovary. No other pelvic mass. No free fluid in POD. No ascitis, pleural or pericardial fluid is present. The USG report concluded as Pregnancy in the rudimentary left horn (ectopic pregnancy). (corresponding with S. beta HCG 2123miu/ml) (Figure 1 and 2)

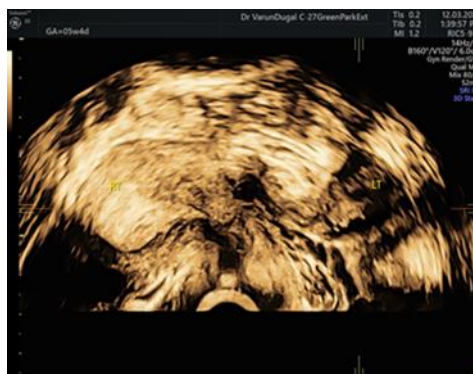

Figure 1: Showing the Right hemiuterus with left rudimentary horn.

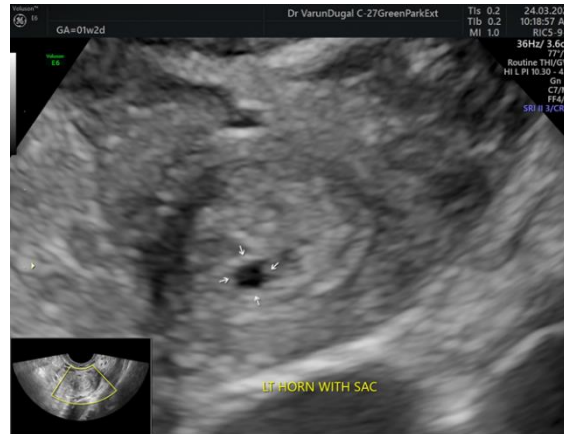


Figure 2: Showing ultrasound image of left uterine horn with sac.

Management:

Diagnostic and operative hysteroscopy with endometrial polypectomy and diagnostic and operative laparoscopy with removal of ectopic pregnancy with left uterine horn and left salpingectomy. (Figure-3)

Intra-operative findings:

On Hysteroscopy:

1. Endometrial polyp seen on the posterior uterine wall.
2. Only Right ostia visible, left ostia not visualized (unicornuate).
3. Background endometrium appears proliferative.

On laparoscopy:

Left rudimentary horn along with left fallopian tube removed and sent for HPE and haemostasis achieved

Laparoscopic chromopertubation:

Right Fallopian Tube Patency checked (Figure- 4)

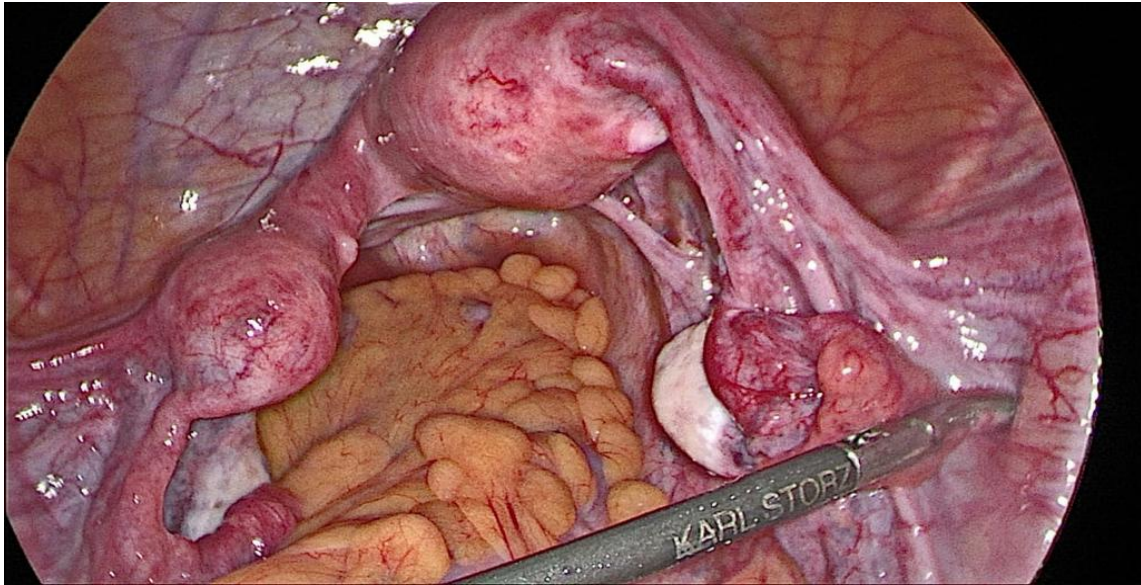


Figure 3: Laparoscopic appearance of left rudimentary horn

Post-operative: 24 hours post-operative serum beta HCG came down to 559.50 mIU/ml from 2123 mIU/ml preoperatively which is 76% drop in the Value. She was given with single dose Injection Methotrexate 50mg IM after 24 hours post operatively. Later beta hCG further reduced to 295 i.e. 47% drop.

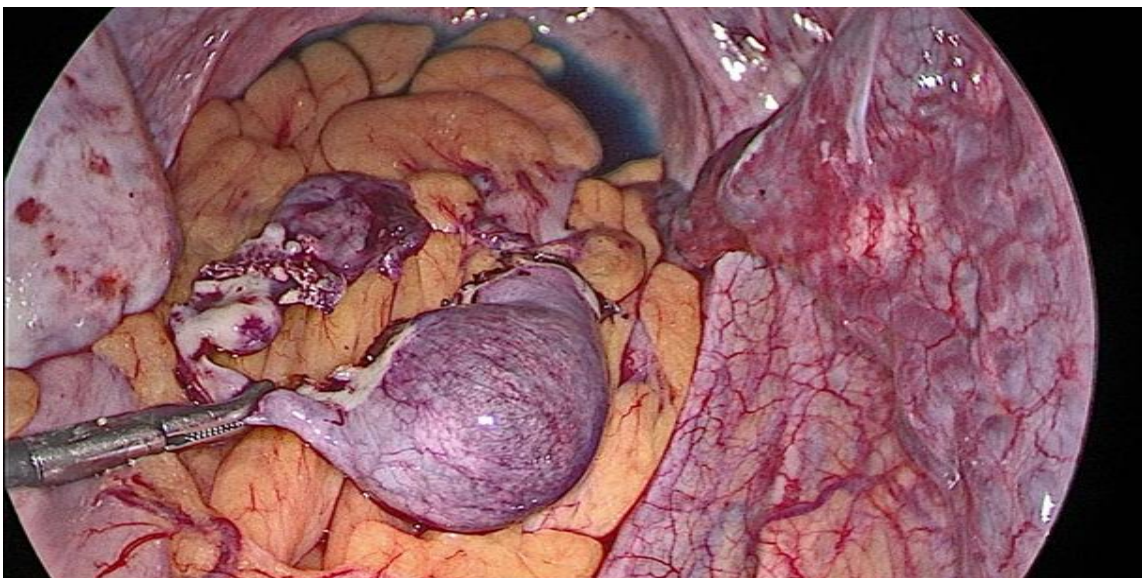


Figure 4: Dissected rudimentary horn with methylene blue spillage in the abdomen indicating right tubal patency.

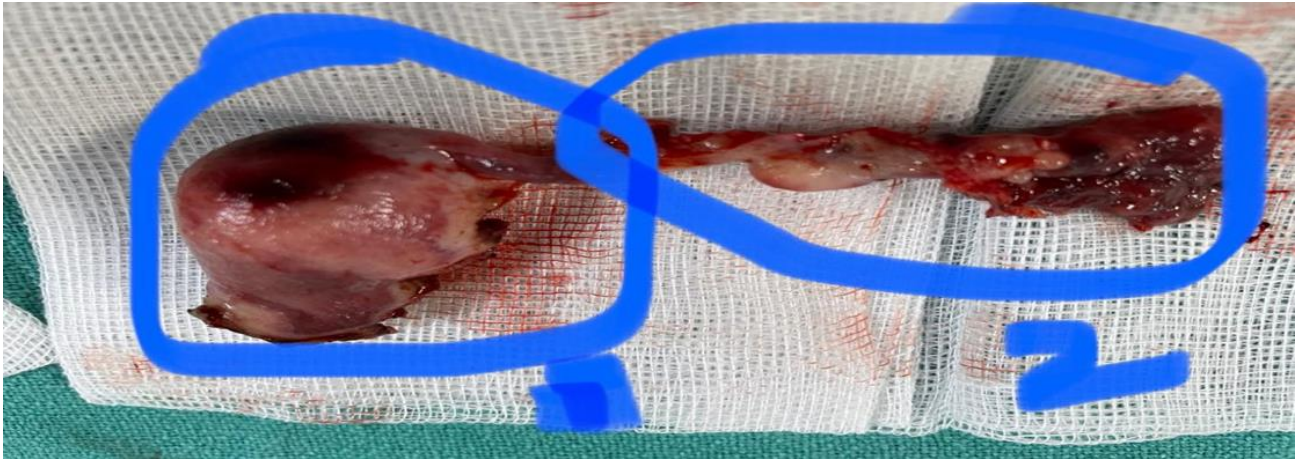


Figure 5: Left rudimentary horn with ipsilateral fallopian tube specimen

Histopathology:

Left cornual region (left rudimentary horn): Ectopic products of conception identified (Figure- 5,6,7,8)



Figure 6: Dilated cornual end with distended tubal wall, lumen contains villi

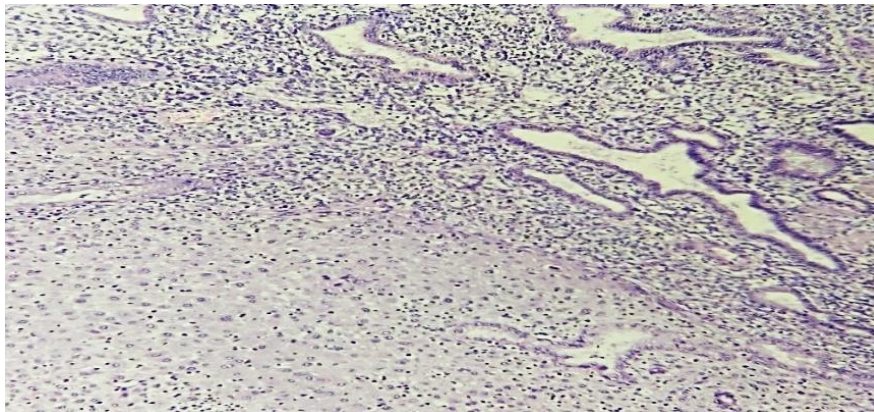


Figure 7: Fallopian Tube showing decidual reaction

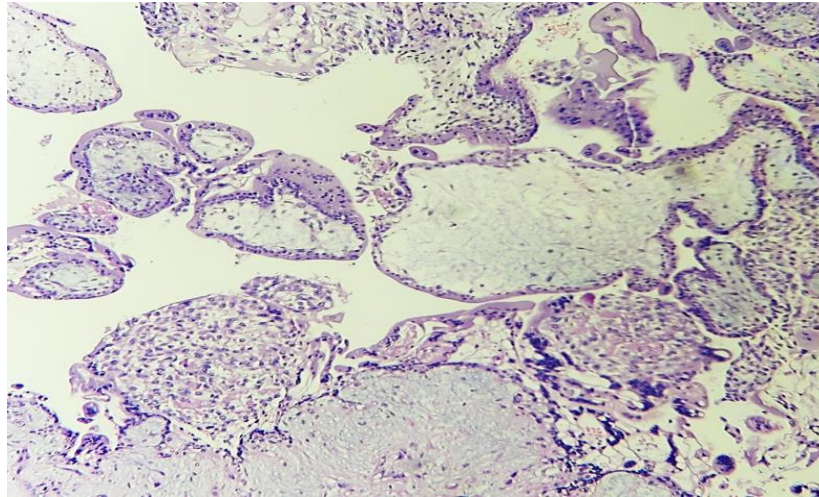


Figure 8: Multiple chorionic villi consistent with ectopic pregnancy

Discussion

Arrested development of one of the two Müllerian ducts gives rise to unicornuate uterus with rudimentary uterine horn. According to the American Fertility Society classification of Müllerian anomalies, different anatomical changes come under the umbrella this uterine anomaly and is further divided into four subgroups: (IIa) rudimentary horn having cavity that communicates with the unicornuate uterus, (IIb) having cavity which is non-communicating, (IIc) without having cavity and (IIId) without horn⁶.

Many a times the early diagnosis of a pregnant rudimentary horn may be missed on the prenatal ultrasound in the first trimester hence it plays a vital role in managing such cases. The reports suggest that the ultrasound is 26% sensitive and that it reduces with the increasing maternal age⁷. For the diagnosis of a rudimentary horn pregnancy the USG criteria is described as the presence of a bicorporeal uterus which is asymmetrical and no continuity between the lumen of the pregnant horn and the cervical canal, as well as the gestational sac being surrounded by the myometrial tissue⁸.

Almost 80% of the rudimentary horn pregnancies land up in uterine rupture⁹ and this may lead to 0.5% maternal mortality rate³. Negligence or lack of awareness at the patient level or at the clinicians' level may be the reason for uterine rupture in most of the cases, the early diagnosis of a rudimentary horn pregnancy is crucial for the successful management of this finding.

Criteria for managing ectopic pregnancy in rudimentary horn:

1. Close monitoring of serum beta hCG.
2. Localization of pregnancy as early as possible to rule out an ectopic pregnancy.
3. Counselling of patient regarding treatment options and future fertility.
4. Early intervention to avoid complications.
5. During surgery a concomitant hysteroscopy to rule out heterotopic pregnancy and avoid inadvertently missing any intrauterine pregnancy/ abnormality is a good step.

The total excision of the symptomatic rudimentary horn and the removal of the ipsilateral fallopian tube is the correct surgical approach in order to avoid the future risk of ectopic tubal pregnancy¹¹.

There are no intraoperative or postoperative complications associated with the laparoscopic removal of the rudimentary uterine horn¹². In the year 1990 the first laparoscopic approach for a rudimentary uterine pregnancy was explained¹³ and several case reports have been subsequently published as mentioned in the table 2.

Study	Age	Period of gestation	Preoperative Diagnosis*	Rupture	Treatment*
Chakravarti et al. ² (2003)	23	9 weeks	Left Ectopic pregnancy	No	LS-RHE
Edelman et al. ⁵ (2003)	23	7 weeks	Right RH pregnancy	No	MTX/LS-RHE
Dicker et al. ¹⁰ (1998)	31	8 weeks	Right cornual pregnancy	No	LS-RHE
Yahata et al. ¹³ (1998)	22	7 weeks	Right RH pregnancy	No	LS-RHE
Sönmezer M et al. ¹⁴ (2005)	28	6 weeks	RH pregnancy	No	LS-RHE
Present case	34	4 weeks 4 days	Left RH pregnancy	No	LS-RHE

*MTX= Methotrexate; LS-RHE = laparoscopic rudimentary horn excision; RH = rudimentary horn

Table 2. Various studies on Rudimentary horn pregnancy and its management

Conclusion

Early diagnosis of a rudimentary horn pregnancy is very crucial in order to provide successful management and prevent sinister complications in such cases. Laparoscopic approach in cases of rudimentary horn pregnancy is a safe and feasible technique.

References

1. Heinonen PK. Unicornuate uterus and rudimentary horn. *Fertil Steril.* (1997) 68:224–30. doi: 10.1016/S0015-0282(97)81506-3
2. Chakravarti S, Chin K. Rudimentary uterine horn: management of a diagnostic enigma. *Acta Obstet Gynecol Scand.* 2003; 82: 1153–1154
3. Nahum GG. Rudimentary uterine horn pregnancy. The 20th-century worldwide experience of 588 cases. *Reprod Med.* 2002; 47: 151–163
4. Scholtz M. A full-time pregnancy in a rudimentary horn of the uterus. *J Obstet Gynaecol Br Emp.* (1951) 58:293–6. doi: 10.1111/j.1471-0528.1951.tb04914.x
5. Edelman AB, Jensen JT, Lee DM, Nichols MD. Successful medical abortion of a pregnancy within a noncommunicating rudimentary uterine horn. *Am J Obstet Gynecol.* 2003; 189: 886–887
6. American Fertility Society (1988) The American Fertility Society classification of adnexal adhesions, distal tubal occlusion, tubal occlusion secondary to tubal ligation, tubal pregnancies, Müllerian anomalies and intrauterine adhesions. *Fertil. Steril.*, 49, 944–945.
7. Kaveh M, Mehdizadeh Kashi A, Sadegi K, Forghani F. Pregnancy in non-communicating rudimentary horn of a unicornuate uterus. *Int J Fertil Steril.* (2018) 11:318–20. doi: 10.22074/ijfs.2018.5022
8. Tsafirir A, Rojansky N, Sela HY, Gomori JM, Nadjari M. Rudimentary horn pregnancy: first-trimester prerupture sonographic diagnosis and confirmation by magnetic resonance imaging. *J Ultrasound Med.* (2005) 24:219–23. doi: 10.7863/jum.2005.24.2.219
9. Brady PC, Molina RL, Muto MG, Stapp B, Srouji SS. Diagnosis and management of a heterotopic pregnancy and ruptured rudimentary uterine horn. *Fertil Res Pract.* (2018) 4:6. doi: 10.1186/s40738-018-0051-7
10. Dicker D, Nitke S, Shoenfeld A, Fish B, Meizner I, Ben-Rafael Z. Laparoscopic management of rudimentary horn pregnancy. *Hum Reprod.* (1998) 13:2643–4. doi: 10.1093/humrep/13.9.2643
11. Fedele L, Bianchi S, Zanconato G, Berlanda N, Bergamini V. Laparoscopic removal of the cavitated noncommunicating rudimentary uterine horn: surgical aspects in 10 cases. *Fertil Steril.* (2005) 83:432–6. doi: 10.1016/j.fertnstert.2004.07.966

12. Canis M, Wattiez A, Pouly JL, Mage G, Manhes H, Bruhat MA. Laparoscopic management of unicornuate uterus with rudimentary horn and unilateral extensive endometriosis: case report. *Hum Reprod.* (1990) 5:819–20. doi: 10.1093/oxfordjournals.humrep.a137190
13. Yahata T, Kurabayashi T, Ueda H, Kodama S, Chihara T, Tanaka K. Laparoscopic management of rudimentary horn pregnancy. A case report. *J Reprod Med.* 1998; 43: 223–226
14. Sönmezer M, Taskin S, Atabekoğlu C, Güngör M, Unlü C. Laparoscopic management of rudimentary uterine horn pregnancy: case report and literature review. *JSLs.* 2006;10(3):396-399.

