



A Case of Valsalva Retinopathy Treated with NDYAG Hyaloidotomy

Dr. Harshita Singh ^{*1}, Dr. JP Singh ², Dr. KD Singh ³

1,2,3. Dr K. D's Eye Hospital, Pathankot.

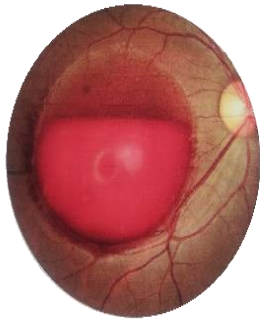
Corresponding Author: Dr. Harshita Singh, Dr K. D's Eye Hospital, Pathankot.

Copy Right: © 2023 Dr. Harshita Singh, This is an open access article distributed under the Creative Commons Attribution License, which permits unrestricted use, distribution, and reproduction in any medium, provided the original work is properly cited.

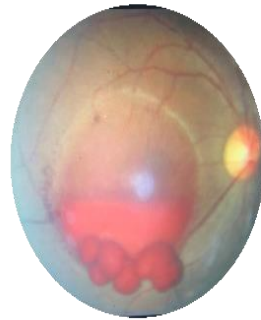Received Date: April 07, 2023

Published Date: May 01, 2023

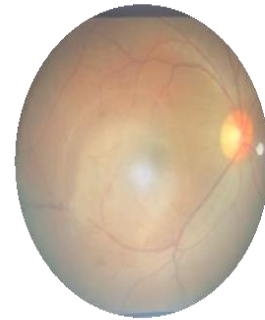
A young man aged 24 years presented with sudden loss of vision since two weeks. He had vision of HM in right eye and left eye was 6/6. On examination he had a huge subhyaloid hemorrhage in right eye and left eye was normal. He had history of lifting heavy weights two weeks prior. A diagnosis of valsalva retinopathy was made and Nd YAG hyaloidotomy was done for right eye. He was called for follow up after a week. The hemorrhage had totally cleared and his vision was 6/6.



Valsalva retinopathy



Nd yag hyaloidotomy done



One month after Yag hyaloidotomy